

# PROCUREMENT OF AUTOGENOUS BONE FROM THE MANDIBULAR RAMUS WITH SIMULTANEOUS THIRD-MOLAR REMOVAL FOR BONE GRAFTING USING THE ER, Cr:YSGG LASER: A PRELIMINARY REPORT

Cameron Y. S. Lee, DMD, MD

## KEY WORDS

Laser  
Osseous surgery  
Hydrokinetic effect  
Bone grafting  
Third-molar removal  
Morbidity

Autogenous bone grafting and third-molar removal are surgical procedures routinely performed in dentistry on a daily basis. The purpose of this preliminary report is to describe our clinical experience with the Er, Cr:YSGG laser in the procurement of bone harvested from the ramus and removal of third molars simultaneously from the mandible.

## INTRODUCTION

**L**oss of maxillary or mandibular anterior incisor teeth can be devastating for all patients, especially for the young adult or teenager. The loss of the incisor tooth is often perceived as a severe cosmetic embarrassment that can negatively affect the social behavior of the individual. To replace a missing anterior incisor tooth, dental implant therapy should seriously be considered the treatment of choice.

In most instances, loss of the anterior tooth is due to maxillofacial trauma, failed endodontic treatment, or congenital absence of teeth. Before implant placement, bone graft augmenta-

tion of the alveolar ridge is often indicated because of a deficiency of bone volume, especially in the labiolingual dimension. To reconstruct the ridge deficiency (atrophy or osseous defect) before implant placement, selection of the bone graft harvest site must be determined. In the young patient who has not had the mandibular third molars removed before implant treatment, procurement of bone from the posterior mandible while removing the third molars should be considered. The patient will benefit from this treatment plan because only 1 invasive surgical procedure will be performed.

Autogenous cortical bone grafts are used to correct a variety of osseous defects and atrophy in the maxillofacial region. Depend-

*Cameron Y. S. Lee, DMD, MD, is in private practice in Aiea, Hawaii. Address correspondence to Dr. Lee at 98-1247 Kaahumanu Street, Suite 314, Aiea, HI 96701 (e-mail: CLee555294@aol.com).*

ing on the size of the defect, the grafts can be harvested extraorally or locally from within the oral cavity. Bone procured from the ascending ramus and buccal cortical plate of the mandible is usually completed with conventional methods of a fissure bur in a high-speed hand piece or oscillating saw. The purpose of this article is to describe our experience with the latest generation of laser, the erbium, chromium: yttrium-scandium-gallium-garnet (Er, Cr:YSGG) laser (Biolase Technology Inc, San Clemente, Calif), to procure bone from the ramus of the mandible while removing the mandibular third molar. To date, there have been no published human clinical studies in the medical or dental literature documenting laser use as described below.

The acronym LASER stands for Light Amplification by Stimulated Emission of Radiation. Ever since Maiman<sup>1</sup> developed the ruby laser in 1960, lasers have become widely used for soft tissue procedures in general surgery, dermatology, and ophthalmology. Laser use in dentistry has been limited to soft tissue procedures such as gingivectomies, excision of fibromas, and frenectomies. With the development of the family of erbium lasers, laser use in dentistry has expanded to include removal of dental caries, cavity preparation, and periodontal and endodontic procedures.<sup>2-5</sup> Clinical evidence and anecdotal reports have demonstrated less bleeding, edema, and pain with laser use. It is theorized that the low levels of pain are caused by a protein coagulum that develops on the lased surface, which seals the ends of sensory nerves and provides biologic dressing over the wound.<sup>6</sup>

In a review of the laser literature, numerous published reports describe the negative effects of laser irradiation on hard tissues.

Adverse thermal damage was observed on the pulps of teeth with the use of the carbon dioxide (CO<sub>2</sub>) and neodymium-doped:yttrium-aluminum-garnet (Nd:YAG) lasers during soft tissue surgical procedures.<sup>7,8</sup> Recently, lasers have been demonstrated to ablate dental hard tissues without thermal injury during the ablation of enamel, cementum, and bone.<sup>5,9</sup> In 2002, the Er, Cr:YSGG laser was introduced for hard tissue surgical procedures such as osseous cutting, shaving, contouring, and resection after submission of safety and efficacy information to the Food and Drug Administration.<sup>10</sup> However, there are no published reports of its use in osseous surgery, especially in human clinical studies.

Laser energy is developed by directing light of various spectra into a medium that amplifies photons and directs them as monochromatic light in the ultraviolet, visible, or infrared regions of the electromagnetic wave spectrum. The laser beam is directed at a target tissue with a fiber-optic delivery system attached to a hand piece and is then emitted continuously or pulsed. Photon amplification occurs through a media such as solid crystals (synthetic ruby), heterogeneous crystals (neodymium, yttrium, aluminum, garnet, and erbium), or gases such as CO<sub>2</sub>, helium or neon, and argon. Each medium generates photons characteristic of that specific wavelength. Various energy levels are applied to cut, ablate, or coagulate tissues.<sup>11,12</sup>

#### LASER DEVICE

The Er, Cr:YSGG laser produces energy at a wavelength of 2780 nm and a pulsed duration of 140 microseconds with a repetition rate of 20 Hz. During the surgical procedures, the power output was

set at a maximum 6 W, yielding an energy density of 68.2 J/cm<sup>2</sup>. The laser device uses a pulsed energy source that is delivered through a fiber-optic delivery system connected to a straight hand piece with an end-cutting sapphire tip. The sapphire tip has a diameter of 750 μm. During the surgical procedure, the sapphire tip is positioned 1 to 2 mm from the target tissue and is bathed by an air-water spray mist to avoid charring of tissues. The mechanism of cutting hard tissue is unlike any other laser system and is accomplished by an interaction of the laser energy with the water spray, which has been termed a "hydrokinetic effect." Absorption of laser energy by the water mist produces violent microexplosions on the target tissue, which is responsible for removing calcified hard tissues such as enamel, cementum, and bone.<sup>13</sup>

#### MATERIALS AND METHODS

Four consecutive patients underwent bone graft augmentation of the anterior maxilla or mandible. Bone was harvested from the right ascending ramus and buccal cortical plate of the mandible with a laser manufactured by Biolase Technology Inc under local anesthesia. Simultaneously, the third molar was removed at the time of graft procurement. For comparison of surgical technique, the contralateral third molar was removed in conventional manner with a fissure bur in an electric high-speed hand piece operating at 70 000 revolutions per minute (rpm). No preoperative antibiotics were prescribed. Informed consent was obtained from all patients participating in the study. The patients were placed in the surgical chair in a semi-supine position. The surgical procedure in each patient was

accomplished under local anesthesia. Bilateral inferior alveolar nerve blocks were administered with lidocaine 2% with 1:100 000 epinephrine. To allow for determination of the size and shape of the donor bone to correct the osseous defect, the recipient site was prepared for grafting before harvesting of the donor bone. Access to the ascending ramus was accomplished with an envelope flap as used in removal of third molars as described by Misch.<sup>14,15</sup> The soft tissue incision began distal to the second molar in the buccal vestibule along the external oblique ridge and extended laterally to the retromolar pad. The incision can be extended superiorly toward the coronoid process until the temporalis tendon is seen. Care should be taken not to incise the buccal artery or expose the buccal fat pad. From the distal aspect of the second molar, the incision was extended to the first molar. The soft tissue flap was then reflected off of the buccal cortical plate of the mandible and isolated with retraction sutures. This provides for wide access to the ascending ramus and body of the mandible. A notched ramus retractor can be used to keep the soft tissues clear of the surgical field. However, in most instances this instrument is not required.

To procure the ramus graft (Figure 1), the superior horizontal laser osteotomy cut was started along the ascending ramus and buccal cortical plate with the laser. Depending on requirements of the graft to reconstruct the osseous defect, the osteotomy can be advanced up to the distal aspect of the first molar. From the horizontal osteotomy, the posterior and anterior vertical cuts can be made. The length of the vertical cuts depends on the size of the graft required, and care must be taken

not to violate the inferior alveolar canal and its contents. Use of the laser is entirely different from using a side-cutting fissure bur in a high-speed hand piece, for tactile sensation will allow the surgeon to accomplish the osteotomy. There is no tactile sensation with laser use because the laser is an end-cutting, noncontact surgical instrument. Therefore, during the noncontact osteotomy, the sapphire tip does not come into contact with the bone. In addition, the laser will ablate osseous tissue efficiently (1- to 1.5-mm depths) only if the hand is moved slowly. With steady hand movement, as in use of a high-speed hand piece, the laser will not ablate osseous tissue. Once the outline of the osteotomy is made, the laser cuts are progressively deepened into the cancellous bone. To complete the osteotomy cuts, the clinician can use either a fissure bur in a high-speed hand piece or a thin curved osteotome with a mallet. To remove the ramus graft from the body of the mandible, a small straight elevator can be used in a controlled manner. An inferior horizontal osteotomy is not necessary, as the ramus block graft will fracture off from the body of the mandible when using the straight elevator. Once the graft is removed (Figure 2) it should be stored in sterile saline solution. Attention is then directed to removing the impacted third molar in standard fashion. The overlying bone can be lased with the laser to gain access to the impacted molar. Once the tooth is exposed, it can be sectioned into 2 fragments with the laser. Or, to decrease surgical time, the tooth can be sectioned with a fissure bur in a high-speed hand piece.

#### RESULTS

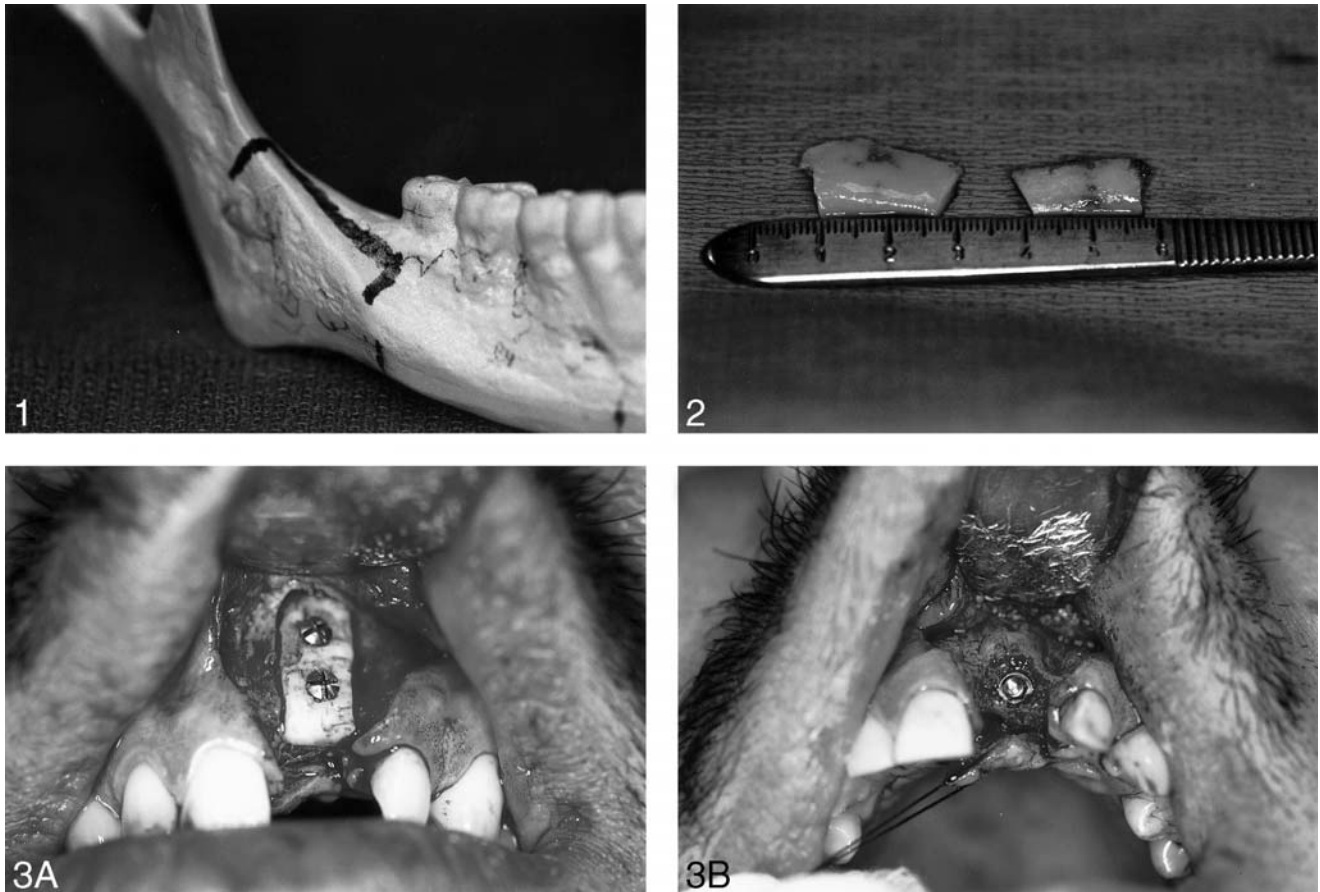
A total of 4 ramus or buccal cortical plate grafts were obtained

from 4 patients with the Er, Cr:YSGG laser. All 4 patients were observed for a period of 10 months from the time of the grafting procedure (Figure 3A) to completion of the prosthetic phase of implant treatment. Four months after grafting, the implant was surgically placed in the grafted jaw (Figure 3B). The implant was loaded 5 months later. The indication for block grafting in all the patients was atrophy in the labiolingual dimension.

The average age of the patients was 18.3 years. There were 3 females and 1 male in this study. Postoperatively, all patients were questioned about edema and pain. None of the patients reported edema and pain that was present, bilaterally. The postoperative edema was most pronounced 48 hours after surgery. However, the edema and pain of the mandible and face was reported to be greater on the left side where the contralateral third molar was removed with a fissure bur in a electric high-speed hand piece operating at 70 000 rpm. The postoperative pain was controlled with either oral narcotic analgesics or nonsteroidal anti-inflammatory medications. Two female patients developed bilateral ecchymosis of the skin that was present in the cheek and submandibular region of the neck. There were no wound complications of infection, neurosensory deficits such as paresthesia or anesthesia, or wound breakdown at the incision line of the graft harvest site.

The average dimension of bone harvested with the laser was 20 × 15 × 3 mm. The thickest area of the graft was 3.0 mm in the area of the buccal cortical plate in the first-molar region. The thinnest area was 2.1 mm posteriorly in the ascending ramus.

The laser osteotomy cuts with the laser were precise, clean, and



FIGURES 1–3. FIGURE 1. Illustration of osteotomy on surgical model. Superior horizontal laser osteotomy is made directly over the ascending ramus. Anterior and posterior vertical osteotomy cuts are joined to the horizontal osteotomy. FIGURE 2. Laser assisted procurement of monocortical block grafts. Note that the margins of the block grafts have almost no carbonization. FIGURE 3. (A) Intraoperative view of block graft stabilized to anterior maxilla with rigid fixation screws. (B) Implant placed in well-consolidated bone graft.

straight with minimal carbonization of osseous tissue.

Intraoperatively, all 4 patients did not experience any marked discomfort with the laser and electric high-speed hand piece. On postoperative interviews, all patients described a “popcorn popping” sound during laser use that was not intimidating compared with the loud, high-pitched sound of the surgical hand piece. Postoperatively, all patients reported use of analgesics to control the discomfort that they were experiencing. All patients reported minimal postoperative pain on the right side where the laser was used. The 3 female patients reported using

a combination of nonsteroidal anti-inflammatory medication and the prescribed narcotic analgesics (average of 4.5 days) to control the pain on the left side, which was described as moderate to severe, where the electric high-speed hand piece was used. The single male student reported using only nonsteroidal anti-inflammatory medication for 3 days. All patients commented that self-prescribed, nonsteroidal anti-inflammatory medication to control the pain on the right side where the laser was used was sufficient. This was in comparison with the left side where the high-speed hand piece was used, which required narcotic analgesia to con-

trol the pain. All patients were satisfied with the surgical grafting procedure and agreed that laser use is less intimidating and results in decreased postoperative pain and edema of the jaw and face. On the basis of their ability to compare the 2 different surgical armamentaria during osseous surgery, all 4 patients would select the laser as the treatment of choice.

#### DISCUSSION

Historically, laser surgery has been limited to soft tissue surgery. Lasers were first applied in dentistry to remove dental caries and



FIGURE 4. Margin of bone graft where laser was used to harvest block graft shows viable cortical bone with osteocytes in lacunae (Hematoxylin and eosin, original magnification  $\times 400$ ).

as a substitute for mechanical cutting with the air-turbine, high-speed hand piece to ablate teeth and bone with the argon, CO<sub>2</sub>, and Nd:YAG lasers.<sup>16,17</sup> These lasers proved ineffective in ablating hard tissues because they required high-energy densities to vaporize hard tissues. Major thermal adverse effects were observed with these lasers, such as pulpal damage, melting, cracking, and charring of the tooth in the surgical field.<sup>7,18-20</sup> The new generation of lasers introduced in the late 1990s, such as the erbium-doped:yttrium-aluminum-garnet (Er:YAG) laser with a wavelength of 2940 nm and the Er, Cr:YSGG laser with a wavelength of 2780 nm, has shown the ability to ablate teeth and bone without damaging the pulp or necrosing the bone.<sup>5,9,13</sup> Both lasers operate under a water spray mist. Studies by Paghdiwala,<sup>21</sup> Burkes et al,<sup>22</sup> Keller and Hibst,<sup>23</sup> and Aoki et al<sup>24</sup> have demonstrated minimal thermal damage to the tooth structure, especially the pulp, with the

Er:YAG laser in conjunction with a water spray. Eversole et al<sup>25</sup> showed that osseous wound repair with the Er, Cr:YSGG laser was comparable with surgery performed with an air-turbine dental drill in the tibia of beagle dogs. In their animal histologic studies, Rizoiu and colleagues<sup>13</sup> demonstrated no adverse thermal changes to the pulps of teeth in rabbit and beagle dogs with the Er, Cr:YSGG laser compared with the conventional fissure bur in a high-speed air-turbine hand piece operating at 25 000 rpm. These findings suggest that, under satisfactory water spray and good laser technique, thermal damage to hard tissues can be avoided (Figure 4).

Review of the world medical and dental literature on the clinical use of the Er, Cr:YSGG laser regarding osseous surgery and removal of teeth has not been reported. However, studies have shown the successful use of this laser in caries removal, cavity preparation, and periodontal and endodontic treatment.<sup>2-5</sup> The

current study deals exclusively with the cutting of bone and removal of impacted third-molar teeth. The Er, Cr:YSGG laser has demonstrated to be a surgical instrument capable of ablating hard tissues for procurement of bone in grafting procedures and in the removal of impacted third molars. A number of researchers have shown that erbium lasers ablate hard tissues by a laser-initiated subsurface expansion of the interstitial water in hard tissues such as bone and enamel. The explosive destruction is due to an increase in internal pressure before the melting point is reached. Other authors have coined this process of explosive ablation as "thermomechanical effect," "cavitation effect," and "hydrokinetic effect."<sup>13,24-27</sup> With this specific laser, the proposed mechanism of cutting hard tissue is due to a hydrokinetic effect where laser-atomized water droplets ablate the target tissue.<sup>13</sup> However, the precise mechanism of ablation remains unclear. In their study evaluating the effects

of atomized water spray, Freiberg et al<sup>26</sup> did not find any marked degree in the ablation of hard tissue structures such as enamel.

Intraoperatively, the laser beam permits precise, clean cutting of hard tissues without necrosing osseous tissues or causing collateral damage to the surrounding soft tissues and teeth. This is because of the water spray mist that surrounds the laser beam. The popcorn-popping sound of the laser experienced by the patient during the cutting of hard tissue is not intimidating compared with the high-pitched sound of the high-speed hand piece. Another important finding observed is the decreased amount of intraoperative bleeding during the laser osteotomy. Postoperatively, all 4 patients reported minimal pain and edema with laser use.

Previous reports claimed that the disadvantage of the family of erbium lasers is the prolonged operational time to complete the various dental procedures. Aoki and colleagues<sup>24</sup> observed that caries removal with the Er:YAG laser took almost 3 times as long compared with conventional treatment with a bur in a high-speed hand piece. Keller and Hibst<sup>23</sup> reported that the operational time for cavity preparations in enamel and dentin took twice as long with the Er:YAG laser compared with a high-speed hand piece. During endodontic procedures, Mazeki et al<sup>28</sup> reported that the preparation time was also longer with laser use compared with conventional treatment. Clinicians who are inexperienced with the laser will have a tendency to move the laser rapidly to cut tissues like they would with the high-speed hand piece. With rapid movement of the laser, cutting of tissue will not occur. Cutting efficiency occurs only if the laser sapphire tip is

moved very slowly over the object to be lased. The third molars removed in this study were not fully developed, as they all lacked total root development. Approximately 20 minutes was required from soft tissue incision to closure in order to remove a third molar with the laser. Less than 10 minutes was required to remove a third molar with conventional use of a fissure bur in an electric high-speed hand piece at 70 000 rpm. Approximately 30 minutes from soft tissue incision to closure was required to harvest a unicortical block of bone with the laser. Less than 15 minutes was required to harvest bone with a fissure bur in an electric high-speed hand piece.

There is a definite learning curve as the clinician gains experience with laser use. To shorten the surgical time of the procedure, sectioning of the third molar with a fissure bur in a high-speed hand piece is highly recommended. Troughing of bone on the buccal aspect of the third molar during its removal with the high-speed hand piece causes postoperative pain and edema for the patient. Troughing of bone should be completed with the laser to minimize these effects. During the procedure to harvest bone from the ramus of the mandible, multiple passes of the sapphire tip were required to complete the osteotomy cuts. To decrease surgical time, a fissure bur can be used to complete the bone cuts before the graft is removed with a chisel or elevator from the body of the mandible.

The use of autogenous bone for grafting in maxillofacial reconstruction and implant treatment continues to be the "gold standard". Autogenous bone is osteogenic, osteoconductive, and osteoinductive. This is the moti-

vating force to explore new surgical techniques to harvest autogenous bone. When evaluating new surgical instrumentation and methods, the surgeon should consider the cost of the instrumentation compared with conventional methods; technical difficulty of performing the surgery with the new instrumentation; and, most importantly, patient morbidity.

The use of the Er, Cr:YSGG laser in operative dentistry is well documented. In the present study, a total of 4 ramus grafts were harvested and 4 third molars were removed from the mandible with this laser. No morbidity was observed throughout the course of this study. Predictable results with this laser technique have been demonstrated.

Postoperative patient interviews were completed regarding assessment of pain and edema. All 4 patients agreed that the amount of postoperative pain and edema was less with laser use. This was in comparison with removing the contralateral third molar with a fissure bur in an electric high-speed hand piece. The results revealed that all 4 patients were satisfied with treatment and preferred the use of the laser to the high-speed hand piece. The only disadvantage with laser use is the prolonged operative time. The surgeon should allow for additional time to complete the surgery if he or she selects the laser as the armamentarium of choice.

## CONCLUSION

Even though our sample size was small, our clinical findings are nonetheless promising. Use of the Er, Cr:YSGG laser for harvesting autogenous bone and removing third molars is predictable,

has minimal morbidity, and is preferred by patients over the conventional high-speed hand piece. Despite the prolonged operational time, use of the Er, Cr:YSGG laser should be considered as an alternative modality to the high-speed hand piece in surgical procedures such as bone graft procurement and removal of third molars. Further peer-reviewed clinical studies are needed to establish the full potential of laser use in osseous surgery.

#### REFERENCES

- Maiman TH. Stimulated optical radiation in ruby lasers. *Nature*. 1960;187:494-494.
- Rick RM, Colvard MD. Current status of lasers in soft tissue dental surgery. *J Periodontol*. 1993;64:589-602.
- Wigdor HA, Walsh JT, Featherstone JDB. Lasers in dentistry. *Lasers Surg Med*. 1995;16:103-133.
- Matsumoto K. Lasers in endodontics. *Dent Clin North Am*. 2000;44:889-906.
- Israel M, Cobb CM, Rossman JA. The effect of CO<sub>2</sub>, Nd:YAG and Er:YAG lasers with and without surface coolant on tooth root surfaces: an in-vitro study. *J Clin Periodontol*. 1997;24:595-602.
- Schuler DE. Use of the laser in the oral cavity. *Otolaryngol Clin North Am*. 1990;23:31-42.
- Spencer P, Cobb CM, Wieliczka DM, Glaros AG, Morris PJ. Change in temperature of subjacent bone during soft tissue laser ablation. *J Periodontol*. 1998;69:1278-1282.
- Williams TM, Cobb CM, Rapley JW, Killoy WJ. Histologic evaluation of alveolar bone following CO<sub>2</sub> laser removal of connective tissue from periodontal affects. *Int J Periodontics Restor Dent*. 1995;15:497-506.
- Yamaguchi H, Kobayashi K, Reiko O. Effects of irradiation of a Er:YAG laser on root surfaces. *J Periodontol*. 1997;68:1151-1155.
- Food and Drug Administration. 510(k). Summary of Safety and Effectiveness Information: Waterlase Millennium, hydrokinetic tissue cutting system. Available at: <http://www.fda.gov/cdrh/pdf/ka13908.pdf>. Accessed February, 2002.
- Levy M. Light, lasers and beam delivery systems. *Laser Surg*. 1992;9:521-532.
- Kutsch VK. Lasers in dentistry: comparing wavelengths. *J Am Dent Assoc*. 1993;124:49-54.
- Rizoiu I, Kohanghadosh F, Kimmel AI, Eversole LR. Pulpal thermal response to an erbium, chromium:YSGG pulsed laser hydrokinetic system. *Oral Surg Oral Med Oral Pathol Oral Radiol Endod*. 1998;86:220-223.
- Misch CM. Ridge augmentation using mandibular ramus bone grafts for the placement of dental implants. *Pract Periodontics Aesthet Dent*. 1996;8:127-135.
- Misch CM. The use of ramus grafts for ridge augmentation. *Dent Implant Update*. 1998;9:41-44.
- Stern RH, Vahl J, Sogunaes RF. Lased enamel: ultrastructural observations of pulsed carbon dioxide laser effects. *J Dent Res*. 1972;51:455-460.
- Melcer J, Chaumette MT, Melcer F, Dejardin J, Hasson R, Merard R. Treatment of dental decay by CO<sub>2</sub> laser beam: preliminary results. *Lasers Surg Med*. 1984;4:311-321.
- Wigdor HA, Abt E, Ashrafi S, Walsh JTJC. The effects of lasers on dental hard tissues. *J Am Dent Assoc*. 1993;124:65-70.
- White JM, Fagan MC, Goodis HE. Intra-pulpal temperatures during pulsed Nd:YAG laser treatment of dentin in-vitro. *J Periodontol*. 1999;65:255-259.
- Tokita Y, Sunakawa M, Suda H. Pulsed Nd:YAG laser irradiation of the tooth pulp in the cat: effect of spot lasing. *Lasers Surg Med*. 2000;26:398-404.
- Paghdiwala AF. Er:YAG laser hard tissue effects. In: Moretti M, ed. *Lasers in Dentistry*. Westford, Mass: Penn-Well Publishing Co; 1991:63-75.
- Burkes EJ, Hoke J, Gomes E, et al. Wet versus dry enamel ablation by Er:YAG laser. *J Prosthet Dent*. 1992;67:847-851.
- Keller U, Hibst R. Experimental studies of the application of the Er:YAG laser on dental hard substances: II. Light microscopic and SEM investigations. *Lasers Surg Med*. 1989;9:345-351.
- Aoki A, Ishikawa T, Yamada M, et al. Comparison between Er:YAG laser and conventional technique for root caries treatment in-vitro. *J Dent Res*. 1998;77:1404-1414.
- Eversole LR, Rizoiu I, Kimmel AI. Pulpal response to cavity preparation by an erbium, chromium: YSGG pulsed laser hydrokinetic system. *J Am Dent Assoc*. 1997;128:1099-1106.
- Freiberg RJ, Boutossov D, Cozean C. Role of water irrigation during Erbium laser ablation of hard dental tissue: evaluation of the effects of atomized water spray versus water surface film. Available at: [http://www.laserdentale.com/articolo12\\_febbraio2003.doc](http://www.laserdentale.com/articolo12_febbraio2003.doc). Accessed February, 2004.
- Education. Academy of Laser Dentistry. An overview of laser wavelengths used in dentistry. Available at: [http://www.laserdentistry.org/praf/edu\\_overview.cfm](http://www.laserdentistry.org/praf/edu_overview.cfm). Accessed February, 2004.
- Mazeki K, Kimura Y, Yokoyama K, Matsumoto K. Preparation of root canal orifices by Er:YAG laser irradiation: in vitro and clinical applications. *J Clin Laser Med Surg*. 2003;21:85-91.