

# A 7-YEAR FOLLOW-UP OF 93 IMMEDIATELY LOADED TITANIUM DENTAL IMPLANTS

Marco Degidi, MD, DDS  
Adriano Piattelli, MD, DDS

## KEY WORDS

Bone reactions  
Follow-up study  
Immediate loading  
Prospective study  
Titanium implants

*Marco Degidi, MD, DDS, is in private practice in Bologna, Italy, and is a visiting professor, Dental School, University of Chieti, Chieti, Italy. Address correspondence to Dr Degidi at Via S. Allende 12/A, Bologna, Italy (e-mail: marcodegidi@tin.it).*

*Adriano Piattelli, MD, DDS, is a professor of Oral Medicine and Pathology, Dental School, University of Chieti, Chieti, Italy.*

Recently, several experimental and clinical investigations found that immediately loaded implants obtained satisfactory levels of osseointegration with high success percentages. Only a few long-term studies of immediately loaded implants have been reported in the literature. The aim of this study was a 7-year clinical and radiographic follow-up of 93 immediately loaded dental implants in human patients. Eleven patients were consecutively enrolled in this study. A total of 7 full and 9 partial edentulous arches were rehabilitated. Patients presented a completely edentulous mandible ( $n = 6$ ), a completely edentulous maxilla ( $n = 1$ ), mandibular posterior edentulous areas ( $n = 5$ ), or a posterior maxillary edentulous area ( $n = 1$ ). Patients were rehabilitated with a bar and an overdenture ( $n = 4$ ), a provisional prosthesis of 3 to 12 elements ( $n = 11$ ), or a metal-ceramic bridge of 10 elements ( $n = 1$ ). A total of 93 implants were inserted and loaded within a 24-hour time frame. Six implants failed in the first year after loading. No more failures were observed in the following 6 years, and all the other implants were well integrated from a clinical and radiographic point of view. The cumulative success rate at 7 years was 93.5%, and the prostheses survival rate was 98.5%. The mean marginal bone loss was 0.6 mm after the first year and 1.1 mm at the 7-year evaluation. Primary stability is one of the most important parameters in immediately loaded implants because it avoids micromotion at the bone-implant interface. Four of the 6 failures in our patients occurred in partially edentulous patients; an excessive load applied to these small bridges could be the reason for the failure. Also, the bone quality is important, for 3 of our failed implants had been inserted in D3 bone. Our clinical and radiographic results have shown that these immediately loaded implants have remained osseointegrated for a long period. Our results point to the possibility of using the immediate loading technique in selected and well-informed cases.

## INTRODUCTION

A submerged healing period of about 3 to 4 months was deemed necessary for the formation of mineralized bone around dental implants, whereas a too-early loading with excessive interfacial micromotion could affect the peri-implant tissues in an untoward manner with the occurrence of a fibrous tissue at the bone-biomaterial interface.<sup>1,2</sup> Little is known, however, on the strain distribution in bone around dental implants after loading with its triggering effects on cells and their biological activities.<sup>2</sup> Excessive micromotion probably damages the early scaffolding from the fibrin clot, impeding its adherence to the implant surface.<sup>2</sup> Furthermore, the initial necrotic bone at the interface between bone and implant was believed to be unable to bear the prosthetic load until it was replaced by newly formed bone.<sup>3,4</sup> This waiting period may cause functional and psychological problems to the patients,<sup>5</sup> with the discomfort of wearing complete dentures, and could be one of the reasons why some patients do not choose implant-supported restorations.<sup>6</sup> The immediate loading technique, on the other hand, reduces the morbidity associated with fewer surgical interventions and facilitates the functional rehabilitation.<sup>7</sup> Moreover, because soft and hard tissues heal concurrently, the length of treatment can be reduced.<sup>8</sup> Recently, several investigators found that immediately loaded implants placed in different clinical conditions were able to obtain clinically satisfactory levels of osseointegration with high success percentages.<sup>7,9-20</sup> The term *immediate loading*

should be reserved only for the implants that are loaded in the time frame of 24 hours. Only a few long-term studies of immediately loaded implants have been reported in the literature. The aim of this study was a 7-year clinical follow-up of 93 immediately loaded dental titanium implants in human patients.

## MATERIALS AND METHODS

Eleven patients (7 men and 4 women; mean age 42 years, range 32-68) were consecutively enrolled in this study between April 1996 and July 1997. The Ethic Committee of the University of Chieti, Chieti, Italy, approved the protocol. All the patients gave their informed consent. Inclusion criteria were adequate amount of bone height and width, an implant site free from acute infection, a healthy appearance of the sinuses, sufficient primary stability, and an alveolar crest that would permit a prosthetically correct sagittal implant placement. Exclusion criteria were any systemic disease; metabolic bone disease; previously grafted jaws; previously irradiated jaws; a history of parafunctions; active inflammation or active infection in the oral cavity; pregnancy; and less than 1 mm of bone available at the buccal, lingual, and apical aspects of the implant. Ninety-three implants (31 IMZ and 62 Frialit-2) (Friadent, Mannheim, Germany) were inserted and immediately loaded. A total of 7 full and 9 partial edentulous arches were rehabilitated (Table 1) (Figures 1 through 8). Six patients presented a completely edentulous mandible and were rehabilitated with 43 implants. One patient presented a completely edentulous maxilla and was re-

habilitated with 12 implants, and 5 patients presented mandibular posterior edentulous areas and were rehabilitated with 23 implants. One patient presented an anterior maxillary edentulous area and received 8 implants, and 3 patients presented a posterior maxillary edentulous area and received 12 implants. Patients were rehabilitated with a bar and an overdenture (n=4), a provisional prosthesis of 3 to 12 elements (n=11), or a metal-ceramic bridge of 10 elements (n=1). The implants were loaded after 1 day. Periapical radiographs were taken after 1, 3, 6, 12, 24, 36, 48, 60, 72, and 84 months. At the 12-month follow-up and at each year thereafter, the prostheses were removed and a clinical evaluation of the peri-implant tissues, the implant mobility, and the bleeding index was made for each individual implant.

Success criteria were no peri-implant radiolucent areas; confirmed individual implant stability; the implant functioning as an anchorage for the functioning prosthesis; and no suppuration, pain, or ongoing pathological processes. All implants that did not fulfill the success criteria were classified as failures.

The marginal bone level was read from periapical radiographs taken at implant insertion and at each annual evaluation. A conventional radiograph Rinn holder was used (long-cone technique). The marginal bone level was measured as the distance from the implant crown border to the most coronal point where the marginal bone met the implant. A peak scale loupe with a  $\times 7$  magnifying factor and a scale graduated in 0.1 mm was used, and the same examiner (M.D.) made all measurements at the mesial and distal surfaces.

TABLE 1  
Implants inserted in the different anatomical configurations

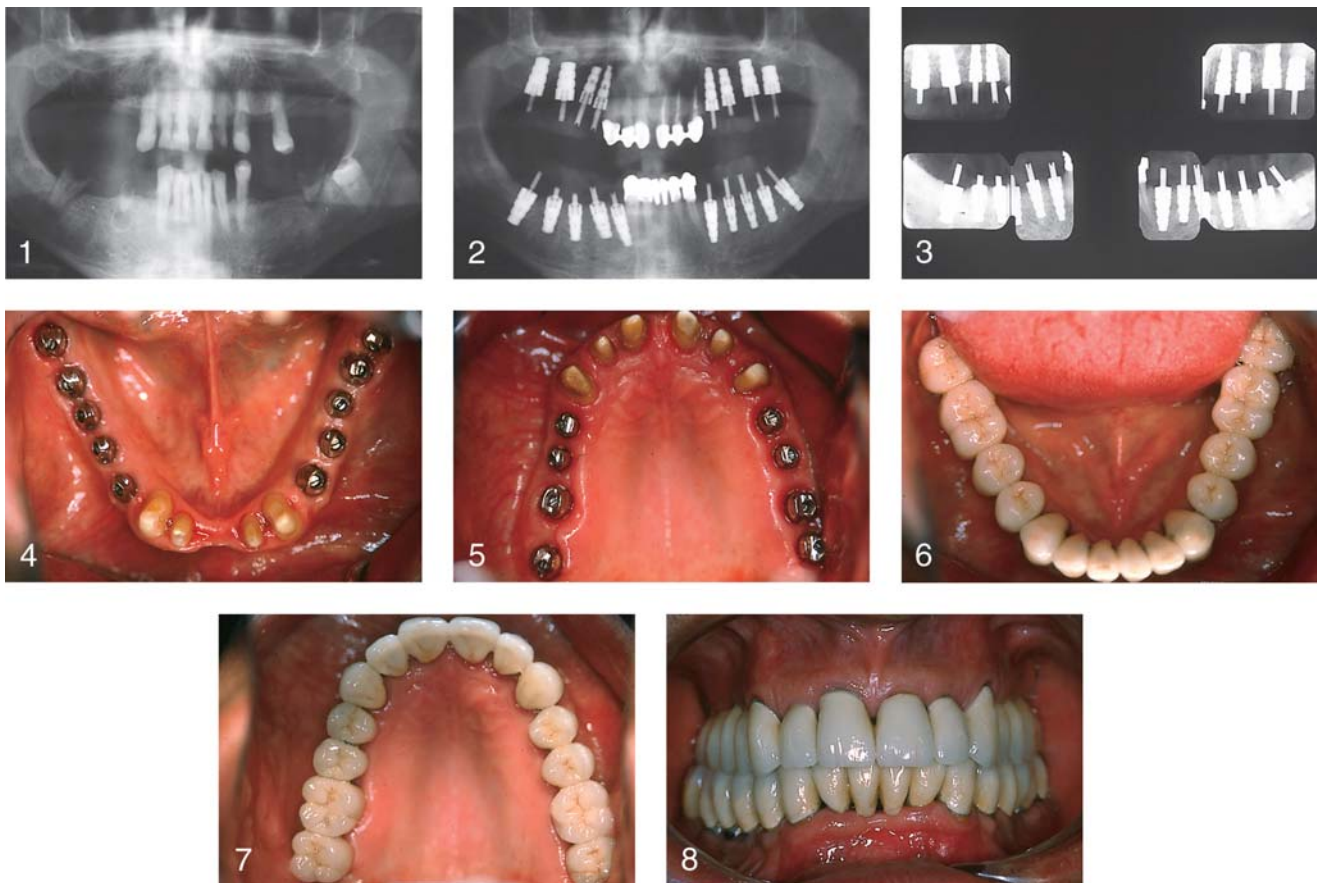
Follow-up Months	Immediate Functional Loading					
	No. of Cases	No. of Implants	No. of Implant Failure	% Implant Success	No. of Prostheses Failures	% Prostheses Survival
Edentulous mandible	6	43	0	100	0	100
Edentulous maxilla	1	12	2	83.3	0	100
Mandibular posterior edentulous area	5	23	2	91.3	1	80
Anterior maxillary edentulous area	1	8	2	75	0	100
Posterior maxillary edentulous area	3	12	0	100	0	100
Total	16	93	6	93.5	1	98.5

**RESULTS**

After 3 months, 1 patient complained of pain in the implant region. The bridge was removed and 2 of the 3 implants were found to be mobile and were

easily removed. Another patient, on removal of the fixed provisional prosthesis on a follow-up at 6 months, presented 2 maxillary implants with a vertical bone loss of more than 50% of the

implant length. These implants were consequently removed. In another case, an implant was lost as the bridge came off because of cement failure, whereas another was removed because it was not



FIGURES 1-8. FIGURE 1. Preoperative panoramic X ray. FIGURE 2. Postoperative panoramic X ray. FIGURE 3. Postoperative periapical X ray. FIGURE 4. Final restoration. Maxilla, occlusal view of the abutments. FIGURE 5. Final restoration. Mandible, occlusal view of the abutments. FIGURE 6. Final restoration. Maxilla, occlusal view. FIGURE 7. Final restoration. Mandible, occlusal view. FIGURE 8. Final restoration. Frontal view.

TABLE 2  
Failures associated with immediate functional loading\*

	Bone Quality	Bone Quantity	Diameter Implant	Implant Length	Location	Type of Restoration	Patient Age	Patient Sex	Abutment	Surgery Complications	Ex-traction Site	Months Since Loading	Is Patient a Smoker?
Patient 1	D3	C-h	5.5	10	15	FTB cemented	57	Male	Protect	Sinus penetration	No	6	No
Patient 1	D3	C-h	5.5	10	25	FTB cemented	57	Male	Protect	Sinus penetration	No	6	No
Patient 2	D1	B	3.8	8	46	FTB cemented	37	Female	Protect	No	No	3	No
Patient 2	D1	B	4.5	10	47	FTB cemented	37	Female	Protect	No	No	3	No
Patient 3	D2	B	4.5	15	11	FTB cemented	44	Female	Protect	No primary stability	No	6	No
Patient 3	D3	B	4.5	15	24	FTB cemented	44	Female	Protect	No primary stability	No	6	No

\*C-h, B is bone quantity according to Misch-Judy classification; FTB is fixed temporary bridge.

TABLE 3  
Life table analysis\*

IFL	No. of Months Loaded														
	0-6	7-12	13-18	19-24	25-30	31-36	37-42	43-48	49-54	55-60	61-66	67-72	73-78	79-84	85-90
Success	87	87	87	87	87	87	87	87	87	87	87	87	87	87	93
Failure	—	—	—	—	—	—	—	—	—	—	—	—	—	—	6

\*IFL is immediate functional loading.

integrated (Table 2). All the failures were observed in the first year of loading; no more implant failures were observed in the following 6 years (Table 3). All the other implants were well osseointegrated from a clinical and radiographic point of view. The cumulative implant success rate after a 7-year follow-up was 93.5%, and the prostheses survival rate was 98.5 % (Table 4).

The mean marginal bone loss value is the difference between the rough part of the implants length that is no longer in contact with bone and the distance from the reference point. The mean marginal bone loss (first year) was 0.6 mm (SD = 0.2) and sub-

sequently 1.1 mm at the 7-year evaluation (SD = 0.2) (Table 5) (Figures 9 through 11). All the patients showed no progressive marginal bone loss over time.

DISCUSSION

Frialit-2 implants have a stepped cylinder configuration where the axial loads acting on the implants are thought to be distributed to the step plateaus and lateral forces are dissipated to enveloping surfaces.<sup>21</sup> A very important requirement for the long-term success of endosseous implants is primary stability. Micromotion of more than 100 µm at bone-implant interface has been shown

to be important for the type of tissues that will form at the interface, particularly if the implants are loaded soon after the implant insertion.<sup>22,23</sup>

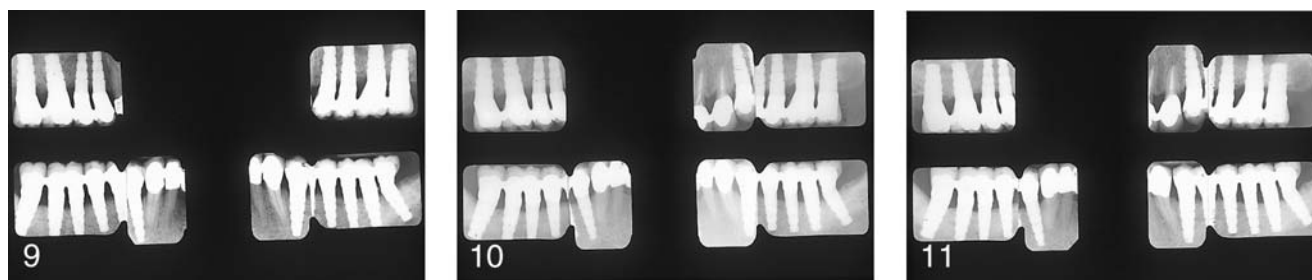Important factors for a proper implant integration in immediately loaded implants have been reported to be bone quality, macro- and microinterlock properties of the implant, bicortical initial stabilization, number and optimal distribution of implants, and careful use of cantilevers. These are also necessary to splint the immediately loaded implants to provide a sufficient degree of

TABLE 4  
Cumulative implant success

Follow-up Months	No. of Implants	Failures	% Implant success	% Prostheses Survival
Frialit-2	59	6	89.8	100
IMZ	34	0	100	100
Total	93	6	93.5	100

TABLE 5  
Marginal bone loss

	Baseline-1 Year	Baseline-7 Years
No. of Implants	87	87
Mean bone resorption (mm)	0.6	1.1
SD	0.2	0.2



FIGURES 9–11. FIGURE 9. Peri-apical X ray 1 year after loading. FIGURE 10. Periapical X ray 3 years after loading. FIGURE 11. Periapical X ray 7 years after loading.

stability and to protect the bone-implant interface from the negative effects of overloading.<sup>8</sup> Good primary stability serves to decrease the distortional strains in the newly regenerating tissues and to improve the chances of neo-osteogenesis at the interface; on the contrary, a poor stability of the implants has been shown to determine an important distortional strain with fibrous tissue formation at the interface.<sup>4</sup> The level of strain that can be safely placed on a dental implant before the occurrence of fibrous tissue at the interface must be investigated. The control of micromotion is probably the key issue in obtaining osseointegration in immediately loaded implants.<sup>19</sup> The reduction of micromotion can be obtained through a wide anterior-posterior distribution of the immediately loaded implants and a cross-arch stabilization of the edentulous arches with a rigid prosthesis.<sup>19</sup> Our patients experienced a steep decline in the rate of implant loss after the first year and

in the following years; no more failures were observed. We confirm data already reported in the literature.<sup>11,17,24</sup> Almost all the failures were presented in the initial stages when the bony interface was developing. Four of these 6 failures occurred in immediately loaded bridges in partially edentulous patients; an excessive load applied to these small bridges could be the reason for these failures. Also, the bone quality is important, for 3 of our 6 failed implants had been inserted in D3 bone. In this respect, Grunder<sup>25</sup> reported that all his failed implants were the most distal implants in that particular quadrant, and that all implants had been inserted in D3 or D4 bone.

Evaluation of the radiographs followed up to 7 years leads us to conclude that peri-implant resorption in immediately loaded implants is comparable with 2-stage implant placement methods subjected to an equal loading period. Ericsson et al<sup>26</sup> reported

an initial average bone loss of 0.4 mm in early loaded implants (18 months) an additional 0.2 mm at 5 years. No differences were observed among implants in different anatomical configurations.

Ibanez and Jalbout<sup>19</sup> found an average radiographic bone loss of 0.65 mm at the 12-month follow-up and 0.94 mm at the 24-month follow-up. Proussaefs et al.<sup>8</sup> found a marginal bone loss of 0.90 mm after 12 months in hydroxyapatite-coated implants used in single-premolar replacement. Wolfinger et al.<sup>14</sup> found no differences in the marginal bone level changes between immediately loaded implants and 2-stage implants. Rocci et al.<sup>17</sup> found a marginal bone loss of 1.0 mm during the first year in immediately loaded implants in the maxilla. On the contrary, Lorenzoni et al.<sup>13</sup> found that mean bone changes at prosthetic delivery was 0.9 mm resorption for loaded implants and 0.33 mm for non-loaded implants, and this difference was statistically highly significant.

Also, a careful surgical technique that minimizes trauma to the soft tissues appears to reduce initial bone loss. In our patients, the prosthetic unit/implant (PU/I) value was 1 in the maxilla and 1.1 in the mandible (Table 6). The optimal PU/I value is found in the single-tooth restoration (PU/I = 1).

IFL	Completely Edentulous*		Partially Edentulous	
	Maxillae	Mandibles	Maxillae	Mandibles
Prosthetic units	12	34	20	18
Implants	12	29	20	18
PU/I	1	1.1	1	1

\*Overdentures are not included in these statistics.

A high PU/I value could produce bending and flexure of the interim restoration, leading to an implant-interface micromovement and resulting in a fibrous implant interface.

Clinical reports with PU/I greater than 2 experienced higher failure rates than did our reports.<sup>27</sup> A low PU/I value improves the long-term prognosis of the implants and prosthetic restorations, and this applies even more so to more demanding situations like immediate functional loading/nonfunctional loading. It is important to build a prosthetic restoration that avoids transferring excessive stresses to the interface. It is then necessary to avoid long bridge spans; use rigid metallic abutments; use metallic reinforcements to the provisional prosthesis; decrease, when possible, the height of the clinical crown; avoid occlusal contacts in parafunctions or wear a night guard; and avoid cantilevers.

Our clinical and radiographic results have shown that these implants remain osseointegrated for long periods (up to 7 years). More studies are certainly necessary concerning the loading times of dental implants, for our results can point to the possibility of an immediate loading of dental implants but only in very selected and well-informed cases.

#### ACKNOWLEDGMENTS

This work was partially supported by the National Research Council, Rome, Italy; by the Ministry of Education, University and Research, Rome, Italy; and by Research Association for Dentistry and Dermatology, Chieti, Italy.

#### REFERENCES

1. Branemark PI, Hansson BO, Adell R, et al. Osseointegrated implants in the

treatment of the edentulous jaw. Experience from a 10-year period. *Scand J Plast Reconstr Surg.* 1977;11 (suppl 16):1-132.

2. Brunski JB. In vivo bone response to biomechanical loading at the bone/dental implant interface. *Adv Dent Res.* 1999;13:99-119.

3. Brunski JB. Forces on dental implants and interfacial stress transfer. In: Laney WR, Tolman DE, eds. *Tissue Integration in Oral, Orthopaedic and Maxillofacial Reconstruction.* Chicago, Ill: Quintessence; 1992:108-124.

4. Carter DR, Giori NJ. Effect of mechanical stress on tissue differentiation in the bony implant bed. In: Davies JE, ed. *The Bone-Biomaterial Interface.* Toronto, Ontario, Canada: University of Toronto Press; 1991:367-379.

5. Chiapasco M, Gatti C, Rossi E, Haefliger W, Markwalder TH. Implant-retained mandibular overdentures with immediate loading. A retrospective multicenter study on 226 consecutive cases. *Clin Oral Implants Res.* 1997;8:48-57.

6. Andersen E, Haanaes HR, Knutson BM. Immediate functional loading of single-tooth ITI implants in the anterior maxilla: a prospective 5-years pilot study. *Clin Oral Implants Res.* 2002;13:281-287.

7. Cooper LF, Rahman A, Moriarty J, Chaffee M, Sacco D. Immediate mandibular rehabilitation with endosseous implants: simultaneous extraction, implant placement, and loading. *Int J Oral Maxillofac Implants.* 2002;17:517-525.

8. Proussaefs P, Kan J, Lozada J, Kleinman A, Farnos A. Effects of immediate loading with threaded hydroxyapatite-coated root-form implants on single premolar replacements: a preliminary report. *Int J Oral Maxillofac Implants.* 2002;17:567-572.

9. De Bruyn H, Collaert B. Early loading of machined-surface Branemark implants in completely edentulous mandibles: healed bone versus fresh extraction sites. *Clin Implant Dent Relat Res.* 2002;4:136-142.

10. Collaert B, De Bruyn H. Early loading of four or five Astra Tech fixtures with a fixed cross-arch restoration in the mandible. *Clin Implant Dent Relat Res.* 2002;4:133-135.

11. De Bruyn M, Kisch J, Collaert B, Linden U, Nilner K, Dvarsater L. Fixed mandibular restorations on three early-loaded regular platform Branemark implants. *Clin Implant Dent Relat Res.* 2001;3:176-184.

12. Gatti C, Chiapasco M. Immediate loading of Branemark implants: a 24-month follow-up of a comparative prospective pilot study between mandibular

overdentures supported by conical transmucosal and standard MKII implants. *Clin Implant Dent Relat Res.* 2002;4:190-199.

13. Lorenzoni M, Pertl C, Zhang K, Wegscheider WA. In patient comparison of immediately loaded and non-loaded implants within 6 months. *Clin Oral Implants Res.* 2003;14:273-279.

14. Wolfinger GJ, Balshi TJ, Rangert B. Immediate functional loading of Branemark System implants in edentulous mandibles: clinical report of the results of developmental and simplified protocols. *Int J Oral Maxillofac Implants.* 2003;18:250-257.

15. Malò P, Rangert B, Nøber M. "All-on-four" immediate-function concept with Branemark System implants for completely edentulous mandibles: a retrospective clinical study. *Clin Implant Dent Relat Res.* 2003;5 (suppl):2-9.

16. Vanden Bogaerde L, Pedretti G, Dellacasa P, Mozzati M, Rangert B. Early function of splinted implants in maxillas and posterior mandibles using Branemark System machined-surface implants: an 18-month prospective clinical multicenter study. *Clin Implant Dent Relat Res.* 2003;5 (suppl):21-28.

17. Rocci A, Martignoni M, Gottlow J. Immediate loading in the maxilla using flapless surgery, implants placed in predetermined positions, and prefabricated provisional restorations: a retrospective 3-year clinical study. *Clin Implant Dent Relat Res.* 2003;5 (suppl):29-36.

18. Malò P, Friberg B, Polizzi G, Gualini F, Vighagen T, Rangert B. Immediate and early function of Branemark System implants placed in the esthetic zone: a 1-year prospective clinical multicenter study. *Clin Implant Dent Relat Res.* 2003;5 (suppl):37-46.

19. Ibanez JC, Jalbout ZN. Immediate loading of Osseotite implants: two-year results. *Implant Dent.* 2002;11:128-136.

20. Degidi M, Piattelli A. Immediate functional and non functional loading of dental implants: a 2 to 60 months follow-up study of 646 titanium implants. *J Periodontol.* 2003;74:225-241.

21. Gomez-Roman G, Schulte W, D'Hoedt B, Axman-Krcmar D. The Frialit-2 implant system: five-year clinical experience in single-tooth and immediately post-extraction applications. *Int J Oral Maxillofac Implants.* 1997;12:299-309.

22. Tarnow DP, Emtiaz S, Classi A. Immediate loading of threaded implants at stage 1 surgery in edentulous arches: ten consecutive case reports with 1- to 5-year data. *Int J Oral Maxillofac Implants.* 1997;12:319-324.



23. Balshi TJ, Wolfinger GJ. Immediate loading of Branemark implants in edentulous mandibles: a preliminary report. *Implant Dent.* 1997;6:83-88.

24. Schnitman PA, Wöhrle PS, Rubenstein JE, DaSilva JD, Wang NH. Ten-year results for Branemark implants immediately loaded with fixed prosthe-

ses at implant placement. *Int J Oral Maxillofac Implants.* 1997;12:495-503.

25. Grunder U. Immediate functional loading of immediate implants in edentulous arches: two-year results. *Int Periodontics Restorative Dent.* 2001;21:545-551.

26. Ericsson I, Nilson H, Lindh T, Nilner K, Randow K. Immediate func-

tional loading of Branemark single tooth implants. An 18 months clinical pilot follow-up study. *Clin Oral Implants Res.* 2000;11:26-33.

27. Wolfe LA, Hobkirk JA. Bone response to a matched modulus endosseous implant material. *Int J Oral Maxillofac Implants.* 1989;4:311-320.



### The SimPlant Platform

The standard for successful implantology

Materialise presents The SimPlant Platform, the only full service platform on the market providing you with integrated solutions for dental implants.

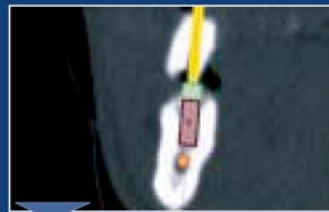The SimPlant Platform is a network of CT sites, SimPlant® digital treatment planning software and patented drill guide production technology, bringing oral implantology to a higher level.

**US: Materialise Clinical Services Inc.**  
810-X Cromwell Park Drive - Glen Burnie, MD 21061  
United States - Phone +1 443 557 0121  
Fax: +1 443 557 0036 - info@simplant.com

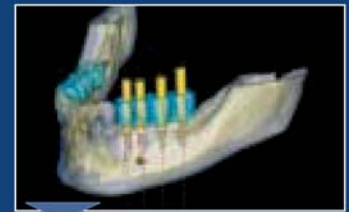**Europe: Materialise Headquarters**  
Technologielaan 15 - 3001 Leuven - Belgium  
Phone +32 16 39 66 11 - Fax: +32 16 39 66 00  
simplant@materialise.be

## Plan virtually...

Interactive CT Software for Predictable Treatment Planning of Dental Implants



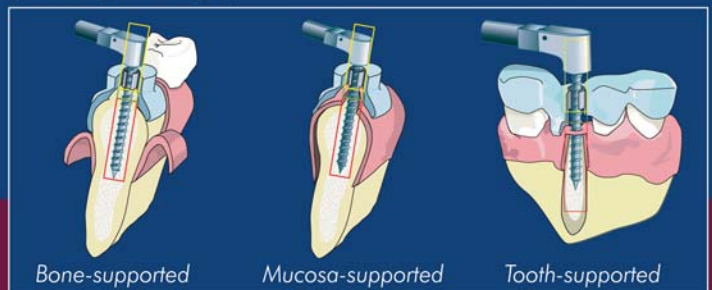
Easy Implant simulation...



... in 2D and 3D

## ... Operate successfully

SurgiGuides: Customized drill guides to transfer your planning to surgery



Bone-supported

Mucosa-supported

Tooth-supported

www.simplant.com

