

RESTORATION OF THE SOFT-TISSUE MARGIN IN SINGLE-TOOTH IMPLANT IN THE ANTERIOR MAXILLA

Jamil Awad Shibli, DDS, MS, PhD
Susana d'Avila, DDS, MS

KEY WORDS

Dental implants
Subepithelial connective
tissue graft
Keratinized mucosa
Single-tooth implant

Esthetic requirements for dental implant restoration have arisen in recent years. Despite several surgical techniques that have been developed, the treatment of the peri-implant soft-tissue defect is still difficult. The purpose of this clinical article is to describe a grafting technique using subepithelial connective tissue grafts to recontour soft-tissue margin discrepancy for single-tooth implant restorations in the anterior maxilla. After 2-year follow-up, this procedure shows that the use of connective tissue grafts can be a predictable approach to establish new and stable peri-implant soft-tissue margin.

INTRODUCTION

The predictability and long-term results in the restoration of both totally and partially edentulous subjects using dental implants have been demonstrated in the literature.^{1,2} However, the achievement of optimal esthetic restorations of a missing anterior tooth with dental implants may be complicated. Excessive alveolar ridge loss after tooth extraction and difficulties with soft-tissue manipulation may jeopardize the esthetically acceptable outcome. In addition, it is difficult to create an implant restoration with peri-implant margin position and contour that appears natural when the healing abutment exits the tissue toward the buccal third of the adjacent natural teeth.³

Accordingly, esthetic requirements have arisen from significant advancements in esthetic restorative dentistry in recent years.⁴⁻⁹ Despite several surgical techniques that have been developed, either the regeneration or the correction of peri-implant soft tissue is still difficult.⁹ The treatment plan often includes ridge augmentation procedures for both hard and soft tissue. In situations where soft-tissue deficiencies are the result of severe implant misalignment, the treatment of choice may be the removal of the dental implant. However, this may not be easily accepted by a patient.

Recently, some periodontal plastic surgery techniques have been used in the routine treatment of peri-implant soft-tissue defects.^{4,9-12} Soft-tissue grafts have been used to treat peri-implant

Jamil Awad Shibli, DDS, MS, PhD, is assistant professor, Department of Periodontology, Dental Research Division, Guarulhos University, Guarulhos, São Paulo, Brazil. Address correspondence to Prof Shibli at Centro de Pós-graduação, Pesquisa e Extensão – CEPPE, Universidade Guarulhos-UnG, Praça Tereza Cristina 01, Guarulhos, São Paulo 07023-070, Brazil (e-mail: jshibli@ung.br).

Susana d'Avila, DDS, MS, is a PhD student, Department of Dental Materials and Prosthodontics, Dental School of Araraquara, State University of São Paulo (UNESP), Araraquara, São Paulo, Brazil.

soft-tissue defects mainly in single-tooth implant restoration.^{9,10,12} The use of connective tissue graft to treat gingival recession around natural teeth is considered a very predictable surgical procedure.^{13,14} The major advantage of connective tissue grafting is recontouring the peri-implant margin and increasing the buccal volume of the peri-implant soft tissue.

This report describes the correction of an esthetic problem with 2 single-tooth dental implant restorations using a subepithelial connective tissue graft combined with the reestablishment of a new abutment margin and crown emergence profile. A 2-year follow-up is included.

CLINICAL CASE

A 26-year-old man presented for a periodontal and prosthodontic evaluation of a single-implant crown in the location of the maxillary right central incisor. The patient lost the natural tooth 5 years earlier due to a traffic accident. After a healing period of 4 months, a dental implant, combined with an autogenous bone graft and guided bone regeneration, was placed by an oral surgeon.

At the initial clinical and radiographic examination, an acceptable position and contour of both papillae was achieved. However, a soft-tissue margin labial to the implant restoration was considerably more apically located than the gingival margin on the adjacent natural tooth (Figure 1). The diagnostic cast showed an apico-coronal position of the implant shoulder located 3.0 mm apical to the cemento-enamel junction (CEJ) of the adjacent incisor. The abutment margin was positioned 2.0 mm apical to the CEJ of the adjacent

central incisor. Prior to the surgical procedure, a new abutment (abutment with profile emergence, hexagonal base; Titanium-Fix, São José dos Campos, São Paulo, Brazil) was selected to minimize the influence of the abutment margin on soft-tissue healing after the surgery. An interim prosthesis made of autopolymerizing acrylic resin (Biotone, Dentsply Ind Ltd, Petrópolis, Rio de Janeiro, Brazil) was created to allow a new soft-tissue profile during the healing period.

In another case, a 45-year-old woman was referred to a prosthodontist for implant restoration. The dental implant was located 4.0 mm apical to the CEJ of the adjacent central incisor (Figure 2). In addition, the healing abutment showed an emergence profile through nonkeratinized mucosa. The subject presented with a deficient peri-implant soft-tissue contour in the buccal-palatal axis. An angled-abutment (15° angle, hexagonal base; Conexão Implants, São Paulo, Brazil) was selected to minimize the influence of the abutment margin on soft-tissue healing after the surgery.

Surgical procedures

Following the abutment replacement, the surgical area was anesthetized (articaine hydrochloride 2%, DFL; Industria e Comércio, Rio de Janeiro, Brazil) using local infiltration. A combined full- and partial-thickness flap was made without perpendicular incisions to avoid scars. The recipient surgical site was left undisturbed.

Donor connective tissue was obtained from the palate using a technique previously described.^{9,15} The epithelial band was removed from the graft and only the subepithelial connective tissue was used. The graft was

immediately placed onto the polished abutment surface and the prepared recipient tissue bed, and stabilized with 2 interproximal and 1 apical resorbable 4-0 suture (Polyvicryl, Vicryl; Ethicon Inc, Somerville, NJ). The flap was then coronally repositioned fully covering the graft and sutured with interrupted sutures (Ethicon, Johnson & Johnson, São José dos Campos), applying special care to avoid excessive tension. A postoperative antibiotic regimen (amoxicillin, 500 mg, every 8 hours for 7 days) was prescribed.

Restorative procedures

Three months after the surgery, an implant level impression using a screw-retained transfer coping was made and the resulting master cast was used for a new abutment selection and crown design. A second interim prosthesis (Biotone) was prepared on the master cast to develop a new emergence profile for the final restoration. This interim prosthesis was highly polished so that it would not jeopardize the health of the peri-implant soft tissue.

The final shape of the abutment was designed according to the longitudinal axis of the dental implant and guided by the surfaces of the adjacent teeth. The abutment shoulder was prepared between 1.0 and 3.0 mm below the gingival level following the scallop of the peri-implant margin. One month after the surgical soft-tissue correction, the abutment was placed with a screw-tightening torque of 20 Ncm as recommended by the manufacturer. A thin layer of condensed white gutta-percha (Dentsply) was used to isolate the screw. The second interim prosthesis was in place until the final restoration was complete.

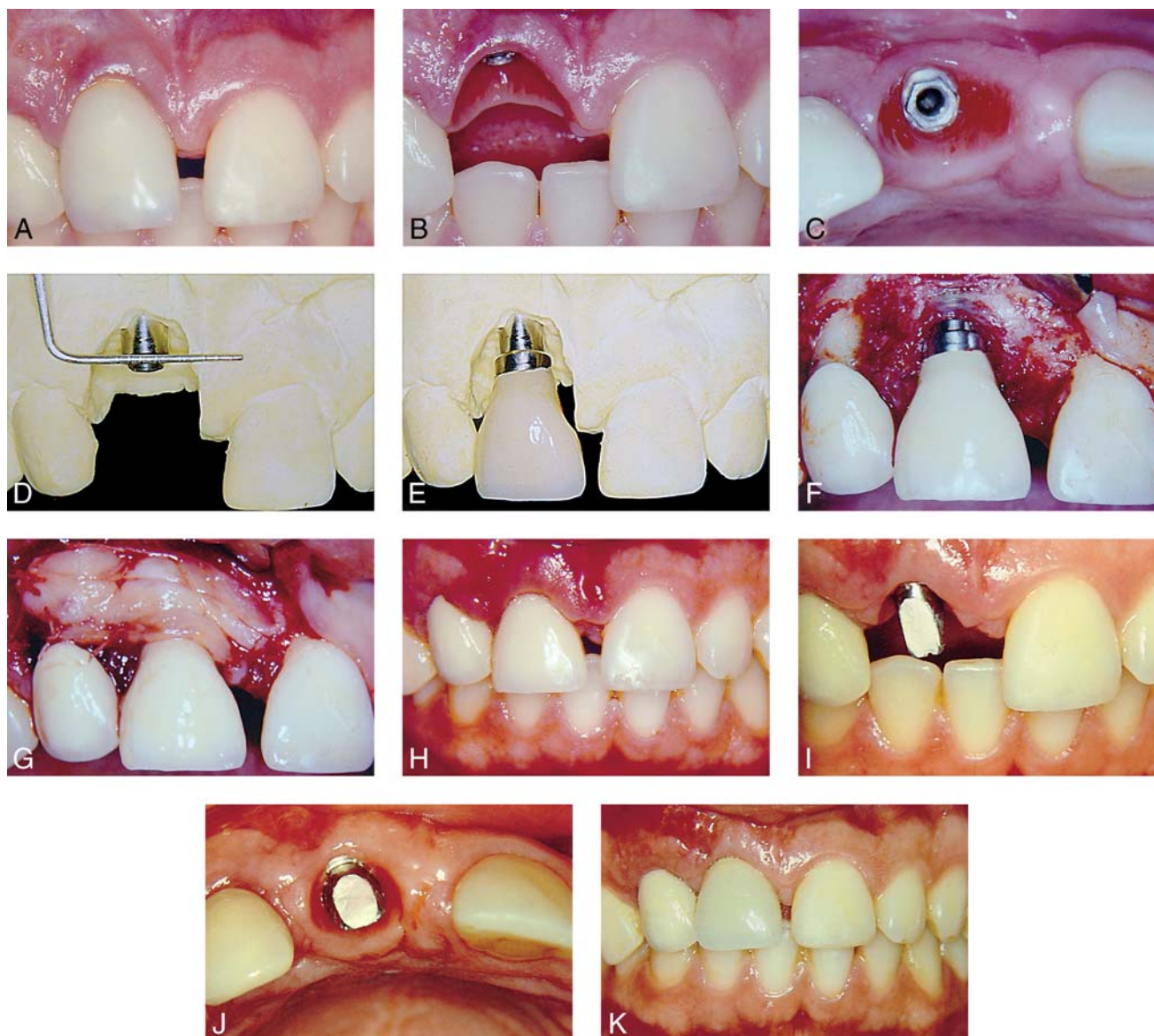


FIGURE 1. (A) Clinical view showing difference of gingival level of tooth and peri-implant margin. (B) Presence of acceptable position and contour of both papillae. (C) Deficient contour of peri-implant soft tissue in the buccal-palatine axis. (D) Diagnostic cast showing an apical position of the implant shoulder. (E) Clinical view of the interim prosthesis made on the new abutment. (F) Mucoperiosteal flap without perpendicular incisions with the new implant restoration in position. (G) Connective tissue graft on the surgical site stabilized with interproximal and apical resorbable suture. (H) Clinical view 21 days post surgery. (I) Presence of acceptable peri-implant tissue contour 5 months post surgery. (J) Correct contour of peri-implant soft tissue in the buccal-palatine axis. (K) Metal-ceramic restoration in position after 2 year-follow up.

Five months after the surgery, the final impression was made using an individual resin coping (DuraLay, Reliance Dental Mfg Co, Worth, Ill) and polyether impression material (Impregun F, ESPE America Inc, Norristown, Pa). A metal-ceramic restoration was then manufactured as the final restoration. After occlusal

and proximal adjustments, the final crown was luted with provisional cement (Temp-Bond, Kerr Corporation, Orange, Calif) so that it could be removed if additional changes were necessary. After 2 weeks, the final restoration was cemented with zinc phosphate cement (SS White Artigos Dentários, Rio de Janeiro, Brazil).

At the 2-year recall appointment, the adjacent peri-implant soft tissues were stable, and both patients were pleased with the final esthetic results. The peri-implant mucosa margin was 2.0 to 3.0 mm more coronal and at the same level of the adjacent central incisor. There was no erythema or bleeding upon probing.

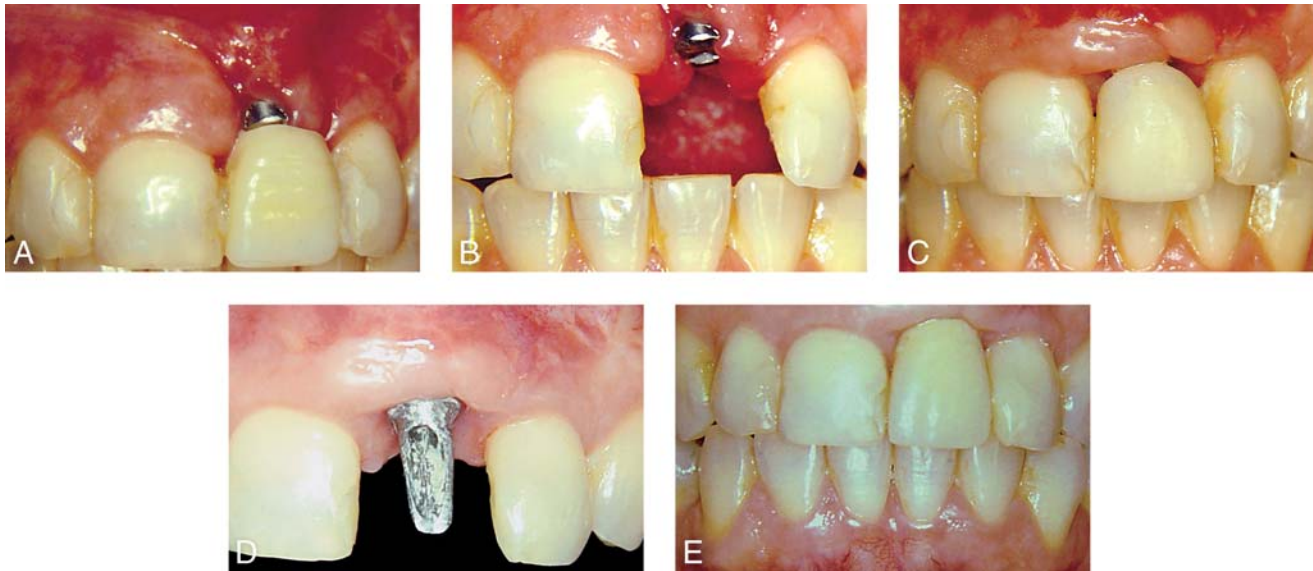


FIGURE 2. (A) Clinical view of peri-implant margin discrepancy. (B) After removal of provisional restoration, the healing abutment presented an emergence profile of nonkeratinized mucosa. (C) Clinical view 45 days post surgery. (D) The abutment shoulder was prepared approximately 1.0 mm below the gingival level following the scallop of the peri-implant margin. (E) Final view of the implant-restoration 2 years post surgery; note the increase of keratinized tissue.

DISCUSSION

These case reports presented a useful treatment for correction of peri-implant margin. Similar to gingival recession in the natural dentition, the described subepithelial connective tissue graft associated with coronal repositioning of the peri-implant mucosa allowed the development of improved soft-tissue contours and implant restoration emergence profile. The peri-implant margin was reestablished leading to a significant esthetic improvement in both patients. The other important factor evaluated in this clinical report was the repositioning of the abutment shoulder by selecting a new abutment. Placing the abutment-restoration junction closer to the CEJ of the adjacent teeth maintained the marginal integrity of the new restoration as previously described.⁹

In addition, the technique described in this clinical paper demonstrates a successful peri-implant soft-tissue reconstruction with a stable esthetic result over

2 years, and can be considered a usual procedure.⁷⁻¹² However, the position of the dental implant shoulder in relation to the CEJ, the amount of keratinized tissue, and the dental implant inclination in the buccolingual axis can alter both the surgical technique and clinical outcomes.⁹

In conclusion, this report suggests that a subepithelial connective tissue graft combined with restorative modifications can be a feasible approach to correct unfavorable peri-implant soft margin, provided that adequate bone support exists.

REFERENCES

1. van Steenberghe D, Quirynen M, Naert I. Survival and success rates with oral endosseous implants. In: Lang NP, Karring T, Lindhe J, eds. *Proceedings of the 3rd European Workshop on Periodontology*. Berlin, Germany: Quintessence Books. 1999:242-254.
2. Branemark PI, Svensson B, van Steenberghe D. Ten year survival rates of fixed prostheses on four or six implants

ad modum Branemark in full edentulism. *Clin Oral Implants Res*. 1995;6:227-231.

3. Potashnick SR. Soft tissue modeling for the esthetic single-tooth implant restoration. *J Esthet Dent*. 1998;10:121-131.

4. Kazor CE, Al-Shammari K, Sarmant DP, Misch CE, Wang H-L. Implant plastic surgery: a review and rationale. *J Oral Implantol*. 2004;30:240-254.

5. Cranin AN. Implant surgery: the management of soft tissues. *J Oral Implantol*. 2002;28:230-237.

6. Chee WL. Provisional restorations in soft tissue management around dental implants. *Periodontol 2000*. 2001;27:139-147.

7. Khoury F, Happe A. The palatal subepithelial connective tissue flap method for soft tissue management to cover maxillary defects: a clinical report. *Int J Oral Maxillofac Implants*. 2000;15:415-418.

8. Khoury F, Hoppe A. Soft tissue management in oral implantology: a review of surgical techniques for shaping an esthetic and functional peri-implant soft tissue structure. *Quintessence Int*. 2000;31:483-499.

9. Shibli JA, d'Avila S, Marcantonio Jr. E. Connective tissue graft to correct peri-implant soft tissue margin: a clinical report. *J Prosthet Dent*. 2004;91:119-122.

10. Price RBT, Price DE. Esthetic restoration of a single-tooth dental implant using a subepithelial connective tissue graft: a case report with 3-year

follow-up. *Int J Periodontics Restorative Dent.* 1999;19:93–101.

11. Maksoud MA. Manipulation of the peri-implant tissue for better maintenance: a periodontal perspective. *J Oral Implantol.* 2003;29:120–123.

12. El-Askary AES. Multifaceted aspects of implant esthetics: the anterior maxilla. *Implant Dent.* 2001;10:182–191.

13. Rosetti EP, Marcantonio RA, Rossa Jr. C, Chaves RS, Goissis G, Marcantonio Jr. E. Treatment of gingival recession: comparative study between subepithelial connective tissue graft and guided tissue regeneration. *J Periodontol.* 2000;71:1441–1447.

14. Hirsch A, Goldstein M, Goult-schin J, Boyan BD, Schwartz Z. A 2-year

follow-up of root coverage using sub-pedicle acellular dermal matrix allografts and subepithelial connective tissue auto-grafts. *J Periodontol.* 2005;76:1323–1328.

15. Bruno JF. Connective tissue graft technique assuring wide root coverage. *Int J Periodontics Restorative Dent.* 1994;14:27–37.

MEISINGER Bone Management®

- Suitable for all current dental implant systems
- Easy handling in complicated indications
- Substance saving for its minimally invasive procedures

Benex® -Control

Root Extraction

- Safe and simple extraction of roots
- Maximum protection of the tooth socket
- Possibility of drilling even if minute root fragments or foreign bodies are present in the root
- Possibility of drilling independently of anatomic root canal

MEISINGER

GERMANY / USA

Meisinger USA, L.L.C.
 7442 South Tucson Way, Suite 130
 Centennial, Colorado 80112 • USA
 Tel., (303) 268-5400
 Fax, (303) 268-5407
 Toll free, (866) 634-7464
 Internet, www.meisingerusa.com
 www.bone-management.com
 E-mail, info@meisingerusa.com

Art.-No.: BE001230000