

IMPLANT PLACEMENT AFTER MARSUPIALIZATION OF A DENTIGEROUS CYST

S. Karamanis, DDS
Th. Kitharas, DDS
D. Tsoukalas, DDS
N. Parissis, DDS

KEY WORDS

Marsupialization
Dentigerous cysts
Implant placement

This paper presents a case of a dentigerous cyst accompanied by a history of inflammation, resorption of the roots of the first molar and the lingual aspect of the distal root of the second molar, and devitalization of the 2 premolars. The treatment option chosen was marsupialization of the cyst, extraction of the involved teeth, endodontic treatment of both premolars, and implant insertion in the area of the first mandibular molar at a later stage. Twelve months postsurgery the area of interest was almost flattened and the radiographic examination revealed total disappearance of the radiolucency. An implant of 15 × 4 mm was inserted in the area of the first mandibular molar. Despite the excellent implant stability achieved, a thin central zone of the defect remained void of bone. After complete excision of soft tissue the defect was filled with an alloplastic bone substitute. Eight months later (20 months postsurgery), the implant was uncovered and the restorative procedure completed. The implant and the crown have been functioning sign and symptom free for 48 months. Marsupialization was preferred instead of enucleation due to (1) proximity of the cyst to the mandibular canal; (2) need for apicectomy of both premolars to gain good access for enucleation; (3) refusal of the patient to undergo a second surgery for bone harvesting; (4) lower probability for postoperative contamination; (5) need of small quantity of bone substitute; (6) easier extraction of the impacted second molar due to its coronal movement. The disadvantages of the treatment were the long healing period and the discomfort of the patient at the early stages of marsupialization. It was judged that the advantages outweighed the disadvantages in this case. We discuss the findings of other authors who support the conservative approach to jaw cysts in a young population, and the concerns that exist in the literature about the ability of osseoconductive graft materials to generate vital bone and achieve implant-to-bone contact.

S. Karamanis, DDS, is a teaching assistant, D. Tsoukalas, DDS, is a lecturer, and N. Parissis, DDS, is an associate professor at the Department of Dental-veolar/Implant Surgery and Radiology, Aristotle University of Thessaloniki, School of Dentistry, Greece.

Address correspondence to Dr Karamanis, G. Papazoli 3, 546 30 -Thessaloniki, Greece (e-mail: karamaniss@yahoo.gr).

Th. Kitharas, DDS, is a general practitioner in Kavala, Greece.

INTRODUCTION

Implant placement, after enucleation of jaw cysts and bone grafting, is an acceptable and well-documented procedure in clinical practice.¹⁻⁴ There are cases, however, where cyst enucleation may present a potential risk of damaging sensitive anatomic structures such as the mandibular nerve canal. On the other hand, graft procedures—especially when a large defect is to be filled—are a concern for a number of patients. Although marsupialization is a reliable alternative in these cases, to our knowledge there is a lack of references to implant placement after bone regeneration via marsupialization. This paper presents a case of single implant placement after marsupialization in the mandible and discusses the advantages and disadvantages of this treatment option.

CASE REPORT

An 18-year-old female patient presented to the clinic with a history of pain and swelling in the left mandible. At that time, clinical examination revealed nothing out of the ordinary. The panoramic examination, however, revealed a large, ovoid, and well-defined radiolucency, extending from the third left mandibular molar up to the first premolar and containing the second molar. The roots of the first molar presented partial resorption, while the lower borders of the lesion were in close proximity to the roof of the mandibular canal. The apices of both premolars were within the lesion and the pulp vitality test was negative for both. The initial diagnosis was dentigerous cyst (Figure 1). The plan was the

endodontic treatment of the premolars, extraction of the first molar, marsupialization of the cyst, and orthodontic movement of the second molar.

The removal of the cyst wall was performed through the post-extraction socket of the first molar. In order to facilitate the second molar's erupting, the incision and bone removal were extended distally (Figures 2 and 3). Intra-operatively however, resorption of the lingual aspect of the distal root of the second molar was noted. Extraction of the second molar was then preferable to moving it orthodontically. The extraction was performed 3 months later because of the close proximity of its apices to the mandibular canal. The biopsy of the cyst wall revealed absence of keratinized epithelium and therefore confirmed the initial diagnosis.

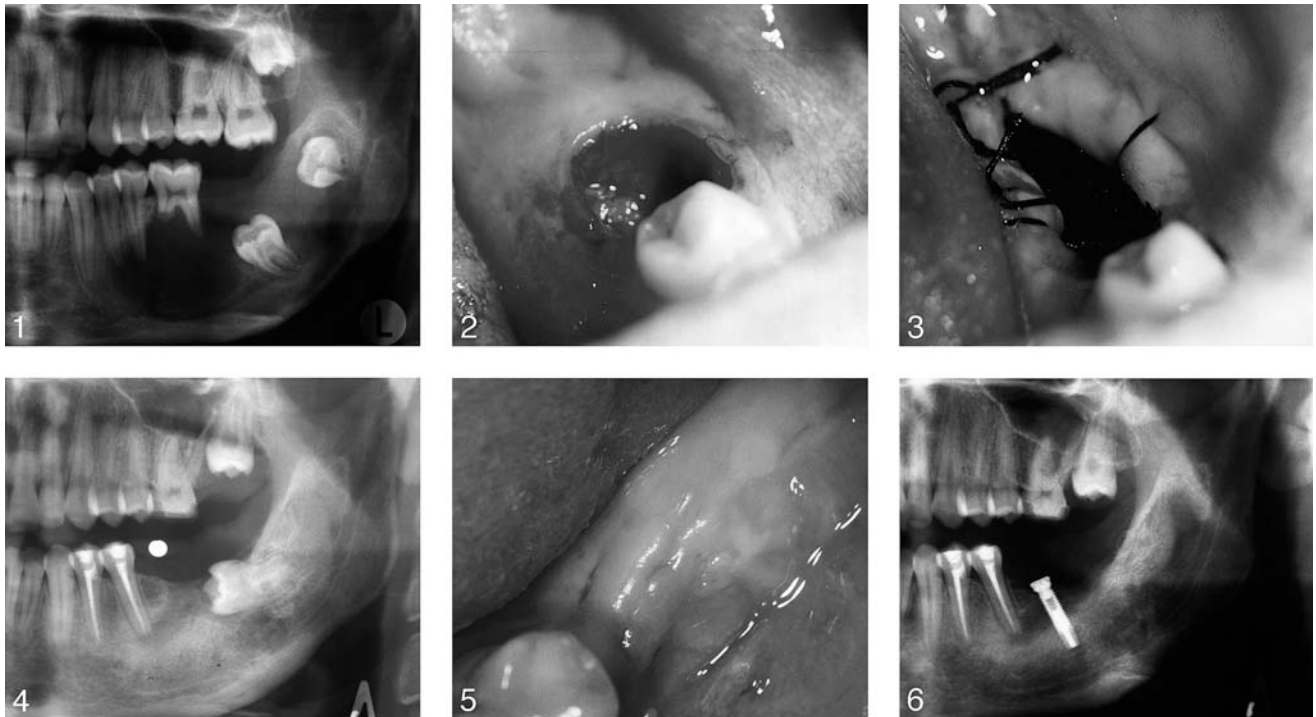
Twelve months after marsupialization almost total disappearance of the radiolucency was noted. Moreover, the radiograph showed that a sufficient amount of bone was deposited over the roof of the mandibular canal (Figure 4). A very satisfactory clinical result was observed; the defect was flattened and totally covered by oral mucosa (Figure 5). In addition, no hyperplastic tissues or fistulas were observed. An implant of 15 × 4 mm (ICE, 3i Implant Innovation Inc, Palm Beach, Fla) was inserted in the region of first left mandibular molar (Figure 6). The bone formation on the buccal and lingual aspect of the defect was very satisfactory and resulted in excellent primer stability of the implant. However a thin central zone of the defect remained devoid of bone. After intensive excision of all soft tissues, an alloplastic bone substitute was placed (Biogran, Orthovita, Mal-

vern, Pa). Eight months later (20 months postsurgery), the implant was uncovered and the restorative procedure (customized University of California at Los Angeles abutment and cement-fixed metal-ceramic crown) followed. The implant and the crown have been functioning for 48 months postinsertion, with no clinical, radiographic signs or symptoms observed or reported by the patient (Figures 7 and 8).

DISCUSSION

After considering procedural advantages, marsupialization instead of enucleation was performed in this case for the following reasons.

There was no possibility of damaging the nerve canal. Although asymptomatic dentigerous cysts do not usually involve the mandibular canal and subsequently are easily separated from surrounding tissues and removed, this might not be expected in cases with a history of inflammation. The possible existence of adhesions may have complicated the procedure and made it less predictable. Beside these anatomic and surgical concerns, enucleation would have resulted in the creation of a large defect. The size of the latter would have necessitated grafting procedures in order to be filled, partially by autologous bone, making the operation more invasive and complex. Further, the patient was not anxious to undergo a second operation. In addition there are still controversies with respect to the ability of osseointegrating graft materials, when used alone, to generate vital bone comparable to the preexisting one and to mimic the natural mechanical properties. Tadjedin et al⁵ and Cordioli



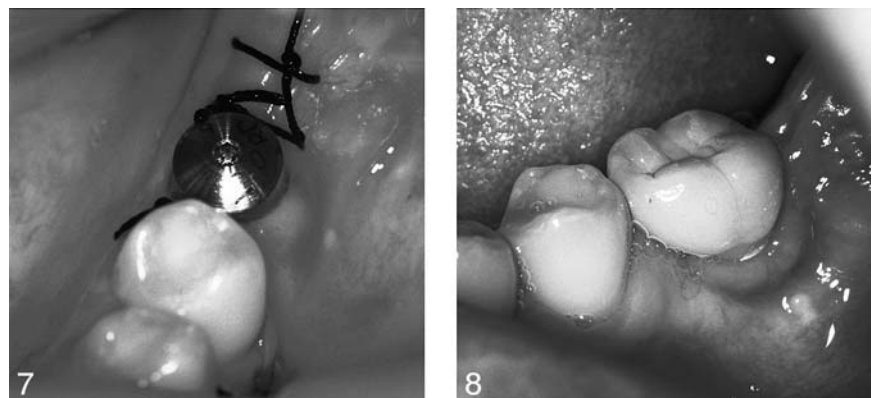
FIGURES 1–6. FIGURE 1. Initial radiograph. FIGURE 2. Postextraction socket. FIGURE 3. Access via the distal extension of the socket. FIGURE 4. Radiograph before implant placement. FIGURE 5. Clinical condition before implant placement. FIGURE 6. Radiograph immediately after implant placement.

et al⁶ reported satisfactory bone regeneration patterns when bioactive glass was used as bone substitute in sinus lift procedures, but only in combination with autologous bone. Carmagnola et al⁷ reported that although they confirmed new bone formation after grafting defects with osseoconductive bone xenograft, histological examinations revealed absence of bone-implant contact. On the other hand, Valentini et al⁸ stated that both osteogenesis and bone-implant contact were satisfactory after placement of osseoconductive bone xenografts. It is worthy of mentioning that the long-term good prognoses of dental implants are related to their placement in preexisting natural bone.^{9,10} To our knowledge, positive long-term results, fully comparable to the previous ones of implant survival rates, currently

are not available for insertion in newly generated bone.

Enucleation, unlike marsupialization, would have necessitated apicectomy of both premolars in order to gain good access and completely remove the cyst. This would have made the surgery more invasive. Alternative-

ly we performed conventional endodontic treatment. It is a matter of concern, however, that although dentigerous cysts do not usually prevent blood supply to the pulp of the adjacent teeth due to their slow development, the premolars were non-vital (confirmed by the vitality



FIGURES 7 AND 8. FIGURE 7. Clinical condition before prosthetic restoration. FIGURE 8. Clinical condition after 48 months.

test). It is speculated that the history of inflammation of this area may have influenced the pulp vitality of these teeth.

Additional reasons for marsupialization rather than enucleation were that the potential risk of postoperative inflammation would have been greater after enucleation and bone grafting in a large defect like this; the quantity of alloplastic graft material needed was very small; and the extraction of the second molar was easier due to its movement coronally.

It is unclear to us why this tooth presented with root resorption. A possible explanation might be that the cyst formation process preceded that of amelogenesis, and this in part influenced the completion of the latter.

The disadvantages of the chosen treatment plan were the long healing period and the relative discomfort of the patient, especially during the initial phase of marsupialization (due to the use of the stent). It was estimated, however, that the advantages mentioned above outweighed the disadvantages in this case.

It is believed that a more conservative surgical management of jaw cysts in a young population might be preferable because of the rapid developmental changes in this area. This approach is consistent with the findings of Bonder¹¹ and Jones et al.¹² The panoramic images in our case revealed sufficient bone apposition over the roof of the mandibular canal. This is consistent with the findings of Bonder et al.¹³ who used more advanced imaging modalities, such as CT with multiplanar reconstruction. They also observed

postmarsupialization remodeling of the cortex of the mandibular canal and the increased distance between the cyst's wall and adjacent structures.

CONCLUSION

Implant insertion after marsupialization of a cyst defect, in combination with placement of a small quantity of an osseointegrative bone substitute, may present an advantageous alternative solution over enucleation, when anatomic limitations are a concern, and autograft procedures, especially in a young population, are not acceptable as a treatment option. However, this paper is a case report and more scientific data in this field are necessary.

NOTE

The information presented here was reported at the 23rd Pan-Hellenic Dental Congress, Athens, 2003. The authors claim to have no financial interest in any company or product mentioned in this article.

REFERENCES

1. Barry CP, Kearns GJ. Case report—odontogenic keratocysts: enucleation, bone grafting and implant placement: an early return to function. *J Ir Dent Assoc.* 2003;49:83–88.
2. Goto M, Jin-Nouchi S, Ihara K, Katsouki T. Longitudinal follow-up of osseointegrated implants in patients with resected jaws. *Int J Oral Maxillofac Implants.* 2002;17:225–230.
3. Sakamoto E, Shimada J, Takeshima H, et al. Reconstruction of occlusal function with osseointegrated implant follow-

ing mandibular resection. *Meikai Daigaku Shigaku Zasshi.* 1990;19:424–436.

4. Bredfeldt GW, Dixon RA, Granado J. Implant restoration following removal of an odontogenic keratocyst: a clinical report. *J Prosthet Dent.* 1992;68:217–219.

5. Tadjoein ES, de Lange GL, Lyaruu DM, Kuiper L, Burger EH. High concentrations of bioactive glass material (Biogran) vs. autogenous bone for sinus floor elevation. *Clin Oral Implants Res.* 2002;13:428–436.

6. Cordioli G, Mazzocco C, Schepers E, Brugnolo E, Majzoub Z. Maxillary sinus floor augmentation using bioactive glass granules and autogenous bone and simultaneous implant placement. Clinical and histological findings. *Clin Oral Implants Res.* 2001;12:270–278.

7. Carmagnola D, Berglundh T, Araujo M, Albrektsson T, Lindhe J. Bone healing around implants placed in jaw defect augmented with Bio-Oss. An experimental study in dogs. *J Clin Periodontol.* 2000;27:799–805.

8. Valentini P, Abensur DJ, Densari D, Graziani JN, Hammerle C. Histological evaluation of Bio-Oss in a 2-stage sinus floor elevation and implantation procedure. A human case report. *Clin Oral Implants Res.* 1998;9:59–64.

9. Lekholm U, Gunne J, Henry P, et al. Survival of the Branemark implant in partially edentulous jaws: a 10-year prospective multicenter study. *Int J Oral Maxillofac Implants.* 1999;14:639–645.

10. Adell R, Lekholm U, Rockler B, et al. A 15-year study of osseointegrated implants in the treatment of the edentulous jaw. *Int J Oral Surg.* 1981;6:387–416.

11. Bodner L. Cystic lesions of the jaws in children. *Int J Pediatr Otorhinolaryngol.* 2002;62:25–29.

12. Jones TA, Perry RJ, Wake MJ. Marsupialization of a large unilateral mandibular dentigerous cyst in a 6-year old boy—a case report. *Dent Update.* 2003;30:557–561.

13. Bodner L, Woldenberg Y, Bar Jiv J. Radiographic features of large cystic lesions of the jaws in children. *Pediatr Radiol.* 2003;33:3–6.