

# BONE HEALING AT A FAILED IMPLANT SITE IN A TYPE II DIABETIC PATIENT: CLINICAL AND HISTOLOGIC EVALUATIONS: A CASE REPORT

Jun-Beom Park, DDS, MSD

Placement of endosseous dental implants in diabetic patients may be compromised because of altered wound healing. Additionally there is no established timetable for implant healing in these patients. A case report is presented that evaluates implant healing at the site of a failed implant after its removal. This report documents bone remodeling in a diabetic patient 6 months after removing the failed implant. The prostheses was delivered within 4 months in the upper arch despite the complications during the healing period.

**Key Words:** diabetes, dental implants, failed implant

## INTRODUCTION

**T**ype II diabetes is a significant disorder seen around world. It has been projected that the number of diabetic patients will rise from an estimated 135 million in 1995 to 300 million in 2025.<sup>1</sup> Diabetes is prevalent in Korea with approximately 7.6% of the population, or 1 of every 13 people, having diabetes.<sup>2</sup>

Type II diabetes results from a progressive insulin secretory defect against the background of insulin resistance. It is diagnosed as diabetes when fasting plasma glucose reaches or exceeds 126 mg/dL. Goodman and Hori<sup>3</sup> reported that bone and matrix formation and apposition were decreased in an experimental diabetic model.

Diabetes is associated with systemic adverse sequelae such as compromised wound healing, which may affect osseointegration of dental implants. The influence of diabetes on the survival of endosseous dental implants has been evaluated in well-controlled animal studies,<sup>4,5</sup> but there are limited data available concerning the clinical outcome of implant treatment for patients with diabetes mellitus.<sup>6-11</sup>

Despite the high success rate for endosseous implants, some implants inevitably fail. Two common factors associated with implant failures are bacterial infection and occlusal load.<sup>12,13</sup>

In this case report, an implant was placed 6 months after removing a failed implant in a type II diabetic patient. Bone healing was evaluated by harvesting a bone sample at the time that the failed implant was replaced.

## MATERIALS AND METHODS

### Case

A 50-year-old male with type II diabetes presented for the evaluation of the upper right area to the Department of Periodontology at the Armed Forces Capital Hospital. The patient was referred to his physician for further evaluation of this area and his diabetes, which was controlled with diet and oral hypoglycemic agents.

The upper right 2nd premolar and upper right 1st and 2nd molars were extracted because of severe periodontitis (Figure 1). Following 2 months of healing, 3 implants (Implantium, Dentium, Seoul, Korea) were placed in the upper right sextant with the insertion torque of 40 Ncm. Two grams of amoxicillin was administered orally preoperatively, according to the recommendation by the American Heart Association,<sup>14</sup> and a chlorhexidine rinse was done immediately before implant surgery. The patient was placed on amoxicillin at 500 mg 3 times per day

*Jun-Beom Park, DDS, MSD, is the former head of the Department of Periodontology, Armed Forces Capital Hospital, Seoul, Korea. He is currently at the Department of Periodontology, School of Dentistry, Seoul National University. Address correspondence to Dr Park at Department of Periodontology, School of Dentistry, Seoul National University, 28-2 Yongon-Dong, Chongno-Gu, Seoul 110-749, Korea (e-mail address: jbassoonis@yahoo.co.kr).*

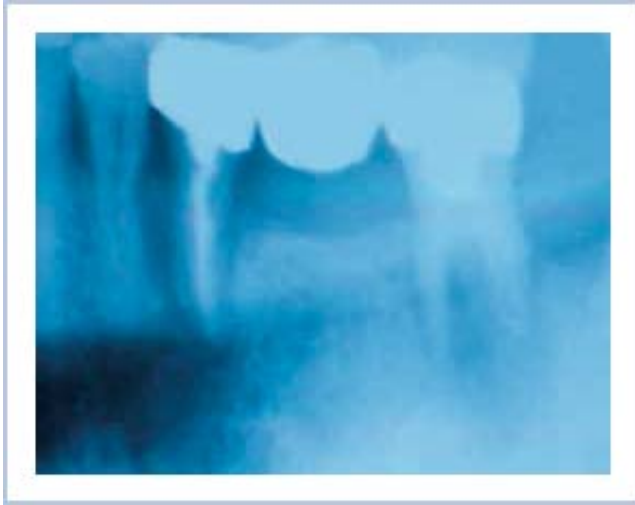


FIGURE 1. Radiograph showing apically involved teeth in the upper right posterior sextant.

for 5 days; mefenamic acid at 500 mg initially, then 250 mg 4 times per day for 5 days; and 0.12% chlorhexidine digluconate 3 times per day for 2 weeks. The patient was asked not to chew or brush the surgical area for the first 4 weeks postoperatively. During the healing period, diabetic control was monitored by measuring blood glucose levels. Efforts were made to meet the preprandial capillary plasma glucose level recommended by the American Diabetes Association (preprandial capillary plasma glucose 90–130 mg/dL and peak postprandial capillary plasma glucose <180mg/dL)<sup>15</sup> and hemoglobin A1C goal for the patients in general (<7%).<sup>15</sup> The patient monitored blood glucose level weekly and the level at the initial visit and at the last visit were 120 and 112 mg/dL, respectively. The hemoglobin A1C level during the healing period was 6.5%.

At 2 weeks, the cover screws of the 3 implants were exposed (Figure 2). Because there were no clinical signs of inflammation and suppuration, professional cleaning of cover screws, reinforcement of oral hygiene, rinsing with 0.12% chlorhexidine digluconate, and shortening of recall periods were done. The cover screws were removed and the healing abutments were placed after 1 month of healing. When the abutments were placed, the implant in the upper right 2nd premolar area showed mobility, and was removed. The implant site was thoroughly debrided with hand instruments and irrigated with saline solution. No hard and soft tissue grafting was done.

Six months after removal of the implant, a replacement was placed at the site of the failed implant (Figure 3). Bony preparation was done with a 2.75-mm trephine drill (inner diameter) and the final drill for

a 4.3-mm implant. The core of 2.7 × 10 mm, harvested with the trephine drill, was sent to the Department of Pathology at the Armed Forces Capital Hospital for processing for histologic evaluation. The implant was placed with the insertion torque of 40 Ncm. A healing abutment and sutures were placed using a one-stage approach obviating 2nd stage surgery.

The retrieved specimen was fixed in 10% neutral buffered formalin solution and decalcified. The specimen was then dehydrated through a series of ethanol solutions of increasing concentrations. The blocks were embedded, cut, ground, and then stained with hematoxylin and eosin. The slide was examined using a light microscope (Olympus BH-2, Olympus Optical, Osaka, Japan).

The final implant-supported crowns for upper 1st and 2nd molars were inserted 8 months after implant installation. The final crown for the upper 2nd premolar was placed 4 months after reimplantation.

The concentric lamellar in the Haversian systems and lacunae with osteocytes were observed in the specimen. Hematopoietic tissue and adipose tissue could be identified throughout the specimen (Figure 4).

The patient reported no specific symptoms and he did not show any clinical signs of implant failure. The prosthesis was functioning well up to 6 months (Figure 5a and b) and the patient was scheduled for follow-up visits every 6 month.

## DISCUSSION

Diabetic patients experience more infection in clean wounds than nondiabetics.<sup>16</sup> Poorly controlled or labile diabetes presents more difficult management problems. It is recommended to postpone surgery until ideal glucose control and protein nutrition are achieved.<sup>17</sup>

Efforts were made to meet the preprandial capillary plasma glucose level recommended by the American Diabetes Association and hemoglobin A1C goal for patients in general.<sup>15</sup> By performing A1C test, a patient's average glycemia over the preceding 2 to 3 months can be measured.<sup>15</sup>

Implant failures can be ascribed to two common factors: bacterial infection and occlusal load.<sup>12,13</sup> Implants that fail due to peri-implantitis show clinical signs very similar to those found around periodontally diseased teeth, such as bleeding, suppuration, pain, mobility, increased probing depth, radiographic evidence of bone loss, and presence of periopathogenic bacteria.<sup>18</sup>

Preoperative antibiotics and chlorhexidine rinsing were done to reduce complications in the patient described in this report. Peterson<sup>19</sup> recommended that maximum reduction of infectious complications was

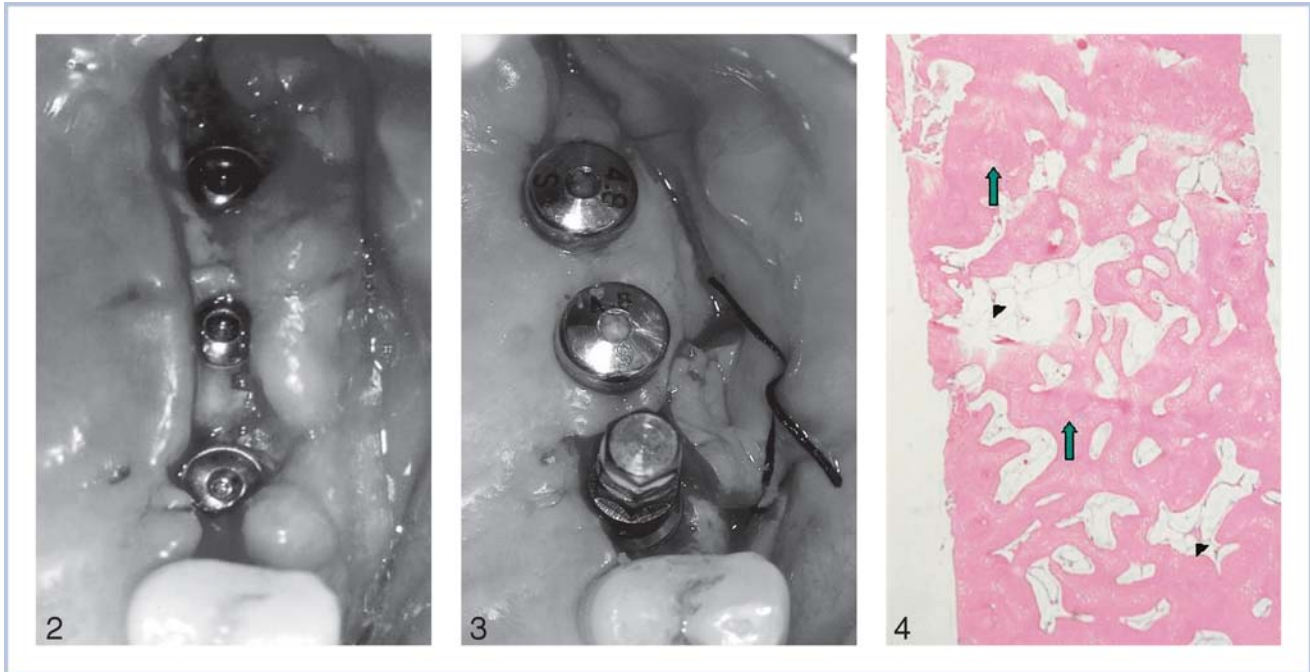


FIGURE 2–4. FIGURE 2. Delayed soft tissue healing at 2-week period and cover screw exposure. FIGURE 3. Implant inserted into the 2nd premolar site, 6 months after removal of the failed implant. FIGURE 4. Histologic view of biopsy 6 months after removing a failed implant. Concentric lamellar in the Haversian systems and lacunae with osteocytes can be seen (arrow). There is hematopoietic tissue and adipose tissue throughout the specimen (arrow head) (hematoxylin and eosin, original magnification  $\times 20$ ).

achieved with appropriate use of preoperative, high-dose antibiotic administration. Dent et al<sup>20</sup> reported that significantly fewer failures occurred in implant-treated patients when preoperative antibiotics were used. Morris et al<sup>11</sup> found that the survival for those implants placed with preoperative antibiotics was 4.5% higher than implants not provided coverage at placement surgery. It is reported that the use of chlorhexidine before and after implant placement produced beneficial results for type II diabetic patients.<sup>11</sup>

Diabetes alters wound healing, which may affect osseointegration of dental implants. The influence of diabetes on the survival of endosseous dental implants has been evaluated in well-controlled animal studies. Iyama and colleagues<sup>4</sup> found that the bone formation around a hydroxyapatite implant away from the endosteum and periosteum was suppressed in the diabetic model. Ottoni and Chopard<sup>5</sup> reported that new bone formation in medullar canal and in bone-to-implant contact in the medullar portion was significantly decreased in diabetic rats.

There are few reports concerning the clinical outcome of implant treatment for patients with diabetes mellitus. Shernoff et al<sup>6</sup> found that the short-term failure rate in 89 type II diabetic patients was 2.2%. The rate increased to 7.3% by the end of the 1st year in 89 type II diabetic patients. Kapur et al<sup>7</sup> reported no implant failures in 52 type I and II diabetic

patients followed for 2 years. Smith et al<sup>8</sup> also reported no implant failures in 4 type I and II diabetic patients. Mericske-Stern and Zarb<sup>9</sup> reported a 91.2% 5-year success rate in 25 diabetic patients in Toronto and a 92.2% success rate in 34 patients in Bern. Olson et al<sup>10</sup> reported that the overall survival rate from prosthesis placement through the 60-month follow-up in 58 patients was approximately 88%. Morris et al<sup>11</sup> found that type 2 diabetic patients tend to have more failures than nondiabetic patients, however, the difference was marginally significant.

The insertion torque in this case was 40 Ncm and Ottoni et al<sup>21</sup> mentioned that an insertion torque above 32 Ncm was necessary to achieve osseointegration. The exposed cover screw was removed and then the healing abutment was placed to achieve better hygiene as recommended by Barboza and Caula<sup>22</sup>. Covani et al<sup>23</sup> reported immediate implantation following explantation of fractured implants, but in this case, the immediate implant insertion was not attempted because of the potential risk for bacterial infection.

The length of healing time to achieve osseointegration has not been established for diabetic patients. Branemark et al<sup>24</sup> first suggested healing periods of 3 to 6 months for the mandible and maxilla, respectively. The implants installed in the mandible were exposed after 16 to 18 weeks by Kapur et al<sup>7</sup> and 2.6 to 22.0 months (mean 4.8 months) by Olson et al.<sup>10</sup> Mericske-

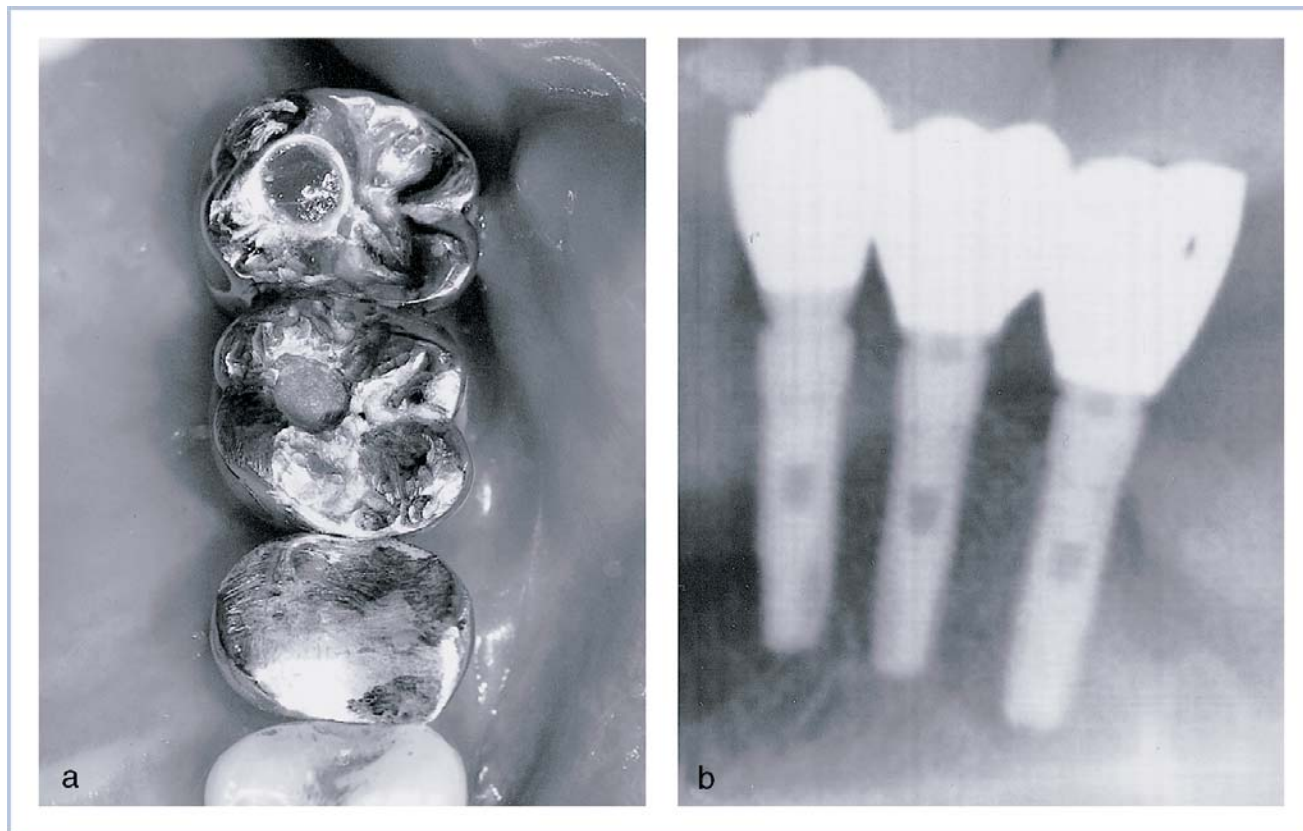


FIGURE 5. (a) Prosthesis in function after 6 months for upper right 2nd premolar and after 9 months for upper right 1st and 2nd molar. (b) Radiograph showing no specific bone loss around implant.

Stern and Zarb<sup>9</sup> used one-stage implants, and the new dentures were connected to the implants in the lower arch after a healing period of 3 to 4 months.

The author wanted to allow sufficient healing time for the bone before inserting the implants in this case. The healing times following tooth extractions and removal of the failed implant were 2 months and 6 months respectively. The prostheses were delivered after 4 to 8 months. The histologic findings revealed that remodeling and maturation were achieved after 6 months of healing in the diabetic patient. The prosthetic loading could be done within 4 months in the upper molar area even though there were some complications during the healing period. Further clinical trials are needed to establish appropriated healing times for various anatomic locations in diabetic patients.

#### SUMMARY

This case report demonstrates that an implant can be placed in a failed site for a type II diabetic patient after a prolonged period of bone healing. Bone remodeling and maturation were achieved after 6 months of healing in the failed implant site and the prostheses

could be delivered within 4 months in the upper arch despite some complications during the healing period.

#### REFERENCES

1. King H, Aubert RE, Herman WH. Global burden of diabetes, 1995–2025: prevalence, numerical estimates, and projections. *Diabetes Care*. 1998;21:1414–1431.
2. Kim SM, Lee JS, Lee J, et al. Prevalence of diabetes and impaired fasting glucose in Korea. *Diabetes Care*. 2006;29:226–231.
3. Goodman WG, Hori MT. Diminished bone formation in experimental diabetes. Relationship to osteoid maturation and mineralization. *Diabetes*. 1984;33:825–831.
4. Iyama S, Takeshita F, Ayukawa Y, et al. A study of the regional distribution of bone formed around hydroxyapatite implants in the tibiae of streptozotocin-induced diabetic rats using multiple fluorescent labeling and confocal laser scanning microscopy. *J Periodontol*. 1997;68:1169–1175.
5. Ottoni CE, Chopard RP. Histomorphometric evaluation of new bone formation in diabetic rats submitted to insertion of temporary implants. *Braz Dent J*. 2004;15:87–92.
6. Shernoff AF, Colwell JA, Gingham SF. Implants for type II diabetic patients: interim report. VA implants in Diabetes Study Group. *Implant Dent*. 1994;3:183–185.
7. Kapur K, Garrett NR, Hamada MO, et al. A randomized clinical trial comparing the efficacy of mandibular implant-supported overdentures and conventional dentures in diabetic

patients. Part I: methodology and clinical outcomes. *J Prosthet Dent.* 1998;79:555–569.

8. Smith RA, Berger R, Dodson TB. Risk factors associated with dental implants in healthy and medically compromised patients. *Int J Oral Maxillofac Implants.* 1992;7:367–372.

9. Mericske-Stern R, Zarb GA. Overdentures: an alternative implant methodology for edentulous patients. *Int J Prosthodont.* 1993;6:203–208.

10. Olson JW, Shernoff AF, Tarlow JL, et al. Dental endosseous implant assessments in type 2 diabetic population: a prospective study. *Int J Oral Maxillofac Implants.* 2000;15:811–818.

11. Morris HF, Ochi S, Winkler S. Implant survival in patients with type 2 diabetes: placement to 36 months. *Ann Periodontol.* 2000;5:157–165.

12. Tonetti M, Schmidt J. Pathogenesis of implant failure. *Periodontol 2000.* 1994;4:127–138.

13. Isidor F. Loss of osseointegration caused by occlusal load of oral implants. A clinical and radiological study in monkeys. *Clin Oral Implants Res.* 1996;7:143–152.

14. Dajani AS, Taubert KA, Wilson W, et al. Prevention of bacterial endocarditis: recommendations by the American Heart Association. *J Am Dent Assoc.* 1997;128:1142–1151.

15. Anonymous. Standards of medical care in diabetes 2006. *Diabetes Care.* 2006;29 (Suppl):S4–S42.

16. Goodson WH, Hunt TK. Wound healing and the diabetic patient. *Surg Gyn Obstet.* 1979;149:600–608.

17. McMurry JF. Wound healing with diabetes mellitus. *Surg Clin North Am.* 1984;64:769–778.

18. Sbordone L, Barone A, Ramaglia L, et al. Antimicrobial susceptibility of periodontopathic bacteria associated with failing implants *J Periodontol.* 1995;66:69–74.

19. Peterson LJ. Antibiotic prophylaxis against wound infections in oral and maxillofacial surgery. *J Oral Maxillofac Surg.* 1990; 48:617–620.

20. Dent CD, Olson JW, Farish SE, et al. The influence of preoperative antibiotics on success of endosseous implants up to and including stage II surgery. A study of 2,641 implants. *J Oral Maxillofac Surg.* 1997;55 (Suppl 5):19–24.

21. Ottoni JM, Oliveira ZF, Mansini R, et al. Correlation between placement torque and survival of single-tooth implants. *Int J Oral Maxillofac Implants.* 2005;20:769–776.

22. Barboza EP, Caula AL. Diagnoses, clinical classification, and proposed treatment of spontaneous early exposure of submerged implants. *Implant Dent.* 2002;11:331–337.

23. Covani U, Barone A, Cornelini R, Crespi R. Clinical outcome of implants placed immediately after implant removal. *J Periodontol.* 2006;77:722–727.

24. Branemark PI, Adell R, Breinie U, et al. Intra-osseous anchorage of dental prostheses. I. Experimental studies. *Scan J Plast Reconstr Surg.* 1969;3:81–100.