

# Optimal Puncture Site of the Right Internal Jugular Vein after Laryngeal Mask Airway Placement

Kazuhide Takeyama, M.D.,\* Hiroyuki Kobayashi, M.D., Ph.D., M.S.,† Toshiyasu Suzuki, M.D., Ph.D.‡

**Background:** Puncturing of the internal jugular vein (IJV) after placement of a laryngeal mask airway (LMA) is difficult. Overlapping of the right internal jugular vein (IJV) and common carotid artery (CCA) after placement of an *LMA-Classic*<sup>TM</sup> (Laryngeal Mask Company, Henley-on-Thames, United Kingdom) was investigated using an ultrasound scanner. A study was conducted to determine the optimal puncture site in the case of puncturing the right IJV after *LMA-Classic*<sup>TM</sup> placement.

**Methods:** The subjects in this study consisted of 114 patients (60 men and 54 women) scheduled to undergo *LMA-Classic*<sup>TM</sup> placement (size 4 for men and size 3 for women). Overlapping between the IJV and CCA was investigated at three points (high, middle, and low points) on the right side of the neck after *LMA-Classic*<sup>TM</sup> placement. A test puncture was also made at the right low (supraclavicular) point after *LMA-Classic*<sup>TM</sup> placement.

**Results:** (1) The degree of overlapping of the right IJV and CCA after *LMA-Classic*<sup>TM</sup> placement was clearly greater than before LMA placement. (2) With the exception of some measurements, there were many cases in which the right IJV and CCA were completely overlapping after *LMA-Classic*<sup>TM</sup> placement. Furthermore, the CCA was not observed in the vicinity of the right IJV at the right low point. (3) There were no complications (including pneumothorax and accidental arterial puncture) during supraclavicular IJV puncture after *LMA-Classic*<sup>TM</sup> placement.

**Conclusion:** After placement of the *LMA-Classic*<sup>TM</sup>, overlapping of the IJV and CCA increased at the high and middle puncture points of the IJV; however, at the lower puncture point, the position of the vessels remained unaffected. Therefore, during IJV puncture at high or middle points, ultrasound guidance is advisable to avoid CCA puncture.

THE internal jugular vein (IJV) is frequently used as a central venous route because of its ease of puncturing. However, puncture failure rates of 4–33% are observed in puncturing using anatomical indices (junction of the sternocleidomastoid muscle). Moreover, the incidence of complications accompanying puncture (accidental puncture of the carotid artery, hematoma of the neck and mediastinum, pneumothorax, brachial nerve damage, and so on) is observed to be 5–10%.<sup>1</sup> These are caused by the locations of vessels being different from indices and by the presence of abnormal vessels. Recently, IJV puncture has been able to be performed more accurately, safely, and rapidly by puncturing after first

confirming the location of the IJV using an ultrasound scanner.<sup>2–7</sup> However, IJV puncture is considered to be difficult after placement of a laryngeal mask airway (LMA). The reason for this is the difficulty in palpating the pulse of the common carotid artery (CCA) and displacement of the sternocleidomastoid muscle.<sup>8</sup>

The positional relation between the right IJV and CCA after placement of the *LMA-Classic*<sup>TM</sup> (Laryngeal Mask Company, Henley-on-Thames, United Kingdom) was investigated using an ultrasound scanner. A study was conducted to determine the optimal puncture site in the case of puncturing the right IJV after *LMA-Classic*<sup>TM</sup> placement.

## Materials and Methods

The subjects of this study consisted of 114 patients (American Society of Anesthesiologists physical status I or II; 60 men and 54 women) scheduled to undergo insertion of the *LMA-Classic*<sup>TM</sup>. The reasons for selecting 114 patients are described below. Sample size was estimated by using nQuery Advisor (version 5.0; Statistical Solutions Ltd., Cork, Ireland). A sample size of 52 in each group had an 80% likelihood of detecting at a probability of 0.660 that the overlap index in patients with a size 4 mask would be less than the overlap index in patients with a size 3 mask using the Wilcoxon (Mann-Whitney) rank sum test with a two-sided level of significance of 0.050. In anticipation of ineligible cases, a total of 114 patients were recruited.

Those procedures targeted for the use of LMA included surgery on the four extremities (upper and lower extremities), transurethral prostatectomy, debridement procedures after burns, and body surface procedures (mastectomy, repaired inguinal hernia). This study was conducted after ethical approval was obtained from the institutional review board of the Tokai University School of Medicine (Isehara, Kanagawa, Japan). On the basis of this, the patients were provided with an explanation of the purpose of this study before undergoing the procedure, and their consent was obtained.

The patients' background information consisted of age (men: 52 ± 11 yr; women: 48 ± 12 yr), height (men: 168 ± 9 cm; women: 156 ± 8 cm), and weight (men: 66 ± 9 kg; women: 55 ± 8 kg). The *LMA-Classic*<sup>TM</sup> was used for the LMA. The reason for using the *LMA-Classic*<sup>TM</sup> is the absence of a cuff on the back of the mask. The absence of a cuff on the back of the mask means that there is little effect on surrounding tissue when the cuff is inflated. Placement of a size 5 *LMA-Classic*<sup>TM</sup> was attempted for the male patients on the base of sex criteria.<sup>9–11</sup> However, because the *LMA-Classic*<sup>TM</sup> was

\* Instructor, ‡ Professor, Department of Anesthesiology, † Director, General Clinical Research Center, Tokai University School of Medicine.

Received from the Department of Anesthesiology and General Clinical Research Center, Tokai University School of Medicine, Isehara City, Kanagawa, Japan. Submitted for publication April 12, 2005. Accepted for publication August 8, 2005. Support was provided solely from institutional and/or departmental sources.

Address reprint requests to Dr. Takeyama: Department of Anesthesiology, Tokai University School of Medicine, Isehara City, Kanagawa, Japan. Address electronic mail to: takeyama@is.icc.u-tokai.ac.jp. Individual article reprints may be purchased through the Journal Web site, www.anesthesiology.org.

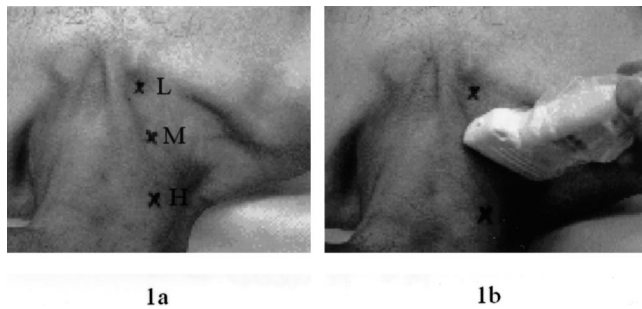


Fig. 1. (A) Three measurement points are shown: H = high point; L = low point; M = middle point. (B) Probe scanning on the right side of the neck. The probe was positioned at the middle point in short axis scanning.

unable to be properly placed in some of the patients, we decided to use a size 4 LMA for men and a size 3 LMA for women. An ultrasound scanner (EUB6500, linear type, 13-MHz probe; Hitachi, Tokyo, Japan) was used. The measurement sites consisted of three points on the right side of the neck (high point: at the midpoint of the mastoid process and ramus clavicularis of the sternocleidomastoid muscle attach to the clavicle; middle point: at the intersection of the clavicular head and sternal head of the sternocleidomastoid muscle; low point: near the area where the ramus clavicularis of the sternocleidomastoid muscle attaches to the clavicle). The reason for selecting these three points is that they are all used as central venous puncture sites<sup>12-14</sup> (fig. 1A). The positional relation of the IJV and CCA was measured before and after *LMA-Classic*<sup>TM</sup> placement. The measuring procedure is described as follows. Before *LMA-Classic*<sup>TM</sup> placement, each patient was placed on a horizontal bed, and the patient's head was rotated 30° to the left from midline. The reason for rotating the head 30° to the left is that, if the head is positioned at the midline, a portion of the probe contacts the clavicle, thereby preventing the probe from effectively pushing against the measurement site. Marks were respectively made at three measurement points with the neck rotated 30° to the left. The probe was gently pressed against the neck so that the center of the probe was positioned at the measurement point in short axis scanning (fig. 1B). After obtaining echo images by scanning two adjacent images, the neck was compressed with the probe. The echo image, which was easily deformed by compression, was recognized to be the IJV, whereas other image that pulsed consistent with pulse was recognized to be the CCA. After confirming the locations of the IJV and CCA, their positional relation was recorded in color images (displaying the IJV in blue and CCA in red) and black-and-white images. Furthermore, because the CCA was unable to be confirmed in all patients at the low point, only images of the IJV were recorded. The patients were then anesthetized by intravenous injection of propofol at 2.5 mg/kg.

A gastric tube was inserted before *LMA-Classic*<sup>TM</sup> placement to remove gastric juices. The *LMA-Classic*<sup>TM</sup>

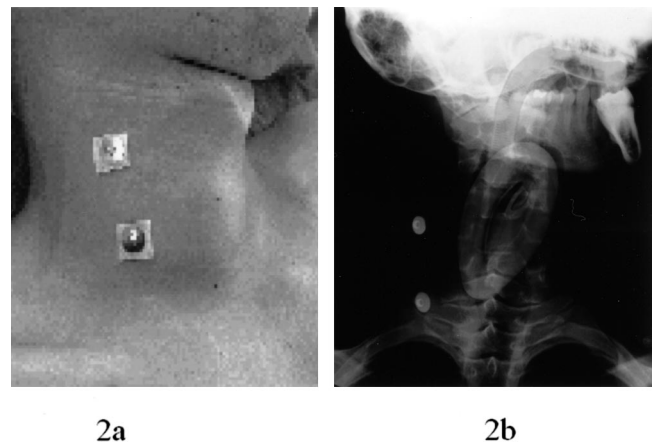


Fig. 2. (A) Placement of *LMA-Classic*<sup>TM</sup> (size 4) with electrocardiograph electrodes attached at the high point and middle point. (B) Simple x-ray film of the neck taken with the head rotated 30° to the left after placement of *LMA-Classic*<sup>TM</sup> (size 4). Electrocardiograph electrodes can be seen at the high and middle points. The electrode at the high point nearly coincides with the wide portion of the cuff, whereas the electrode at the middle point nearly coincides with the height of the end of the cuff.

was placed after removing the gastric tube. Air was injected into the cuff, and after confirming adequate ventilation, anesthesia was started under spontaneous respiration. Next, the sites of the cuff that coincided with the measurement points (middle and high points) were confirmed. The electrodes of an electrocardiograph were attached to the middle and high points of a certain male patient and used as marks. After placing the *LMA-Classic*<sup>TM</sup>, simple x-ray images of the neck were taken, with the head rotated 30° to the left (fig. 2A). Subsequently, the positional relation between the IJV and CCA was measured after *LMA-Classic*<sup>TM</sup> placement. This measurement was performed using the same procedure as that before *LMA-Classic*<sup>TM</sup> placement. Because nitrous oxide was used, a cuff pressure gauge (Tyco Healthcare Japan, Ltd., Japan) was used during anesthesia. The air injection rate was adjusted to be nearly constant (15 ml for size 3 or 20 ml for size 4) within a range in which the cuff internal pressure was maintained no higher than 60 cm H<sub>2</sub>O.<sup>15</sup> The percent overlap of the IJV and CCA was calculated from the recorded images. Calculation of this ratio was determined as the ratio of the overlapping length of the IJV to the horizontal diameter of the CCA. This ratio was referred to as the overlap index. The calculation formula is as follows: Overlap index = [overlap (mm)/CCA diameter (mm)] × 100.<sup>16</sup>

A comparative study was made of this overlap index by measuring the overlap index (1) before *LMA-Classic*<sup>TM</sup> placement, (2) before and after *LMA-Classic*<sup>TM</sup> placement, (3) for different sizes (sizes 3 and 4), and (4) for different measurement points (middle and high points in the same patient). Because the frequency distribution of the overlap indices was not normally distributed, non-parametric tests were used. The data were expressed as the median and its 95% confidence interval and inter-

quartile range. The significance of differences in median values between patients with a size 3 mask and those with a size 4 mask was assessed by using the Wilcoxon rank sum test. Differences in overlap indices at different puncture sites within the same patient were analyzed by the Wilcoxon signed-rank test. Data were analyzed with SPSS for Windows (version 13.0; SPSS Inc., Chicago, IL) and Confidence Interval Analysis for Windows (version 2.1.1; BMJ Books, London, United Kingdom).

Moreover,<sup>5</sup> test punctures were performed of the IJV at the right low point after *LMA-Classic*<sup>TM</sup> placement. The test punctures were performed in 20 patients. This is because 10 patients each using size 3 and size 4, respectively, were selected. Test punctures were performed according to the following procedure. The patient head was rotated 30° to left from midline after *LMA-Classic*<sup>TM</sup> placement. A disposable syringe equipped with a 23-gauge needle (volume, 2.5 ml) was used for the syringe. After confirming the location of the IJV with the ultrasound scanner, the needle was slowly advanced from the low point toward the clavicle while negative pressure was applied.

Test puncturing was considered to be successful when backflow of venous blood was confirmed. After test puncturing, fluctuations in values of oxygen saturation measured by pulse oximetry and changes in breathing sounds in the right lung were carefully monitored at all times in consideration of the potential for the occurrence of pneumothorax.

## Results

### Patient Background

There were no significant differences observed between men and women (data not shown).

### Neck X-ray Findings

Simple x-ray images of the neck showed that the electrocardiograph electrodes attached at the middle point coincided with the front edge of the cuff, whereas the electrocardiograph electrodes attached at the high point coincided with the wide portion of the cuff (fig. 2B).

### Specific Example of Positional Relation between Right IJV and CCA

The following describes a specific example of the positional relation between the right IJV and CCA (fig. 3). In figure 3, there is hardly any overlapping of the right IJV and CCA at the middle and high points before *LMA-Classic*<sup>TM</sup> placement. After *LMA-Classic*<sup>TM</sup> placement, however, the right IJV and CCA completely overlapped at the middle and high points. In this example, the cuff was shown to be in contact with the right CCA at the middle and high points after *LMA-Classic*<sup>TM</sup> placement.

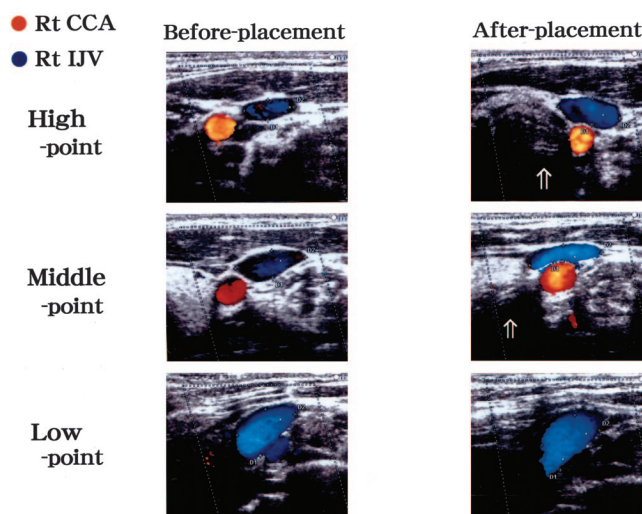
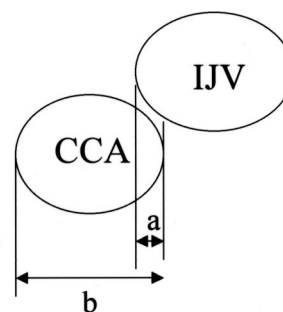


Fig. 3. A specific example of the positional relation between the right internal jugular vein (IJV) and common carotid artery (CCA) is shown. Before laryngeal mask airway placement: IJV and CCA did not overlap at the high point and partially overlapped at the middle point. After laryngeal mask airway placement: IJV and CCA completely overlapped at the high and middle points. The cuff (arrow) seemed to be contacting the right CCA at the high and middle points. At the low point, CCA was not observed in the vicinity of the IJV regardless of laryngeal mask airway insertion.

Furthermore, the CCA was not clearly observed in the vicinity of the IJV regardless of *LMA-Classic*<sup>TM</sup> placement at the right low point. In addition, the cuff was not observed in the vicinity of the IJV even after *LMA-Classic*<sup>TM</sup> placement.

### Measurement of Overlap Index between Right IJV and CCA

Before *LMA-Classic*<sup>TM</sup> placement, the overlap index (fig. 4) at the middle point was not statistically different between men and women (median, 13 vs. 0;  $P = 0.144$ ) based on the Wilcoxon rank sum test. The overlap index at the high point was also not statistically different between men and women (median, 0 vs. 0;  $P = 0.388$ ) based on the Wilcoxon rank sum test (table 1).



$$\text{Overlap index} = a/b \times 100$$

Fig. 4. Overlap index is indicated. Overlap index = [overlap (mm)/CCA diameter (mm)]  $\times$  100. a = overlap of common carotid artery (CCA) and internal jugular vein (IJV) (mm); b = CCA diameter (mm).

**Table 1. Comparison of Overlap Indexes between Men and Women before Laryngeal Mask Airway Placement**

	Women (n = 54)	Men (n = 60)	P Value
Middle	0 (0–20) [0–38]	13 (0–25) [0–50]	0.144
High	0 (0–13) [0–14]	0 (0–9) [0–13]	0.338

Values are presented as median (95% confidence interval) [interquartile range]. P values were assessed by Wilcoxon rank sum test.

Differences in the overlap indices before and after *LMA-Classic™* placement within the same patient were analyzed by the Wilcoxon signed-rank test. There was a significant increase in the overlap index within the same patient from baseline (before *LMA-Classic™* placement) to the overlap index after *LMA-Classic™* placement with an average change of 41.8 ( $P < 0.001$ ; 95% confidence interval, 33.6–50.0) at the middle point and with an average change of 40.9 ( $P < 0.001$ ; 95% confidence interval, 33.5–48.3) at the high point.

After *LMA-Classic™* placement, the overlap index at the high point was higher in patients with a size 3 mask (n = 54) as compared with those with a size 4 mask (n = 60) (median, 90 vs. 27;  $P = 0.001$ ) based on the Wilcoxon rank sum test (table 2). At the middle point, however, the overlap index was not statistically different between patients with a size 3 mask and those with a size 4 mask (median, 100 vs. 79;  $P = 0.129$ ) based on the Wilcoxon rank sum test.

There was a significant decrease in overlap indices from the middle point to the high point within the same patient using a size 4 mask, with an average change of 18.2 ( $P = 0.002$ ; 95% confidence interval, 6.6–29.9) based on the Wilcoxon signed-rank test. Within the same patient using a size 3 mask, however, there were no significant differences in overlap indices from the middle point to the high point ( $P = 0.348$ ) based on the Wilcoxon signed-rank test.

Backflow of venous blood was confirmed in all 20 patients during IJV puncturing at the right low point after *LMA-Classic™* placement. Complications accompanying puncture (accidental puncturing of the CCA and pneumothorax) were not observed.

## Discussion

The purpose of this study was to determine which site of a central vein facilitates central venous puncturing in the

**Table 2. Comparison of Overlap Indexes between Two Groups with Different Mask Sizes**

	Mask Size 3 (n = 54)	Mask Size 4 (n = 60)	P Value
Middle	100 (63–100) [36–100]	79 (27–100) [17–100]	0.129
High	90 (67–100) [29–100]	27 (0–71) [0–91]	0.001

Values are presented as median (95% confidence interval) [interquartile range]. P values were assessed by Wilcoxon rank sum test.

case that unexpected bleeding has occurred during anesthesia management after *LMA-Classic™* placement. The procedures examined in this study were comparatively minor procedures. There is predicted to be little bleeding during these procedures. Consequently, they do not usually require a central venous route (insertion from the femoral vein or subclavian vein) before surgery.

In the case that a central venous route has been judged to be required, there is also a method in which a central venous route is secured after reintubating the airway. In this case, however, a certain amount of time is required until intubation of the airway after removing the *LMA-Classic™*. The optimal puncture site for central venous puncturing after *LMA-Classic™* placement was examined as one way of being able to access a central vein directly.

Riley *et al.*<sup>8</sup> recommended puncturing the IJV after first deflating the cuff as a method of facilitating IJV puncture after *LMA™* placement. The reason for this is that the pulsation of the CCA becomes easier to palpate by deflating the cuff, thereby making it easier to puncture the IJV. However, deflating the cuff results in less adhesion with the airway, leading to the risk of inadequate ventilation. Therefore, in this study, the positional relation between the IJV and CCA with the cuff still inflated was measured using an ultrasound scanner.

The air injected into the cuff was injected at nearly a constant rate regardless of size to minimize variations in the amount of injected air. The amounts of injected air were one half to one third the maximum injectable volume for both size 3 and size 4 masks. This injected amount was considered to be the optimal amount for relieving throat pain and preventing leakage of air from around the mask. There are few reports describing the positional relation between the IJV and CCA after *LMA™* placement. According to a report by Nandwani *et al.*<sup>17</sup> (in which only a size 3 *LMA™* was used in 18 female patients), although the larynx seemed to distend in an anterior direction after *LMA™* placement, there was no overlapping of the IJV and CCA.

### *Comparison between Our Study and the Study of Nandwani et al.*<sup>17</sup>

In our study, the positional relation between the right IJV and CCA was measured at multiple measurement points using two sizes of masks. The overlap indices clearly increased after *LMA-Classic™* placement as compared with before *LMA-Classic™* placement for both mask sizes and at each measurement point.

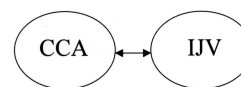
These results differ from the report by Nandwani *et al.*<sup>17</sup> One possible cause of this discrepancy may be the rotation angle of the patients' heads. In our study, the positional relation between the IJV and CCA was measured with the patient's head rotated 30° to the left, whereas in

the study by Nandwani *et al.*, each patient's head was in the neutral position. In the specific example shown in figure 3, the positional relation of the vascular system was measured with the patient's head rotated 30° to the left. In figure 3, the cuff was shown to be in contact with the right CCA at the middle and high points after *LMA-Classic*<sup>TM</sup> placement. A possible cause of the overlapping on the basis of figure 3 is that, as a result of rotating the head after *LMA-Classic*<sup>TM</sup> placement, the CCA became susceptible to extrinsic compression from the inflated cuff, thereby making it easier to move toward the dorsal side of the IJV.

We normally perform IJV puncture with the head rotated in the opposite direction from the puncture side,<sup>12</sup> as was done in this study. In this study, an angle of 30° was used for the angle of rotation of the head. This is because the IJV and CCA become increasingly likely to overlap at rotation angles in excess of 30°. This in turn leads to an increased risk of accidentally puncturing the CCA.<sup>16,18</sup>

The positioning of the head in the neutral position has been recommended for the angle of the head during IJV puncture.<sup>19,20</sup> Troianos *et al.*<sup>20</sup> measured the positional relation between the IJV and CCA using magnetic resonance imaging. They reported that rotating the head to the left resulted in greater overlapping of the IJV and CCA as compared with positioning the head in the neutral position. They therefore reported that the head should be in neutral position during IJV puncture.

In our study, however, the head was not in the neutral position. This is because, if the head was in the neutral position, we were unable to depict the positional relation between the IJV and CCA effectively. If the head is in the neutral position, a portion of the probe contacts the clavicle, thereby preventing the measuring surface of the probe from properly contacting the measurement point. This phenomenon was observed during measurement at the middle and low points. At the high point, the probe was barely able to make proper contact with the measurement point. As a result, the IJV and CCA tended to exhibit partial overlapping at the high point even if the head was in the neutral position. According to the report by Troianos *et al.*,<sup>20</sup> there seem to be hardly any overlapping of the IJV and CCA on magnetic resonance imaging if the head is in the neutral position. However, the positional relation between the IJV and CCA is believed to change as a result of *LMA-Classic*<sup>TM</sup> placement. It is predicted that the IJV and CCA will at least partially overlap even if the head is in the neutral position after *LMA-Classic*<sup>TM</sup> placement. Consequently, even if the head is in the neutral position, it is necessary to use an ultrasound scanner during IJV puncture. In the future, we intend to conduct a more detailed study of overlapping of the IJV and CCA when the head is in the neutral position.



←→: Distance of between CCA and IJV

Fig. 5. Arrow indicates distance between common carotid artery (CCA) and internal jugular vein (IJV).

#### Comparison of Overlap Indices for Different Mask Sizes and Different Measurement Points within the Same Patient

In the case of measuring overlap indices at the high point after placement of a size 4 *LMA-Classic*<sup>TM</sup>, the resulting overlap indices were lower as compared with other conditions. These results were different from what we expected. Before this study, we expected that the overlap indices between the IJV and CCA would be higher for the high point than the middle point. The reason for this is that the high point nearly coincided with the height of the wide portion of the cuff as shown in figure 2B. That is, the effects of the cuff were thought to be greater at the high point than at the middle point, thereby resulting in a greater likelihood of overlapping of the right IJV and CCA at the high point.

However, the results were the opposite of what we expected. To examine the cause of this, we measured the distance between the IJV and CCA at the high point and middle point before placement of the size 4 *LMA-Classic*<sup>TM</sup>. As a result, the distance between the IJV and CCA (fig. 5) was  $1.9 \pm 1.4$  mm at the high point and an average of  $0.9 \pm 0.7$  mm at the middle point. Therefore, the arteriovenous distance was significantly greater at the high point than at the middle point ( $P < 0.01$ , Mann-Whitney U test). Although this is a hypothesis, it is possible that the likelihood of overlapping decreased even if the CCA was displaced to the dorsal side of the IJV after placing the *LMA-Classic*<sup>TM</sup> because they are farther apart at the high position. However, in this case as well, the overlap indices between the IJV and CCA increased as compared with before *LMA-Classic*<sup>TM</sup> placement. Therefore, confirmation with an ultrasound scanner is required in the case of IJV puncture.

In the future, we hope to conduct a study involving actual IJV puncturing at middle and high points after *LMA*<sup>TM</sup> placement using an ultrasound scanner for the purpose of assessing the resulting puncture success rates.

#### Supraclavicular Puncture

In the right supraclavicular region, the CCA was not definitively observed in the vicinity of the IJV regardless of *LMA-Classic*<sup>TM</sup> placement. The IJV at this site was seen to be in contact with the subclavian vein, and the diameter of the IJV gave the impression of being larger than at the high and middle points. Anatomically, the IJV merges with the subclavian vein at the posterior surface

of the sternoclavicular joint, and an enlarged portion is formed directly above the merge.<sup>21</sup> At the low point, the enlarged portion of the IJV may have been visible.

There are hardly any obstructions present at the low point during IJV puncturing. It was therefore desired to confirm whether IJV puncturing is possible under these conditions. A trial puncture was therefore conducted only at the low point. IJV puncturing was able to be performed in all patients without any accidental puncturing of the CCA or cuff. However, backflow of venous blood was ultimately observed after several attempts at puncturing in several of the patients. One possible factor for the difficulty encountered during puncturing was the small amount of increase in the vessel diameter. Parry<sup>22</sup> reported that the size of the vessel diameter is involved in the success rate of IJV puncture. There have been sporadic reports indicating that the Valsalva method demonstrates efficacy in enlarging the IJV.<sup>23,24</sup> It may be necessary to use the Valsalva method in cases which IJV puncture initially seems unlikely to proceed favorably.

Fortunately, in this study, there were no patients in which pneumothorax occurred. However, during trial puncturing in the supraclavicular region, it is necessary to confirm the location of the pleura using an ultrasound scanner. The location of the pleura was not confirmed before trial puncturing in this study. This is one aspect of the study that should be reconsidered. The *LMA-Classic™* was only type of LMA used in this study.

A recently available disposable-type LMA (*LMA-Unique™*) is reported to be associated with a lower increase in mask internal pressure when nitrous oxide is used, as compared with the *LMA-Classic™*.<sup>25</sup> We would like to conduct a comparative study using different types of LMA in the future. In addition, the sizes of the *LMA-Classic™* used in this study consisted of size 4 for men and size 3 for women.

There have been reports indicating that a size 4 rather than a size 3 is more suitable for women, whereas a size 5 rather than a size 4 is suitable for men.<sup>26</sup> It has also been reported that selecting mask size based on sex rather than based on body weight resulted in lower rates of gas leakage from around the mask.<sup>27</sup> We also intend to conduct studies using more suitable mask sizes in the future.

Puncturing at the high and middle points should be attempted when performing IJV puncturing after *LMA-Classic™* placement if an ultrasound scanner is able to be used. However, in cases in which the IJV and CCA overlap completely and there is a high risk of accidentally puncturing the CCA, it may be worthwhile to attempt puncturing at the low point.

In conclusion, although overlapping of the IJV and CCA increases at high and middle IJV puncturing sites after *LMA-Classic™* placement, puncturing at a low point does not have an effect on the positional relation of the two vessels. Therefore, when performing IJV puncturing at a high point or a middle point, it is pref-

erable to avoid accidentally puncturing the CCA with use of guidance by an ultrasound scanner.

The authors thank Masanobu Yoshikawa, Ph.D. (Assistant, Department of Pharmacology, Tokai University School of Medicine, Isehara City, Kanagawa, Japan), Atsusi Hashimoto, M.D., Ph.D. (Instructor, Department of Pharmacology, Tokai University School of Medicine), and Hitachi Medical Corporation (Tokyo, Japan) for their cooperation in compiling and supporting this report.

## References

- Skolnick ML: The role of sonography in the placement and management of jugular and subclavian central venous catheters. *Am J Roentgenol* 1994; 163:291-5
- Gordon AC, Saliken JC, Johns D, Owen R, Gray RR: US-guided puncture of the internal jugular vein: Complications and anatomic considerations. *J Vasc Interv Radiol* 1998; 9:333-8
- Caridi JG, Hawkins IF Jr, Wiechmann BN, Pevarski DJ, Tonkin JC: Sonographic guidance when using the right internal jugular vein for central vein access. *Am J Roentgenol* 1998; 171:1259-63
- Docktor B, So CB, Saliken JC, Gray RR: Ultrasound monitoring in cannulation of the internal jugular vein: Anatomic and technical considerations. *Can Assoc Radiol J* 1996; 47:195-201
- Koski EMJ, Suhonen M, Mattila MAK: Ultrasound-facilitated central venous cannulation. *Crit Care Med* 1992; 20:424-6
- Keenan SP: Use of ultrasound to place central lines. *J Crit Care* 2002; 17:126-37
- Teichgraber UKM, Benter T, Gebel M, Manns MP: A sonographically guided technique for central venous access. *Am J Roentgenol* 1997; 169:731-3
- Riley RH, Gaylard DG, Wright DA, Davies PC: The LMA and difficulty with internal jugular vein cannulation (letter). *Anaesthesia* 1999; 54:1224
- Berry AM, Brimacombe JR, McManus KF, Goldblatt M: An evaluation of the factors influencing selection of the optimal size of laryngeal mask airway in normal adults. *Anaesthesia* 1998; 53:565-70
- Asai T, Howell TK, Koga K, Morris S: Appropriate size and inflation of the laryngeal mask airway. *Br J Anaesth* 1998; 80:470-4
- Voyagis GS, Batzioulis PG, Secha-Doussaitou PN: Selection of the proper size of laryngeal mask airway in adults. *Anesth Analg* 1996; 83:663-4
- Perrino AC Jr, Feldman J, Barash PG: Noninvasive cardiovascular monitoring. *Monitoring in Anesthesia*, 3rd edition. Edited by Saidman, LJ Smith NT. San Diego, Butterworth-Heinemann, 1993, pp 64
- Otto CW: Central venous pressure monitoring. *Monitoring in Anesthesia and Critical Care Medicine*, 2nd edition. Edited by Blitt CD. New York, Churchill-Livingstone, 1991, p 199
- English ICW, Frew RM, Pigott JF, Zaki M: Percutaneous catheterisation of the internal jugular vein. *Anaesthesia* 1969; 24:521-31
- Brimacombe J, Berry A, Brain AJ: Optimal infracuff pressures with the laryngeal mask. *Br J Anaesth* 1996; 77:295-6
- Sulek CA, Gravenstein N, Blackshear RH, Weiss L: Head rotation during internal jugular vein cannulation and the risk of carotid artery puncture. *Anesth Analg* 1996; 82:125-8
- Nandwani N, Fairfield MC, Krarup K, Thompson J: The effect of laryngeal mask airway insertion on the position of the internal jugular vein. *Anaesthesia* 1997; 52:77-83
- Lieberman JA, Williams KA, Rosenberg AL: Optimal head rotation for internal jugular vein cannulation when relying on external landmarks. *Anesth Analg* 2004; 99:982-8
- Willeford KL, Reitan JA: Neutral head position for placement of internal jugular vein catheters. *Anaesthesia* 1994; 49:202-4
- Troianos CA, Kuwik RJ, Pasqual JR, Lim AJ, Odasso DP: Internal jugular vein and carotid artery anatomic relation as determined by ultrasonography. *ANESTHESIOLOGY* 1996; 85:43-8
- Paradis NA, Martin GB, Goetting MG, Rosenberg JM, Rivers EP, Appleton TJ, Nowak RM: Simultaneous aortic, jugular bulb, and right atrial pressures during cardiopulmonary resuscitation in humans: Insights into mechanism. *Circulation* 1989; 80:361-8
- Parry G: Trendelenburg position, head elevation and a midline position optimize right internal jugular vein diameter. *Can J Anesth* 2004; 51:379-81
- Denys BG, Uretsky BF: Anatomical variations of internal jugular vein location: Impact on central venous access. *Crit Care Med* 1991; 19:1516-9
- Armstrong PJ, Sutherland R, Scott DHT: The effect of position and different manoeuvres on internal jugular vein diameter size. *Acta Anaesth Scand* 1994; 38:229-31
- Van Zundert AAJ, Fonck K, Al-Shaikh B, Mortier E: Comparison of the *LMA-Classic™* with the new disposable soft seal laryngeal mask in spontaneously breathing adult patients. *ANESTHESIOLOGY* 2003; 99:1066-71
- Asai T, Brimacombe J: Cuff volume and size selection with the laryngeal mask. *Anaesthesia* 2000; 55:1179-84
- Kihara S, Brimacombe JR, Yaguchi Y, Taguchi N, Watanabe S: A comparison of sex- and weight-based *Proseal™* laryngeal mask size selection criteria. *ANESTHESIOLOGY* 2004; 101:340-3