

## Case Scenario: Postoperative Liver Failure after Liver Resection in a Cirrhotic Patient

Catherine Paugam-Burtz, M.D., Ph.D.,\* Julia Wendon, M.B.Ch.B., F.R.C.P.,† Jacques Belghiti, M.D.,‡ Jean Mantz, M.D., Ph.D.§

**H**EPATIC resection for malignant liver tumors improves overall survival. However, liver surgery continues to be associated with significant morbidity and mortality.<sup>1</sup> A combination of careful patient selection, meticulous operative technique and specialized perioperative care is required to achieve low perioperative mortality (less than 5%) even in cases of hepatocellular carcinoma resections in cirrhotic patients.<sup>1</sup> Postoperative hepatic failure (POLF) is one of the most serious complications following liver surgery with a mortality that can exceed 70%.<sup>2</sup> The aim of this case scenario is to highlight the perioperative management of POLF after liver resection for hepatocellular carcinoma in patient with cirrhosis.

### Case Reports

A 51-yr-old man with hepatocellular carcinoma in the setting of hepatitis B cirrhosis was scheduled for a right hepatectomy. He had been diagnosed with chronic hepatitis B 6 yr ago and had no other significant medical conditions. A rise in

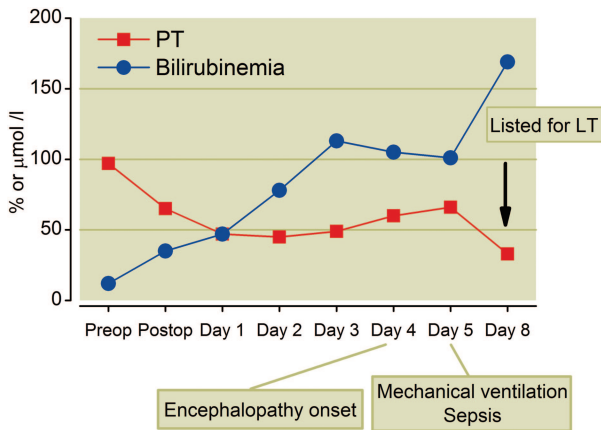
$\alpha$ -fetoprotein to 700 ng/ml led to the diagnosis of two hepatocellular carcinoma tumors in the right liver (60 mm in segment VII and 25 mm in segment IV and VIII) delineated on computed tomography (CT) scanning. Preoperative assessment did not show esophageal varices, portal hypertension, ascites, or evidence of portal vein thrombosis on abdominal CT-scan. Nontumor liver biopsy displayed macronodular cirrhosis. Bone scintigraphy and lung CT-scan did not show any evidence of metastasis. Preoperative liver and kidney functions were normal. There was no evidence of ongoing hepatitis B viral replication. An arterial chemoembolization of the segment IV artery was performed first, followed by a right venous portal embolization to induce hypertrophy of the left liver 1 month later.<sup>3</sup> Four weeks after embolization, a postprocedure liver CT-scan showed a 10% increase in the volume of the left liver, suggesting that the postoperative remaining liver volume would be approximately 40% of the original liver volume. A right hepatectomy (resection of hepatic segments V, VI, VII, and VIII) was performed 6 weeks after portal embolization. Anesthesia consisted of propofol, sufentanil, atracurium, and desflurane. Perioperative hemodynamic monitoring was performed with a radial artery catheter, a right internal jugular catheter and esophageal doppler. Intermittent portal clamping lasted 34 min. There were no intraoperative complications and no red cell transfusions were required. The patient was extubated in the operating theater and then transferred to the intensive care unit as part of standard postoperative care. The patient was alert and hemodynamically stable, without respiratory or renal failure. Postoperative analgesia was provided through patient-controlled analgesia with morphine. Acetaminophen was not given. Immediate postoperative data showed metabolic acidosis with hyperlactatemia (4 mM), which normalized after 12 h. Postoperatively, bilirubinemia increased steadily and prothrombin time (PT) remained low (vitamin K had been supplemented) (fig. 1). Daily hepatic echo-Doppler did not show any abnormalities of portal and suprahepatic vein flow, nor of hepatic artery flow. Because of persistent hyperbilirubinemia and a decreased PT, an abdominal CT scan was performed on post-

\* Professor, Department of Anesthesiology and Critical Care, AP-HP Beaujon Hospital, Clichy, France, and Univ Paris Diderot, Sorbonne Paris Cité, Paris, France, and INSERM U 773, Univ Paris Diderot, Sorbonne Paris Cité, Paris, France. † Professor, Institute of Liver Studies, Kings College London, Kings College Hospital, London, United Kingdom. ‡ Professor, Head of Department, Department of Hepato-Biliary and Liver Transplantation Surgery, Univ Paris Diderot, Sorbonne Paris Cité, Paris, France. § Professor, Head of Department, Department of Anesthesiology and Critical Care, AP-HP Beaujon Hospital, Clichy, France, and Univ Paris Diderot, Sorbonne Paris Cité, Paris, France.

Received from the Department of Anesthesiology and Critical Care, AP-HP Beaujon Hospital, Clichy, France, and Univ Paris Diderot, Sorbonne Paris Cité, Paris, France. Submitted for publication July 21, 2011. Accepted for publication December 1, 2011. Support was provided solely from institutional and/or departmental sources. Figures 2 and 3 were redrawn by Annemarie B. Johnson, C.M.I., Medical Illustrator, Wake Forest University School of Medicine Creative Communications, Wake Forest University Medical Center, Winston-Salem, North Carolina.

Address correspondence to Dr. Paugam-Burtz: Service d'anesthésie réanimation chirurgicale, Hôpital Beaujon, 100, Bd du Général Leclerc, 92110 Clichy, France. catherine.paugam@bjn.aphp.fr. This article may be accessed for personal use at no charge through the Journal Web site, [www.anesthesiology.org](http://www.anesthesiology.org).

Copyright © 2012, the American Society of Anesthesiologists, Inc. Lippincott Williams & Wilkins. Anesthesiology 2012; 116:705-11



**Fig. 1.** Postoperative course of serum bilirubinemia and prothrombin time. LT = liver transplantation;  $\mu\text{mol/l} = \mu\text{M}$ ; PT = prothrombin time; Preop = preoperative day; Postop = immediate postoperative.

operative day 3, which showed a partial thrombus of the remnant right portal vein. The CT scan did not reveal additional vascular abnormalities or any collections. Therapeutic anticoagulation with unfractionated heparin was initiated. There was no significant ascites and the abdominal drain was removed on postoperative day 4. On postoperative day 4, the patient became confused and somnolent. Electroencephalogram was consistent with a metabolic source of altered mental status, and hepatic encephalopathy was considered the most likely diagnosis. On postoperative day 5, the patient's mental status worsened (Glasgow coma score = 5) and he required tracheal intubation and mechanical ventilation. His worsening neurologic status was concomitant with fever ( $38^{\circ}\text{C}$ ) and an increase in leukocyte count to  $16.4 \text{ g/L}$ . There were no clinical signs of pulmonary, abdominal, or urinary infection. An extensive infectious workup (blood, urine, ascites, and blind protected pulmonary catheter cultures) was performed. Empiric antimicrobial therapy with piperacillin-tazobactam and ciprofloxacin was started. Hepatic and neurologic compromise was isolated without acute renal injury or significant hemodynamic instability. Arterial ammonia measurements were not available at the time.

On postoperative day 7, the patient was comatose and could not be weaned from the ventilator. PT was 26% with a corresponding International Normalized Ratio (INR) of 2 and a serum bilirubin of  $145 \mu\text{M}$ . Protected distal pulmonary sample cultures from postoperative day 5 yielded more than  $10^3$  *Klebsiella pneumoniae*, suggesting pneumonia. The patient was placed on appropriate antimicrobial therapy, and subsequently his leucocytosis improved and his fever resolved. Definitive histologic examination of the resected right liver showed macronodular cirrhosis with a low level of hepatitis activity and two well differentiated nodules of hepatocellular carcinoma (3 cm and 2.5 cm). The diagnosis of POLF secondary to a small functional liver remnant and possibly worsened by sepsis was considered. After a multidisciplinary meeting was held with liver transplant surgeons,

hepatologists, intensivists, and anesthesiologists, the patient was listed for liver transplantation and received a liver graft 9 days after the hepatectomy. Histologic analysis of the remnant left liver showed macronodular cirrhosis and multiple foci of parenchymal necrosis. There was no vascular thrombosis, no evidence of sinusoidal obstruction, and no inflammation. The patient's hospital course after the liver transplantation was complicated by severe sepsis secondary to bacterial peritonitis and concomitant bacteremia. The patient was extubated on postoperative day 12. He left the intensive care unit 15 days after his liver transplantation and 24 days after his hepatectomy.

## Discussion

### What Are the Clinical Symptoms of Postoperative Liver Failure?

The typical clinical features of POLF are worsening coagulopathy, hyperbilirubinemia, and encephalopathy, and can be associated with renal failure, respiratory compromise, and features of sepsis. This clinical presentation is similar to the presentation of acute liver failure, but more akin to that of subacute liver failure than to that of hyperacute liver failure.<sup>4</sup> Unlike acute liver failure, POLF is usually not associated with hepatic necrosis and transaminitis. The decrease in functional liver mass that occurs in POLF is mostly related to a large resection volume and not to necrosis and inflammation.

### Diagnostic Criteria and Epidemiology of Postoperative Liver Failure after Liver Resection

Serum bilirubin and clotting tests are well known measures of hepatic function. Changes in these parameters of hepatic function following liver surgery demonstrate that serum bilirubin and INR peak on postoperative day 2 and then normalize between postoperative days 5–7. These postoperative changes are influenced by the extent of resection, the subsequent inflammatory response, and the remnant liver's capacity for regeneration.<sup>5</sup> Consequently, serum bilirubin and INR are used in a majority of the proposed POLF scoring systems. However, there was no standardized definition of POLF until recently when the International Study Group of Liver Surgery has proposed a standardized definition of POLF and a system for grading severity of posthepatectomy liver failure.<sup>6</sup> They defined POLF as impairment in the liver's ability to maintain its synthetic, excretory, and detoxifying functions as characterized by an increased INR and hyperbilirubinemia on or after postoperative day 5. Figure 1 shows the time course for development of hyperbilirubinemia and coagulopathy in our patient and exemplifies the typical postoperative evolution of POLF. The group also proposed a system for classifying severity of POLF based on its impact on clinical management. Grade-A posthepatectomy liver failure requires no change in the patient's clinical management. Grade-B posthepatectomy liver failure requires changes in the patient's clinical management but no

invasive therapies. Grade-C posthepatectomy liver failure is defined by the need for invasive treatment.<sup>6</sup> Based on this classification, our patient developed grade-C POLF.

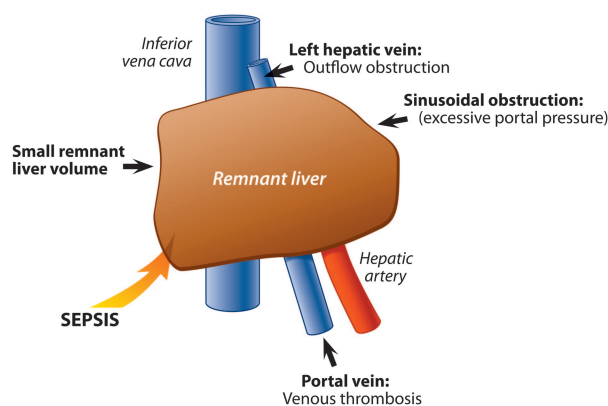
In addition to being used as diagnostic tools, postoperative bilirubinemia, and INR or PT have also been included in scores that are used as outcome predictors after hepatic resection. We have previously shown that PT less than 50% (INR more than 1.7) and bilirubinemia greater than 50  $\mu\text{M}$  are early predictors of mortality in the intensive care unit on both postoperative days 3 and 5, with positive likelihood ratios of 8.6 and 9.9, respectively.<sup>2</sup>

The incidence of POLF after a major hepatic resection ranges between 0–30% with a mean incidence of 5–8% following hepatic resection in patients with cirrhosis.<sup>1,7,8</sup> However, the lack of a standardized definition for POLF makes it difficult to compare the various reported values of incidence. Still, POLF is a major contributor to postoperative mortality and is implicated in 18–75% of postoperative deaths following major hepatic resections.<sup>2,9</sup>

#### What Are the Predictors and the Causes of Postoperative Acute Liver Failure after Liver Resection in Cirrhotic Patients?

Many predictors of POLF, such as, diabetes, liver fibrosis extent, small remnant liver volume, intraoperative blood loss, and need for blood transfusion have been described.<sup>10</sup> Diabetes is a common comorbidity in patients with liver resection. It is commonly associated with cirrhosis and is also a risk factor for nonalcoholic fatty liver disease, including nonalcoholic steatohepatitis, which can lead to liver fibrosis, cirrhosis, and hepatocellular carcinoma. Diabetes may also increase the risk of postoperative hepatic decompensation.<sup>11</sup> The extent of liver resection is one of the major factors for POLF. The critical residual volume is related to the incidence of postoperative function. The correlation between remnant liver mass and regeneration is frequently linked to the development of POLF.<sup>10</sup> Failure to regenerate occurs when the remnant liver volume is below a certain threshold. Schindl *et al.* have shown that a remnant volume that is 26% of the original liver volume seems to be the threshold in noncirrhotic patients. Liver volumetry using axial images from two-dimensional CT scans is used to measure the future remnant liver volume as a predictor of postoperative hepatic dysfunction. In cirrhotic livers, functional reserve is impaired, resulting in a reduced regeneration capacity and a higher probability of POLF following resection.<sup>12</sup> An expected remnant volume (expressed as a percentage of total liver volume) greater than 40% is suggested in patients with parenchymal disease such as cirrhosis.<sup>13</sup>

A schematic representation of the causes of POLF is displayed in figure 2. Postoperative conditions such as hepatic congestion and sepsis can also be responsible for POLF by themselves or in combination with small remnant liver volume. Hepatic congestion is a well described etiology for POLF.<sup>1,8</sup> Congestion can be related to liver outflow obstruction



**Fig. 2.** Schematic representation of postoperative liver failure causes after hepatic resection.

tion, which highlights the importance of preserving the venous drainage of the remnant liver for adequate liver function.<sup>1</sup> Hepatic congestion can be also related to excessive inflow pressure or flow. Shear stress is an important component of liver regeneration, but excessive pressure in the portal vein could be responsible for increased sinusoidal perfusion, which can induce sinusoidal endothelial cell injury and subsequently reduce hepatocyte regeneration.<sup>14</sup> This concept, which originates from experiences with living donor liver transplantation, has been named small for size syndrome. “Small-for-size” syndrome arises when a partial graft cannot cope with the unique stresses placed upon it because of its small size. Although there is no standard definition, small-for-size syndrome may be diagnosed clinically when prolonged hyperbilirubinemia, coagulopathy, ascites, and/or encephalopathy arise.<sup>14</sup> Based on the small size of the remnant liver, a similar syndrome can be observed following hepatic resection.

Sepsis or infection plays a key role in POLF occurrence, particularly during acute liver failure. However, a causal relationship between POLF and infection has not been fully elucidated.<sup>8,9,15</sup> On the one hand, liver failure is a risk factor for infections<sup>4</sup> with an incidence as high as 40–80%.<sup>16</sup> It has been shown that 73% of patients with postoperative liver dysfunction develop postoperative sepsis compared with 18% of patients without POLF.<sup>15</sup> On the other hand, sepsis has detrimental effects on liver function and affects hepatic regeneration.<sup>10</sup> Sepsis can cause hypotension resulting in hepatic ischemia. It induces Kupffer cells dysfunction, increases proinflammatory cytokines, and causes the release of toxic liver endotoxins that may have an inhibitory effect on hepatocyte proliferation.<sup>10</sup> Consequently, sepsis diminishes the liver’s capacity for regeneration. Sepsis is an independent predictor of death in patients with POLF.<sup>9</sup> Furthermore, liver surgery itself likely increases the risk of infection. Indeed, hepatectomy is associated with enteric bacterial translocation and the risk of translocation increases with portal clamping. Major liver resections significantly reduce the functional capacity of the reticuloendothelial system, which

**Table 1.** Child-Pugh Classification for the Assessment of the Severity of Cirrhosis

	1 Point	2 Points	3 Points
Total Bilirubin, $\mu\text{M}$ (mg/dl) Serum	<34 (<2)	34–50 (2–3)	>50 (>3)
albumin, g/L	>35	28–35	<28
INR	<1.7	1.71–2.20	>2.20
Ascites	None	Mild	Severe
Hepatic encephalopathy	None	Grade I or II	Grade III–IV

Class A cirrhosis: 6–8 points, Class B cirrhosis: 7–9 points, Class C: 10–15 points.

INR = International Normalized Ratio.

plays a pivotal role in bacterial immune defense.<sup>17</sup> Our present patient was suffering from cirrhosis, which is a very well documented additional risk factor for sepsis. Patients with cirrhosis develop bacterial infections more frequently than those without cirrhosis. Infection in these patients is accompanied by a markedly imbalanced cytokine release along with an excessive proinflammatory response and an increased risk of sepsis, severe sepsis, or septic shock.<sup>18</sup> Moreover, infection and systemic inflammation appear to be associated with severe hepatic encephalopathy in cirrhotic patients.<sup>19</sup>

In the present case, the pathologic examination of the remnant liver did not display any specific histologic abnormalities. This suggests that POLF was likely related to the large resection, which left a relatively small remnant cirrhotic liver and was probably worsened by infection.

### How Is Postoperative Liver Failure Following Liver Resection in Cirrhotic Patients Prevented?

Based on the scarcity of therapeutic options for POLF, a great effort should be made to prevent its occurrence. The following section describes meticulous preoperative selection and optimization strategies, optimal intraoperative surgical and anesthetic techniques, and cautious postoperative care, a combination of perioperative strategies designed to prevent POLF occurrence.

**Preoperative Care.** Preoperative patient evaluation allows the physician to determine the functional reserve of the liver and to predict the volume of the remnant liver. The functional liver capacity can be assessed with the Child-Pugh classification system, which is a predictor of postoperative morbidity (table 1).<sup>20</sup> The general consensus is that liver surgery should only be conducted in patients with nondecompensated cirrhosis, classified as Child A, and in some very well selected Child B patients. The Model for End-stage Liver Disease score combines bilirubinemia, creatinine, and INR according to the following formula:  $(0.957 \cdot \ln(\text{serum creatinine}) + 0.378 \cdot \ln(\text{serum bilirubin}) + 1.120 \cdot \ln(\text{INR}) + 0.643) \cdot 10$ . This score reflects hepatocellular function. A Model for End-stage Liver Disease score of more than 10, when compared with a score of less than 9, is associated with

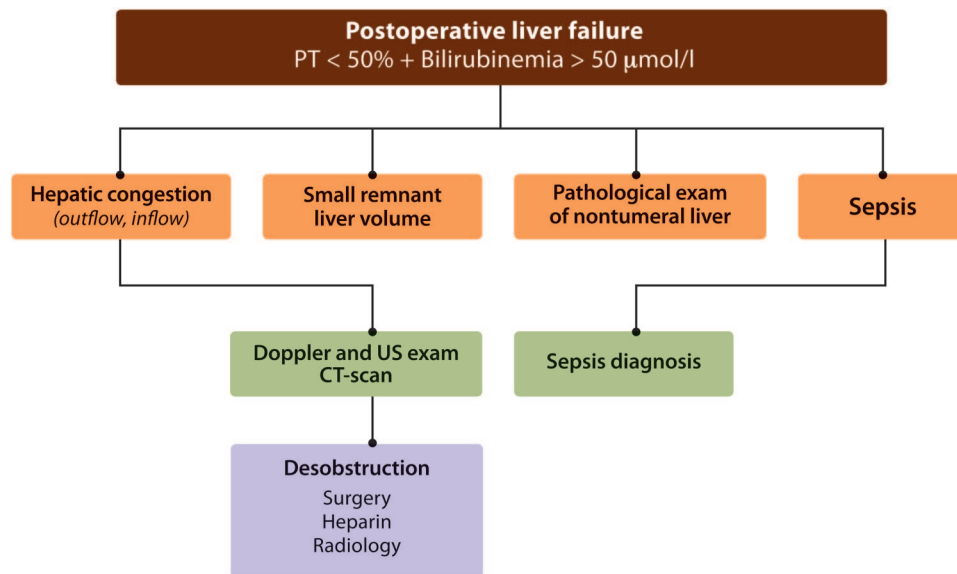
a significant increased risk of POLF after hepatectomy for hepatocellular carcinoma in cirrhotics.<sup>21</sup> Portal hypertension, which is a contraindication for major liver resection in cirrhotic patient, is assessed by the presence of esophageal varices, ascites, splenomegaly, or thrombocytopenia. Some authors suggest measuring the hepatic vein pressure gradient to predict the risk of postoperative liver failure.<sup>22</sup> The hepatic functional reserve can also be evaluated with functional tests. Assessment of the plasma indocyanine green disappearance rate by pulse spectrophotometry is a noninvasive measure of liver function that has been widely used to assess functional liver reserve in patients with chronically reduced hepatic function. It can also be used to preoperatively assess liver function reserve and safety limits for the liver resection size.<sup>23</sup>

In patients with predicted remnant liver volumes that are insufficient, preoperative portal vein embolization is used to induce atrophy of the embolized, tumor-bearing liver segments and hypertrophy of the nonembolized segments. Depending on the underlying liver function, portal vein embolization can increase liver volume by 8–16% and increase liver function in the future remnant liver.<sup>24</sup> Portal venous embolization has been shown to reduce the risk of postoperative liver failure.<sup>3</sup>

**Intraoperative Care.** Volatile anesthetic agents have been associated with adverse hepatic reactions. However, there is a general lack of evidence demonstrating hepatotoxicity from either desflurane or sevoflurane, and hepatotoxicity of anesthetic agents is no longer a significant clinical concern.<sup>25</sup>

Intraoperative blood loss and subsequent need for blood transfusions are predictors of POLF. In cirrhotic patients, postoperative metabolic acidosis following hepatic surgery is worsened by intraoperative blood loss and could be related to hepatic functional reserve and the complexity of the surgical resection.<sup>26</sup> The immediate postresection bicarbonate level could be used as an early predictor of POLF.<sup>26</sup> Tranexamic acid, an antifibrinolytic drug, has been shown to reduce intraoperative blood loss and the need for blood transfusion during liver resection.<sup>27</sup> This suggests that the use of tranexamic acid should be considered, especially for liver resections associated with a high risk of blood transfusion. Surgical techniques such as vascular occlusion, namely portal occlusion, have been reported to reduce intraoperative bleeding. Systematic studies have shown that portal clamping is associated with a significant reduction in intraoperative bleeding.<sup>28</sup> However, none of these studies demonstrated a significant reduction in erythrocyte transfusions. Furthermore, vascular occlusion techniques are consistently associated with liver ischemia–reperfusion injury. Intermittent vascular pedicular clamping has been developed to improve parenchymal tolerance to clamping. For liver surgery in cirrhosis, repeated 10-min episodes of hepatic vascular clamping interrupted by 5 min of reperfusion as well as a cumulative length of vascular clamping not exceeding 1 h have been proposed.<sup>7</sup> Liver surgery without clamping has also been proposed to reduce parenchymal ischemia.<sup>29</sup> In patients with





**Fig. 3.** Proposed management for postoperative liver failure. CT = computed tomography;  $\mu\text{mol/l} = \mu\text{M}$ ; PT = prothrombin time; US = ultrasound.

chronic liver disease, measures such as portal vein embolization, avoidance of parenchymal ischemia, and minimization of blood loss are crucial to decreasing postoperative morbidity and mortality.<sup>3,12</sup>

The development of therapeutic approaches to ischemia-reperfusion injury has allowed for some randomized clinical trials.<sup>30</sup> Ischemic preconditioning before continuous hepatic pedicle clamping could reduce reperfusion injury, particularly in steatotic livers. However, randomized clinical trials have not confirmed that ischemic preconditioning has a positive effect on outcomes. Preconditioning with sevoflurane has been shown to significantly limit the postoperative increase of serum transaminases and the rate of postoperative complications.<sup>31</sup> Recently, an experimental model has suggested that pretreatment with remifentanyl can attenuate liver injury both *in vivo* and *in vitro*. These effects were thought to be mediated through inducible nitric oxide synthase by exhausting reactive oxygen species and attenuating the inflammatory response.<sup>32</sup> These novel pharmacological approaches have generated a new interest in the choice of anesthetic agents, which might influence the postoperative outcome.

**Postoperative Care.** Postoperative analgesia is usually provided with patient-controlled analgesia and combined with acetaminophen because of the morphine-sparing effect of this agent. However, concerns exist about the safety of acetaminophen, particularly in patients at risk for liver failure.<sup>33</sup> Moreover, acetaminophen metabolism may be impaired after hepatic resection.<sup>34</sup> At present, despite the absence of definitive data, it seems reasonable to avoid the use of acetaminophen for postoperative analgesia after liver surgery in patients at risk for POLF, such as those with cirrhosis.

#### How Is Postoperative Liver Failure Treated?

POLF should be recognized as early as possible. Criteria such as bilirubinemia exceeding  $50 \mu\text{M}$  and PT less than 50% (INR more than 1.7) on postoperative day 3 could be used as early warning signs.<sup>2</sup> This is crucial for triggering early recognition of the potentially curable complications of POLF (fig. 3).

Vascular complications such as portal thrombosis or suprahepatic abnormalities responsible for venous liver congestion can be detected by ultrasonography and Doppler or CT scan. Whether early postoperative portal thrombosis should be surgically managed by desobstruction or treated with anticoagulants is debated. Liver outflow obstruction can be surgically cured when caused by the rotation of the remnant liver. Improvement of the venous outflow could also be achieved with endovascular treatment using a metallic stent.<sup>35</sup> Small-for-size syndrome may potentially be managed by decreasing portal venous inflow into the remnant liver *via* splenic artery embolization.<sup>36</sup>

Avoidance of postoperative sepsis is a key issue in the management of POLF. It should be noted that the diagnosis of infection based on commonly used biomarkers of sepsis, such as C-reactive protein, might not be accurate in this situation. Following major hepatic resection, C-reactive protein levels were decreased in patients with POLF, probably reflecting a decrease in functional liver mass.<sup>5</sup> This is consistent with what has been reported in acute liver failure where C-reactive protein levels appeared to be more closely related to acute liver failure severity than to ongoing infection.<sup>37</sup> Based on the very high risk of sepsis in these patients and its negative effects on outcome, current guidelines for acute liver failure management recommend frequent utilization of antimicrobial therapy.<sup>4</sup> There is currently no randomized trial that has compared a systematic use of antibiotics *versus* clin-

ically guided administration of antibiotics in acute liver failure. Whether antibiotics should be systematically administered in POLF remains to be determined.

### **What Is the Role of Liver Transplantation for Postoperative Liver Failure?**

Liver transplantation is the only radical treatment that improves survival in patients with end-stage liver disease. However, patients suffering from POLF are rarely eligible candidates for liver transplantation because of tumor characteristics or comorbid conditions. Liver transplantation for POLF is associated with significant morbidity but could provide treatment for an otherwise fatal condition.<sup>38</sup> According to the Milan criteria, indications for liver transplantation are single-lesion hepatocellular carcinomas of 5 cm or fewer and multiple tumors with no more than 3 nodules, each of which is 3 cm or fewer.<sup>22,38</sup> Based on these criteria, our patient was a suitable candidate for liver transplantation.

### **What Is the Role of Extra Hepatic Assistance Devices in Postoperative Liver Failure?**

Artificial liver devices have been developed in the last few years. These devices can be divided into extracorporeal epuration systems, usually based on albumin dialysis, and bioartificial devices based on bioreactors containing hepatocytes. The former have been the most frequently studied. However, none have been specifically studied in the setting of POLF, with the exception of one case series with no obvious beneficial outcome. Outcomes for the use of these various devices in the management of acute liver failure are also unclear.<sup>39</sup> They are not currently recommended in the medical management of acute liver failure patients.<sup>4</sup> Because their actual place in the global field of acute or on acute chronic liver failure remains to be determined, their role in POLF is undefined. However, because POLF is typically a fatal condition, it is important to investigate the potential roles of these devices.

### **Knowledge Gap**

The field of unanswered questions about POLF is large. As we have seen earlier, pharmacological modulation of ischemia/reperfusion has not yet been incorporated into clinical practice despite its apparent impact on clinically relevant outcomes. However, this remains an important field of ongoing research that generates interest in the choice of pharmacological anesthetic agents that may influence postoperative outcome.

The role of platelets in liver regeneration has been recently highlighted.<sup>40</sup> After partial liver resection, a low platelet count is an independent predictor of delayed postoperative liver function recovery and is associated with an increased risk of postoperative mortality. The potential therapeutic consequences of these findings would need to be studied.

Modulation of hepatic regeneration after hepatectomy is another interesting field of research.<sup>10</sup> It has recently been

suggested that the abrupt regenerative response of a small remnant liver may be responsible for intense lobular derangement and subsequent liver dysfunction. The suppression of the mitogen-activated protein kinase kinase/extracellular signaling pathway during the early posthepatectomy phase makes the regenerative response linear, and improves the prognosis for animals bearing a small remnant liver.<sup>41</sup> This approach opens a new field of investigation and therapeutic options for the prophylaxis of POLF. Finally, the effects of portal pressure modulation after extensive hepatectomy and small remnant liver deserve attention. This technique could be associated with a significant improvement of outcome.

Hepatic encephalopathy should be appropriately diagnosed and supportive treatment should be offered. It is of note that ammonia appears to decrease neutrophil function, and as such may increase the risk of infection and the inflammatory response.<sup>19</sup> Whether or not agents used to decrease ammonia levels benefit this group of patients remains to be clarified.

### **References**

1. Agrawal S, Belghiti J: Oncologic resection for malignant tumors of the liver. *Ann Surg* 2011; 253:656-65
2. Paugam-Burtz C, Janny S, Delefosse D, Dahmani S, Dondero F, Mantz J, Belghiti J: Prospective validation of the "fifty-fifty" criteria as an early and accurate predictor of death after liver resection in intensive care unit patients. *Ann Surg* 2009; 249:124-8
3. Abulkhir A, Limongelli P, Healey AJ, Damrah O, Tait P, Jackson J, Habib N, Jiao LR: Preoperative portal vein embolization for major liver resection: A meta-analysis. *Ann Surg* 2008; 247:49-57
4. Bernal W, Auzinger G, Dhawan A, Wendon J: Acute liver failure. *Lancet* 2010; 376:190-201
5. Reissfelder C, Rahbari NN, Koch M, Kofler B, Sutudja N, Elbers H, Büchler MW, Weitz J: Postoperative course and clinical significance of biochemical blood tests following hepatic resection. *Br J Surg* 2011; 98:836-44
6. Rahbari NN, Garden OJ, Padbury R, Brooke-Smith M, Crawford M, Adam R, Koch M, Makuuchi M, Dematteo RP, Christophi C, Banting S, Usatoff V, Nagino M, Maddern G, Hugh TJ, Vauthey JN, Greig P, Rees M, Yokoyama Y, Fan ST, Nimura Y, Figueras J, Capussotti L, Büchler MW, Weitz J: Posthepatectomy liver failure: A definition and grading by the International Study Group of Liver Surgery (ISGLS). *Surgery* 2011; 149:713-24
7. Clavien PA, Petrowsky H, DeOliveira ML, Graf R: Strategies for safer liver surgery and partial liver transplantation. *N Engl J Med* 2007; 356:1545-59
8. van den Broek MA, Olde Damink SW, Dejong CH, Lang H, Malagó M, Jalan R, Saner FH: Liver failure after partial hepatic resection: Definition, pathophysiology, risk factors and treatment. *Liver Int* 2008; 28:767-80
9. Capussotti L, Viganò L, Giuliante F, Ferrero A, Giovannini I, Nuzzo G: Liver dysfunction and sepsis determine operative mortality after liver resection. *Br J Surg* 2009; 96:88-94
10. Garcea G, Maddern GJ: Liver failure after major hepatic resection. *J Hepatobiliary Pancreat Surg* 2009; 16:145-55
11. Huo TI, Wu JC, Lui WY, Huang YH, Lee PC, Chiang JH, Chang FY, Lee SD: Differential mechanism and prognostic impact of diabetes mellitus on patients with hepatocellular carcinoma undergoing surgical and nonsurgical treatment. *Am J Gastroenterol* 2004; 99:1479-87
12. Ercolani G, Ravaioli M, Grazi GL, Cescon M, Del Gaudio M,

- Vetrone G, Zanello M, Pinna AD: Use of vascular clamping in hepatic surgery: Lessons learned from 1260 liver resections. *Arch Surg* 2008; 143:380-7
13. Clavien PA, Emond J, Vauthey JN, Belghiti J, Chari RS, Strasberg SM: Protection of the liver during hepatic surgery. *J Gastrointest Surg* 2004; 8:313-27
  14. Dahm F, Georgiev P, Clavien PA: Small-for-size syndrome after partial liver transplantation: Definition, mechanisms of disease and clinical implications. *Am J Transplant* 2005; 5:2605-10
  15. Schindl MJ, Redhead DN, Fearon KC, Garden OJ, Wigmore SJ, Edinburgh Liver Surgery and Transplantation Experimental Research Group (eLISTER): The value of residual liver volume as a predictor of hepatic dysfunction and infection after major liver resection. *Gut* 2005; 54:289-96
  16. Han MK, Hyzy R: Advances in critical care management of hepatic failure and insufficiency. *Crit Care Med* 2006; 34:S225-31
  17. Schindl MJ, Millar AM, Redhead DN, Fearon KC, Ross JA, Dejong CH, Garden OJ, Wigmore SJ: The adaptive response of the reticuloendothelial system to major liver resection in humans. *Ann Surg* 2006; 243:507-14
  18. Gustot T, Durand F, Lebrech D, Vincent JL, Moreau R: Severe sepsis in cirrhosis. *Hepatology* 2009; 50:2022-33
  19. Shawcross DL, Sharifi Y, Canavan JB, Yeoman AD, Abeles RD, Taylor NJ, Auzinger G, Bernal W, Wendon JA: Infection and systemic inflammation, not ammonia, are associated with Grade 3/4 hepatic encephalopathy, but not mortality in cirrhosis. *J Hepatol* 2011; 54:640-9
  20. Schroeder RA, Marroquin CE, Bute BP, Khuri S, Henderson WG, Kuo PC: Predictive indices of morbidity and mortality after liver resection. *Ann Surg* 2006; 243:373-9
  21. Cescon M, Cucchetti A, Grazi GL, Ferrero A, Viganò L, Ercolani G, Zanello M, Ravaioli M, Capussotti L, Pinna AD: Indication of the extent of hepatectomy for hepatocellular carcinoma on cirrhosis by a simple algorithm based on preoperative variables. *Arch Surg* 2009; 144:57-63
  22. Bruix J, Sherman M: Practice Guidelines Committee, American Association for the Study of Liver Diseases: Management of hepatocellular carcinoma. *Hepatology* 2005; 42:1208-36
  23. Seyama Y, Kokudo N: Assessment of liver function for safe hepatic resection. *Hepatol Res* 2009; 39:107-16
  24. de Graaf W, van Lienden KP, van den Esschert JW, Bennink RJ, van Gulik TM: Increase in future remnant liver function after preoperative portal vein embolization. *Br J Surg* 2011; 98:825-34
  25. Kharasch ED: Adverse drug reactions with halogenated anesthetics. *Clin Pharmacol Ther* 2008; 84:158-62
  26. Cucchetti A, Siniscalchi A, Ercolani G, Vivarelli M, Cescon M, Grazi GL, Faenza S, Pinna AD: Modification of acid-base balance in cirrhotic patients undergoing liver resection for hepatocellular carcinoma. *Ann Surg* 2007; 245:902-8
  27. Wu CC, Ho WM, Cheng SB, Yeh DC, Wen MC, Liu TJ, P'eng FK: Perioperative parenteral tranexamic acid in liver tumor resection: A prospective randomized trial toward a "blood transfusion"-free hepatectomy. *Ann Surg* 2006; 243:173-80
  28. Rahbari NN, Wente MN, Schemmer P, Diener MK, Hoffmann K, Motschall E, Schmidt J, Weitz J, Büchler MW: Systematic review and meta-analysis of the effect of portal triad clamping on outcome after hepatic resection. *Br J Surg* 2008; 95:424-32
  29. Scatton O, Massault PP, Dousset B, Houssin D, Bernard D, Terris B, Soubrane O: Major liver resection without clamping: A prospective reappraisal in the era of modern surgical tools. *J Am Coll Surg* 2004; 199:702-8
  30. Bahde R, Spiegel HU: Hepatic ischaemia-reperfusion injury from bench to bedside. *Br J Surg* 2010; 97:1461-75
  31. Beck-Schimmer B, Breitenstein S, Urech S, De Conno E, Wittlinger M, Puhani M, Jochum W, Spahn DR, Graf R, Clavien PA: A randomized controlled trial on pharmacological preconditioning in liver surgery using a volatile anesthetic. *Ann Surg* 2008; 248:909-18
  32. Yang LQ, Tao KM, Liu YT, Cheung CW, Irwin MG, Wong GT, Lv H, Song JG, Wu FX, Yu WF: Remifentanyl preconditioning reduces hepatic ischemia-reperfusion injury in rats *via* inducible nitric oxide synthase expression. *ANESTHESIOLOGY* 2011; 114:1036-47
  33. Forget P, Wittebole X, Laterre PF: Therapeutic dose of acetaminophen may induce fulminant hepatitis in the presence of risk factors: A report of two cases. *Br J Anaesth* 2009; 103:899-900
  34. Galinski M, Delhotal-Landes B, Lockey DJ, Rouaud J, Bah S, Bossard AE, Lapostolle F, Chauvin M, Adnet F: Reduction of paracetamol metabolism after hepatic resection. *Pharmacology* 2006; 77:161-5
  35. Wang JK, Truty MJ, Donohue JH: Remnant torsion causing Budd-Chiari syndrome after right hepatectomy. *J Gastrointest Surg* 2010; 14:910-2
  36. Umeda Y, Yagi T, Sadamori H, Matsukawa H, Matsuda H, Shinoura S, Mizuno K, Yoshida R, Iwamoto T, Satoh D, Tanaka N: Effects of prophylactic splenic artery modulation on portal overperfusion and liver regeneration in small-for-size graft. *Transplantation* 2008; 86:673-80
  37. Silvestre JP, Coelho LM, Povoas PM: Impact of fulminant hepatic failure in C-reactive protein? *J Crit Care* 2010; 25:657 e7-12
  38. Otsuka Y, Duffy JP, Saab S, Farmer DG, Ghobrial RM, Hiatt JR, Busuttill RW: Postresection hepatic failure: Successful treatment with liver transplantation. *Liver Transpl* 2007; 13:672-9
  39. Stutchfield BM, Simpson K, Wigmore SJ: Systematic review and meta-analysis of survival following extracorporeal liver support. *Br J Surg* 2011; 98:623-31
  40. Alkozai EM, Nijsten MW, de Jong KP, de Boer MT, Peeters PM, Slooff MJ, Porte RJ, Lisman T: Immediate postoperative low platelet count is associated with delayed liver function recovery after partial liver resection. *Ann Surg* 2010; 251:300-6
  41. Ninomiya M, Shirabe K, Terashi T, Ijichi H, Yonemura Y, Harada N, Soejima Y, Taketomi A, Shimada M, Maehara Y: Deceleration of regenerative response improves the outcome of rat with massive hepatectomy. *Am J Transplant* 2010; 10:1580-7