

# ANESTHESIOLOGY

The Journal of

THE AMERICAN SOCIETY OF ANESTHETISTS, INC.

---

---

Volume 2

JULY, 1941

Number 4

---

---

## REGIONAL BLOCK ANESTHESIA FOR OPERATIONS ON THE PERINEUM, ANUS, GENITALIA AND LOWER EXTREMITIES

EDWARD B. TUOHY, M.D., M.S. (Anes.) \*

*Rochester, Minn.*

It is important for a satisfactory production of local anesthesia of any portion of the body that one have an accurate knowledge of topographic anatomy and in addition a thorough knowledge of the nerve supply to the various portions of the body which are to be anesthetized. This knowledge is particularly applicable in considering local anesthetic procedures for operations on the genitalia, such as epididymectomy, orchectomy and operations for the relief of varicocele or hydrocele. It is important that one keep in mind the nerve supply to this region. The pudendal plexus (Fig. 1) (1) supplies sensory innervation to the external genitalia, chiefly through the pudendal nerve (internal pudic) and the inferior pudendal branch of the posterior femoral cutaneous nerve (small sciatic). The inferior pudendal branch innervates a portion of the skin of the scrotum in men or the labia majora in women. The pudendal nerve (internal pudic nerve) divides into two terminal branches—the perineal nerve and the dorsal nerve of the penis or clitoris. The perineal nerve divides again into the posterior scrotal (or labial) and muscular branches. The terminal fibers of the ilio-inguinal nerve also innervate the skin of the scrotum or the greater labia. In addition, the genitofemoral nerve (genitocrural nerve) with its external spermatic and lumbo-inguinal branches supplies sensory innervation to the external genitalia. The external spermatic nerve follows behind the spermatic cord to the scrotum and a few filaments go to the skin of the scrotum in men or the greater labia in women (Fig. 2).

\* Section on Anesthesia, Mayo Clinic, Rochester, Minnesota.

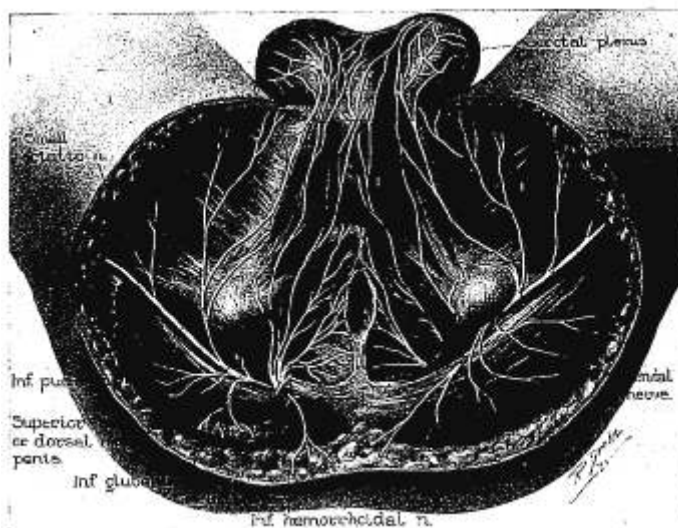


FIG. 1. The male perineum, showing the distribution of the various nerves of the pudendal plexus. (From Labat, Gaston: *Regional Anesthesia*. Philadelphia, Pa. W. B. Saunders Company. 1922. 496 pp.)

It is apparent, therefore, from the diverse sensory innervation of the perineum and external genitalia that one must obtain complete block of all sensory nerves supplying this region if one is to expect satisfactory anesthesia. Anesthesia of the perineum and external genitalia is more complete if one uses a caudal transsacral block, which will anesthetize both the pudendal and sacral plexus, and then injects the solution locally into the skin and the subcutaneous tissue of the pubic region. If it is not necessary that the perineum be anesthetized completely and the operative procedure is rather limited as, for example, excision of a Bartholin cyst, one may inject the solution about the inferior pudendal nerve and the internal pudic nerve separately near the tuberosities of the ischia (Fig. 1). Block of these nerves may be achieved by inserting an 80 mm. needle, first mesially and then also laterally to the tuberosity of the ischia on each side of the tuberosity on a level with the posterior border of the anus. The tip of the needle is inserted to a depth of 2.5 cm. and at this point 15 to 25 cc. of a 1 per cent solution of procaine hydrochloride or metycaine is injected.

In circumcision operations local infiltration of the prepuce may be followed by sloughing of the tissues, especially if a vasoconstrictor is incorporated in the local anesthetic agent. It is therefore preferable for this operation to block the nerve supply of the penis at its base. A

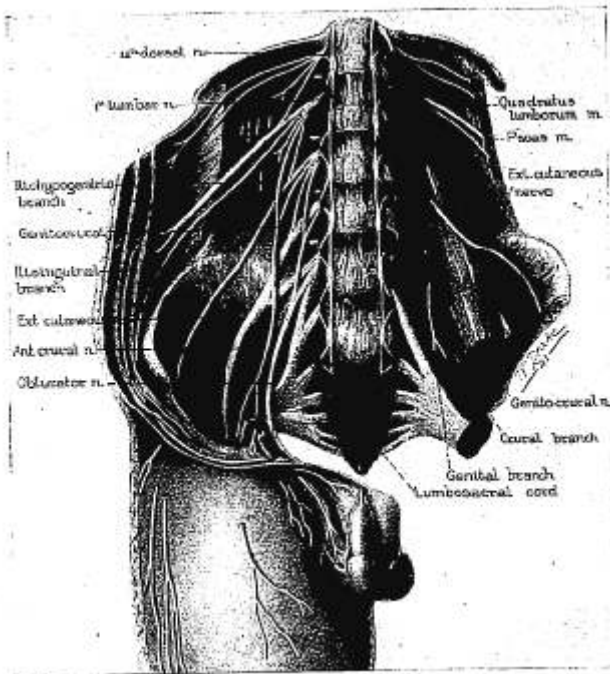


FIG. 2. The various branches of the lumbar plexus.

skin wheal is raised at the base of the penis near the middle of the symphysis pubis and an intradermal injection using 20 to 25 cc. of a 0.5 per cent solution of procaine or metycaine is made about the base of the penis at the penoscrotal juncture. After this infiltration, 5 cc. of a 1 per cent solution of the anesthetic agent is injected directly into the corpora cavernosa, utilizing the original skin wheal over the symphysis pubis.

Operations for hydrocele, varicocele, and so forth, usually will require sacral nerve block anesthesia and in addition local infiltration of the skin in the lower part of the inguinal region in order to anesthetize the terminal fibers of the ilio-inguinal and genito-crural nerves. A local infiltration of these latter nerves is done in the lower part of the inguinal region at the level of the external inguinal ring plus an injection into the structures of the spermatic cord at about the level of the pubic spine. If a sacral nerve block is not used, one must make an intradermal infiltration circumferentially around the base of the scrotum and infiltrate the line of incision, in addition to the local anesthetization of the ilio-inguinal and genito-crural nerves.

BLOCK ANESTHESIA FOR SUCH PROCEDURES AS LIGATION OF THE GREATER SAPHENOUS VEIN AND REPAIR OF FEMORAL HERNIA

The sensory innervation of this region is supplied by (1) anterior branches of the lateral femoral cutaneous nerve, (2) anterior femoral cutaneous nerve, (3) filaments of the ilio-inguinal nerve, and (4) the lumbo-inguinal branch of the genitofemoral nerve (Fig. 3). The block is produced by making an intradermal skin wheal just mesial to the an-

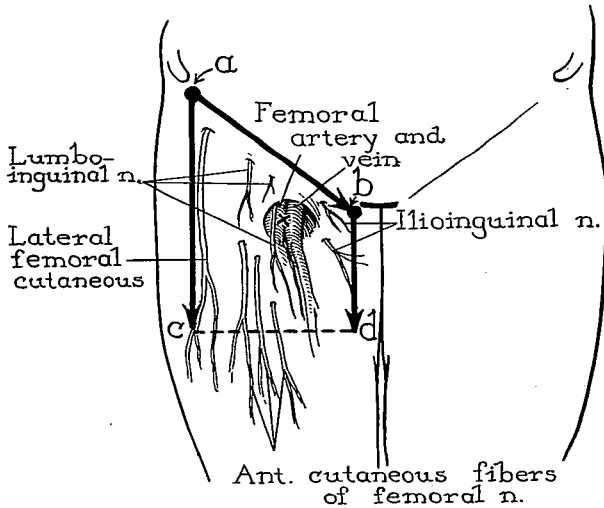


FIG. 3. The sensory innervation of the anterior surface of the upper part of the thigh and the type of field block used for operations in this region, such as the repair of femoral hernia or the ligation of the greater saphenous vein. The injection is made as indicated by the direction of the arrows; that is, *a* to *b*, *a* to *c*, and *b* to *d*. In a few instances it is necessary to inject between *c* and *d*. At the point marked *x*, 5 cc. of a 1 per cent solution of the anesthetic agent is deposited directly over the femoral artery and vein.

terior iliac spine and below it and then continuing an intradermal injection in the line of the inguinal ligament as far as the spine of the pubis, using a 0.5 per cent solution of procaine or metycaine. Next a similar type of injection (intradermal and subcutaneous) is made in a straight line directly below the anterior superior iliac spine for about 7 inches (18 cm.). This infiltration will anesthetize the terminal fibers of the lateral femoral cutaneous nerve. A similar infiltration is made, practically parallel to this latter infiltration from a point near the symphysis pubis along the mesial side of the thigh for about 5 or 6 inches (13 or 15 cm.). This latter injection will anesthetize the terminal branches of the ilio-inguinal nerve in this region.

For repair of femoral hernia it is best to complete the rectangular area by injecting intradermally and subcutaneously from the line of infiltration on the mesial side to that on the lateral side of the thigh in order to assure a complete block of the branches of the anterior femoral cutaneous nerve. During the repair of the hernia when traction is made on the femoral hernial sac, it is usually necessary to supplement this block by local infiltration at the base of the hernial sac itself.

For other operations in this region such as ligation of the greater saphenous vein an additional injection of a 1 per cent solution of procaine or metycaine is made directly over the point where the greater saphenous vein pierces the cribriform fascia of the saphenous opening to enter the femoral vein. This injection is facilitated by palpating with the middle or index finger of the left hand—if the anesthetist is right-handed—the femoral artery which lies lateral to the femoral vein and then introducing the needle just mesial to the palpating finger tip directly downward toward the femoral vein. An injection of 5 cc. of a 1 per cent solution is deposited in this region. The branches of the lumbo-inguinal nerve supplying the vessels in this region will be blocked by this injection.

#### BLOCK OF THE GREATER AND LESSER SCIATIC NERVES (POSTERIOR FEMORAL CUTANEOUS NERVE)

For operations on the posterior region of the thigh and for various orthopedic manipulations, sciatic nerve block may be indicated. Direct intraneural injection with 95 per cent alcohol is fairly common in cases of intractable sciatic neuritis. The great sciatic nerve emerges from the pelvis through the great sacrosciatic foramen. It passes below the piriformis muscle between the greater trochanter of the femur and the tuberosity of the ischium.

The sciatic nerve can be injected when the patient lies face downward, but it is more accurately reached when the patient lies in a modified Sims' position with the side to be injected uppermost. The thigh is flexed moderately on the abdomen so that the axis of the femur passes through the posterior superior iliac spine. A line is then traced from the greater trochanter of the femur to the posterior superior iliac spine and then bisected. From the midpoint of this ilirotrochanteric line a perpendicular is dropped downward 3 cm. This marks the point at which the initial skin wheal is raised (Fig. 4). An 80 mm. needle is introduced through this wheal and advanced perpendicularly until bony contact is made with the neck of the femur, the depth at which the bone is felt, being usually 5 to 6 cm. from the surface of the skin. Since the sciatic nerve trunk is quite large, paresthesia is obtained easily near the neck of the femur. For purposes of anesthesia, 8 to 12 cc. of a 2 per cent solution of procaine is injected paraneurally. The lesser, or small,

sciatic nerve lies on the posterior aspect of the great sciatic nerve, and injection may be performed through the same point on the skin surface.

#### CAUDAL AND TRANSSACRAL ANESTHESIA (2, 3)

A so-called saddle type of anesthesia is produced by blocking the sacral nerves and this permits operations on the anus, rectum or perineum, or in the urinary bladder, and certain gynecologic procedures such as perineorrhaphy, operations for cystocele or rectocele and vaginal hysterectomy. The dome of the bladder and the fundus of the uterus are not anesthetized by caudal transsacral anesthesia, but usually

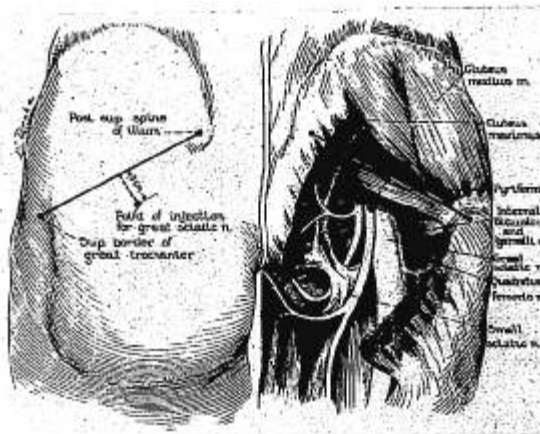


Fig. 4. Block anesthesia of the greater and lesser sciatic nerve. (From Labat, Gaston; Regional Anesthesia. Philadelphia, Pa. W. B. Saunders Company. 1922. 496 pp.)

this is not essential for the types of operation mentioned. Furthermore, in transurethral manipulations such as prostatectomy or fulguration of vesical tumors, it is advantageous to have sensation present in the dome of the bladder to prevent inadvertent overdistention of the bladder.

The decided advantage which this type of anesthesia possesses over methods of general anesthesia in operative procedures on the lower part of the rectum and anus rarely is challenged. The risk of caudal transsacral anesthesia, as compared with that of various methods of inhalation, intravenous, rectal or even spinal anesthesia, is negligible. Since the muscles of the anal sphincters are some of the last in the body to relax under general anesthesia, it is necessary to induce deep surgical anesthesia in order to obtain adequate operative relaxation. It is ac-

cepted that spinal anesthesia is accomplished more easily than caudal transsacral anesthesia and that it is ordinarily reasonably satisfactory; there are disadvantages to spinal anesthesia, however, such as nausea, a fall in systolic blood pressure and postspinal headache.

The use of local infiltration anesthesia in proctologic surgery is undesirable ordinarily because in order to produce sufficient anesthesia and relaxation by this method, the amount of solution required is such that deformity of the tissues occurs and it is difficult to estimate the amount of tissue which should be excised. Furthermore, in the presence of edema, ulceration and acutely inflamed tissues around the anus, local infiltrative anesthesia should be avoided.

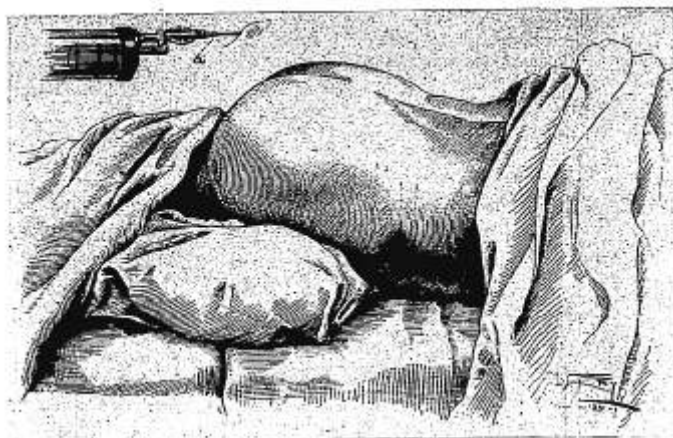


FIG. 5. Sacral block anesthesia, showing the proper position of patient on table. a. The position of the syringe when the initial skin wheel is raised prior to injection of the anesthetic solution into the caudal canal. (From Lundy, J. S., and McCuskey, C. F.: Sacral Anesthesia in Operations on the Rectum, *Atlantic Med. J.* 30: 14-20, 1926.)

Inasmuch as caudal transsacral anesthesia can be used for a multiplicity of purposes and is one of the most reliable and safest procedures, it seems reasonable to give considerable space to its description. There are few nerve plexuses or individual nerves in the body which may be anesthetized as uniformly and accurately as the sacral nerves. Whereas the procedure of caudal transsacral block has been condemned by some because of the complexity of technic, this criticism is not wholly justified because at least the technic of caudal injection can be mastered by most persons in a short time. The transsacral technic requires more care and diligence, but it also may be acquired if careful adherence to detail is maintained. Less skill will be necessary if suggestions and details are followed.

Before proceeding with the injection in any case, using sacral anesthesia, one should be sure that the patient is placed comfortably in the prone position on the table with a pillow of medium size under his hips to accentuate the superficial landmarks (Fig. 5). Occasionally the use of an adjustable kidney rest, covered with a small pillow placed beneath the patient's hips, will facilitate the injection in the case of obese patients because the rest can be elevated or lowered to the point at which the posterior bony landmarks of the sacrum and pelvis are most prominent. With certain thin patients, for example, those who have marked lordosis, no elevation of the hips is required because the sacral region is sufficiently prominent.

By observation alone, when a patient is placed properly on the table, one can visualize the rhomboid of Michaelis, which is formed by straight lines drawn bilaterally from the gluteal cleft to the dimples in the skin overlying the posterior superior spine, and by two straight lines drawn from these dimples to the midline of the spinal column at the level of the fourth lumbar vertebra. The importance of visualizing this region is to help one ascertain the exact location of the sacral cornua, which lie near the gluteal cleft dorsally and which must be located prior to injecting the anesthetic agent into the caudal canal. The dimples in the skin over the dorsum of the sacrum serve to indicate the close proximity of the posterior superior spines of the ilia. After having observed the posterior contour of the sacrum and pelvis, one should utilize palpation to locate the exact sites for injection. Much too frequently attempts are made to perform caudal transsacral block by palpation and various other tactile manipulations without adequately looking at and visualizing the topography of the sacrum and pelvis.

Another suggestion which will facilitate, among other things, both the introduction of the caudal needle and the insertion of needles into the transsacral foramina on the left side is to place the left side (assuming the anesthetist to be right-handed) of the patient's head against the pillow. The right side of the patient's head is placed against the pillow when needles are inserted into the right sacral foramina. This maneuver definitely helps to relax the erector spinae muscles of the back on the side on which one is working and allows easier introduction of the needles. In addition, the feet should be turned toward each other; in the prone position this procedure relaxes the gluteal muscles and greatly facilitates introduction of the caudal needle.

*Caudal Block.*—The skin over the sacrum and adjacent region is prepared surgically. A sterile towel is placed across the buttocks at about the upper third of the gluteal cleft. A sterile drape, sufficiently long to cover the patient, with a perforation 10 inches (25 cm.) in diameter, is placed over the back so that the opening in the drape exposes the sacrum. The sterile equipment required for caudal transsacral anesthesia consists of the following: (1) a syringe, (2) two 80 mm. needles, (3) four 50 mm. needles, (4) one wheel needle 20 mm. in



length, (5) one 80 mm. caudal needle, (6) one 120 mm. caudal needle, (7) one 5 cc. ampule of 20 per cent solution of metycaine or procaine, (8) one 3 ounce porcelain cup, (9) one towel clip, (10) forceps, (11) one 1 cc. ampule of epinephrine hydrochloride (1:2600), and (12) towels and drape sheet.

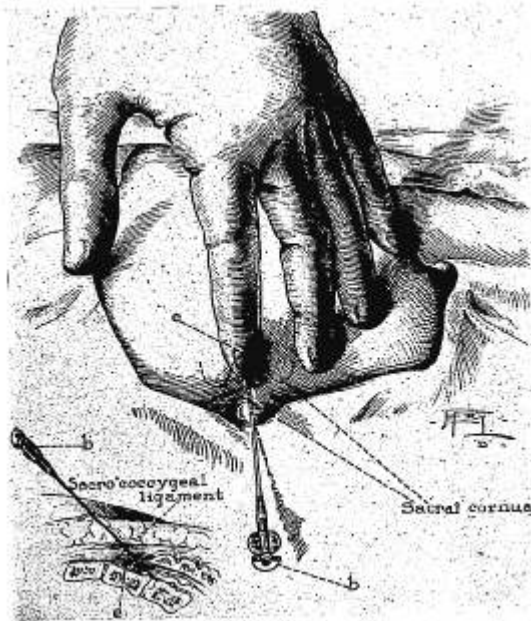


FIG. 6. Sacral block anesthesia, showing position of left hand; *e*, position of index finger in relation to sacral cornua, and *b*, introduction of 50 mm. needle through skin, subcutaneous tissue and sacrocoxygeal ligament. (From Lundy, J. S., and McCuskey, C. F.: Sacral Anesthesia in Operations on the Rectum, *Atlantic Med. J.* 30: 14-20, 1926.)

Ordinarily a 1 per cent solution of metycaine with epinephrine is preferred to a 1 per cent solution of procaine for sacral block anesthesia because anesthesia is established faster and lasts longer, and clinically there is apparently no more toxic effect than with procaine.

The method of locating and raising the initial skin wheal is as follows: The index finger of the left hand is placed on the sterile towel beneath the drape sheet and the tip of the coccyx is located by gentle palpation, the sterile towel preventing contamination of one's glove while locating the coccyx. The thumb of the left hand now is per-

pendicular to the sacrococcygeal joint and, by simultaneously keeping the index finger on the coccyx and palpating the bony structure of the sacrum in this region with the tip of the thumb, the two cornua of the sacrum usually can be felt. After identification of the sacral cornua with the thumb, the left hand is placed flat on the dorsum of the sacrum in such a manner that the index finger can feel the cornua and also the slight depression between them over which is stretched the sacrococcygeal membrane (Fig. 6). This depression between the cornua marks the sacral hiatus, which is the opening into the caudal canal.

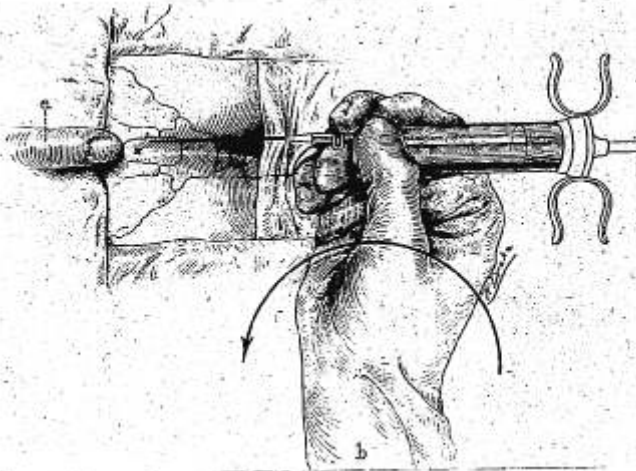


FIG. 7. Sacral block anesthesia: *a*, position of left index finger in relation to sacral hiatus; *b*, method of holding syringe and needle prior to introduction of needle through sacrococcygeal ligament. (From Lundy, J. S.: A method for Producing Block Anesthesia of the Sacral Nerves, *Am. J. Surg.* 4: 262-270, 1928.)

Occasionally, in thin persons, two sets of cornua may be felt, one set being slightly below the other; in such cases one must be extremely careful to select the cornua which have the depression between them only toward the distal end. In most instances the upper set of cornua, if two sets are palpable, should be chosen. With the tip of the index finger of the left hand resting in the depression between the cornua, a small skin wheal is raised about  $\frac{1}{4}$  inch (0.6 cm.) below the finger tip.

A 50 mm. needle, also attached to the syringe, is introduced through the skin wheal and advanced through the sacrococcygeal membrane into the sacral hiatus at an angle of approximately 45 degrees (Fig. 7). This needle now should be in the caudal end of the sacral canal, and

5 cc. of a 1 per cent solution of metycaine is injected slowly. The syringe is then detached, the needle remaining in situ. This 50 mm. needle serves as a guide for the introduction of the caudal needle, and it should not be removed until the latter is ready to be inserted.

Most difficulties in inserting the caudal needle arise because the initial skin wheal was located improperly, being either too high or too low and not in the midline. The caudal needle (80 mm. in length

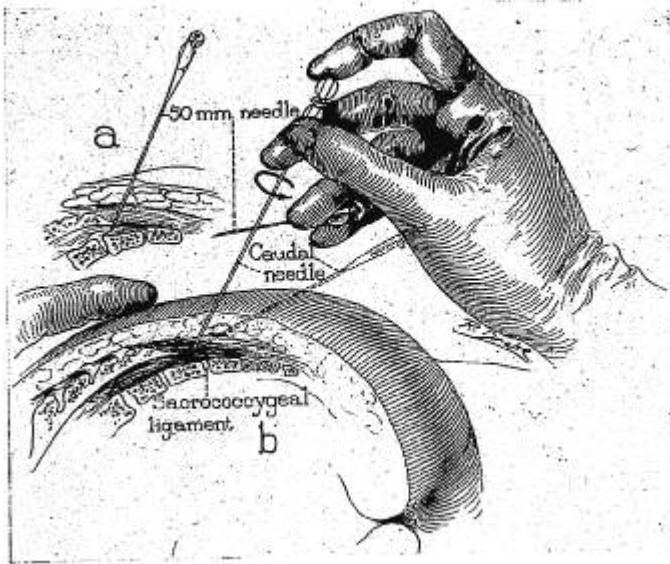


FIG. 8. Sacral block anesthesia: *a*, position of 50 mm. needle; *b*, method of removing 50 mm. needle with ring and little fingers of right hand, with subsequent introduction of caudal needle. (From Lundy, J. S.: A Method for Producing Block Anesthesia of the Sacral Nerves, *Am. J. Surg.* 4: 262-270, 1928.)

unless the patient is obese) is held between the thumb and middle finger of the right hand, the index finger of the right hand holding the stylet. The index finger of the left hand is placed between the sacral cornua again, and the ring finger and little finger of the right hand withdraw and drop the 50 mm. needle in such a way that the anesthetist does not have to look away and lose perception of the angle at which the needle must be inserted in order to enter the caudal canal (Fig. 8). The caudal needle then is inserted through the same perforation made by the 50 mm. needle, the bevel being kept upward until bone is contacted (Fig. 8). It then is rotated 180 degrees, and its hub is depressed

slightly so that it can be advanced through the sacrococcygeal membrane into the caudal canal (Fig. 8). When bony resistance is encountered at points deep in the caudal canal, the needle is given a half turn and advanced a little further, the rotation of the needle bringing its bevel against the bony obstruction so that the needle will override it.

The left index finger should be held in its position between the cornua in order to make sure that the needle enters the caudal canal and does not slide on top of the sacrum. The needle should not be advanced in the caudal canal beyond the level of the second sacral foramen, the distance of which can be ascertained by withdrawing the stylet and measuring on the skin surface. When one is reasonably certain that the needle is within the canal, the stylet is removed and an injection of 10 cc. of a 1 per cent solution of metycaine with epinephrine is made slowly after first carefully aspirating. The fluid should be injected easily. If resistance is encountered, one should palpate the dorsum of the sacrum to see whether any swelling occurs, which obviously would indicate that the needle was not in the canal, or else one should turn and withdraw the needle slightly. Careful aspiration prior to injection is extremely important since it is possible to make an intravenous or subarachnoid injection if the point of the needle happens to be in a certain position.

Occasionally, when the stylet of the caudal needle is removed or when one is aspirating, blood is observed. This indicates traumatization of the plexus of veins which occupies the caudal canal and means that any subsequent injection of anesthetic solution must be done slowly and intermittently, making frequent changes in the location of the point of the needle by alternately advancing and withdrawing it. Rotation of the needle through a half circle is an added precaution because this maneuver will change the relation of the bevel of the needle to the lumen of any vein which may be close by and prevent its penetration. Aspiration of spinal fluid is a rare occurrence and one that will occur usually only when the caudal needle is advanced beyond the level of the second sacral foramen. In the event it does occur, however, one should not inject more than 5 or 10 cc. of a 1 per cent solution of metycaine with epinephrine because spinal anesthesia may result. The injection of 30 cc. of a 1 per cent solution of metycaine with epinephrine when the dural sac has been punctured might produce serious results.

A second injection of 10 cc. of a 1 per cent solution of metycaine with epinephrine is made shortly after the original injection of 10 cc. has been made. The total amount of solution in the caudal canal, including the 5 cc. injected through the 50 mm. needle, is then 25 cc. When the anesthetic solution is being injected into the caudal canal, the patient may experience a transient pulling sensation down the back of the legs or a sense of pressure in the sacrum. If the solution is injected too rapidly, respiration increases in depth and sometimes the patient may complain of an occipital headache. Furthermore, nausea

may occur as a result of rapid injection because of rapid absorption into the blood stream. After the caudal injection is completed, if one is not pressed for time, it is desirable to wait a few moments to allow extension of the caudal anesthesia so that the transsacral injection will be less painful.

If caudal block alone is used for anesthesia of the sacral nerves, at least 30 to 35 cc. of 1 per cent solution of metycaine with epinephrine must be injected and the solution allowed to penetrate the nerve trunk thoroughly for thirty or forty minutes. Satisfactory anesthesia for operative purposes can be expected in no more than 50 or 60 per cent of the cases, and one should be prepared to carry out posterior transsacral block if necessary. In certain cases so-called high caudal block may be utilized. For this procedure 60 to 80 cc. of a 1 per cent solution of metycaine with epinephrine is injected slowly over the course of twenty-five to thirty minutes. The resulting anesthesia using this larger amount of solution is variable, but the scheme may be tried if one is not equipped to perform transsacral anesthesia in addition. Satisfactory anesthesia can be established in a high percentage of cases by blocking the second sacral nerve, bilaterally, along with the injection of the caudal canal.

*Transsacral Block.*—The most satisfactory bony eminences which can be palpated near the upper margin of the sacrum are the posterior superior spines of the ilia. In obese patients the skin directly overlying the spines is dimpled and, depending on the amount of fat present, this determines whether or not the spine can be felt easily. It should be emphasized that light palpation should be used to feel the posterior iliac spines, because firm pressure in many instances may reveal other bony points along the ilium which actually are not as superficial and only cause confusion. The posterior sacral foramina lie in a straight line on each side of the sacrum, but they are not always parallel to the midline of the sacrum (Fig. 9). In women, the second sacral foramina are usually farther from the midline of the sacrum than in men. The third and fourth foramina usually are closest to the midline of the sacrum in both sexes. In other words, the sacral foramina in women actually form a “V” in relation to the sacral hiatus, whereas in men they are practically parallel to the midline of the sacrum.

After the posterior superior iliac spine has been located, skin wheals are raised over the second, third and fourth sacral foramina, which underlie a line about a fingerbreadth lateral to the midline of the sacrum at the following intervals: the second at a point about 1.5 cm. mesial and 1 cm. caudal from the posterior superior iliac spine, the third about a fingerbreadth below the second, and the fourth a fingerbreadth below the third (Fig. 9). It is helpful to make the skin wheals slightly lateral to the calculated sites and directly over the sacral foramina because, if the needles are inserted through wheals which are too close to the midline of the sacrum, the skin overlying the sacrum cannot be retracted

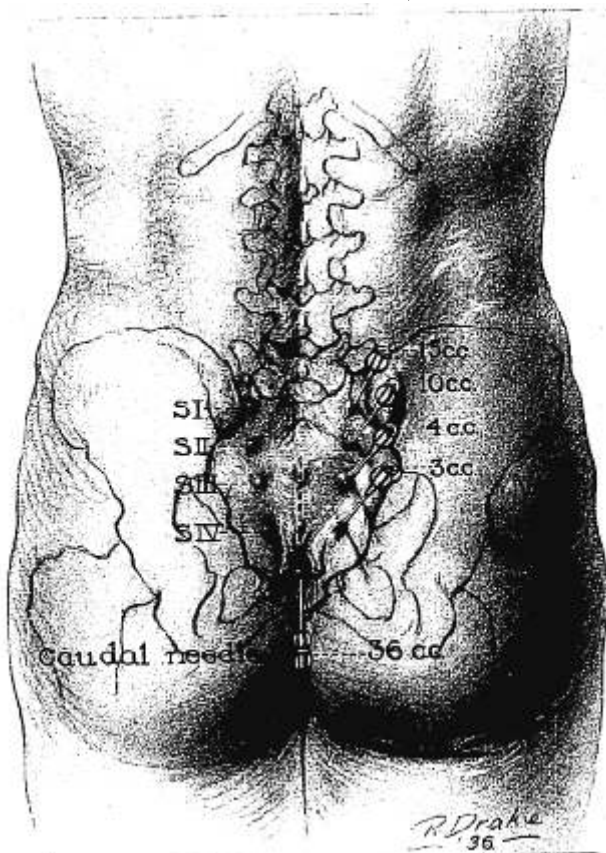


FIG. 9. Sacral block anesthesia, showing soft tissue of buttock and bony skeleton of the pelvis. The caudal and transsacral needles have been introduced through primary skin wheals into the various foramina, including the caudal canal.

laterally as well as it can be moved toward the midline. The mechanical stress on the needle is apparent when the skin is stretched in order to bring a given wheal into a position so that the needle can be advanced into a foramen. The breakage of a needle in a sacral foramen always is disconcerting, and one must keep in mind this hazard and avoid all unnecessary lateral tension or traction when introducing such needles. It is rarely necessary to inject the solution into the fifth sacral foramen,

which lies 1 cm. lateral to the site of the initial wheal, because the caudal injection usually anesthetizes the fibers of the fifth sacral nerve. Furthermore, the fifth sacral foramen is not always patent or present, and one should not attempt such an injection if bony resistance is felt in a rather wide area.

Having completed the injection of the left sacral foramina, the anesthetist should instruct the patient to place the right side of his head against the pillow. While he is doing this, the anesthetist should place his hand on the lumbar region of the back in order to prevent the patient from raising his hips and attempting to shift his weight on the table. This precaution will prevent several transsacral needles from being broken off in the foramina, since the second, third and fourth transsacral needles, as well as the caudal needle, are still left in position until block of the second, third and fourth posterior sacral nerves on the right is completed (in a manner similar to that on the left side).

The anesthetist should stand near the patient's hip on the side on which the injection is being made. These positions will facilitate the technical production of bilateral transsacral anesthesia. In the average case the second sacral nerve on the right is the last one to be injected. The sequence of injection, after the caudal needle is placed, is to anesthetize the fourth, third and second sacral nerves, respectively, on the left side and then to progress in the same fashion on the right side. The average amount of 1 per cent solution of metycaine with epinephrine injected into the foramina is as follows: 2 cc. in each fourth sacral foramen, 3 cc. in each third, and 10 cc. in each second sacral foramen.

Occasionally, anesthesia may be established slowly on one side or the other near the anterior margin of the anus or on the perineum. In that event one should make sure that the second sacral nerve on the affected side has been anesthetized and also inject the first sacral nerve of the same side, the latter being located in its foramen about 1.5 cm. mesial and 1 cm. above the posterior superior iliac spine (Fig. 9). The first sacral foramen is somewhat larger than the others, but since it is surrounded by a thicker bony edge, the injection usually is a little more difficult owing to the fact that the needle point impinges on bone more readily before it can be directed into the foramen. Ten cubic centimeters of 1 per cent solution of metycaine with epinephrine is injected into the first foramen when it is located. When the needles are placed accurately in the respective foramina, they should be in a straight line and equidistant from each other and bear the same angle of inclination (approximately 90 degrees) to the caudal needle (Fig. 9). In addition, the needles should not be advanced more than 0.5 cm. within each individual foramen, because a deeper location of the needle point in the foramen will not allow the injected anesthetic solution to come in contact with the posterior branches of the sacral nerves.

It rarely happens that the caudal canal cannot be located, but if this should be the case, one may inject twice the usual amount of solution into each sacral foramen with equally good results.

#### REGIONAL ANESTHESIA FOR OPERATIONS ON THE LOWER EXTREMITIES (4)

For operations on the knee, lower part of the leg and foot, regional methods of anesthesia are easier to perform than for operations on the thigh and hip. The multiplicity of nerves supplying the thigh and hip has made intraspinal anesthesia in most instances the procedure of

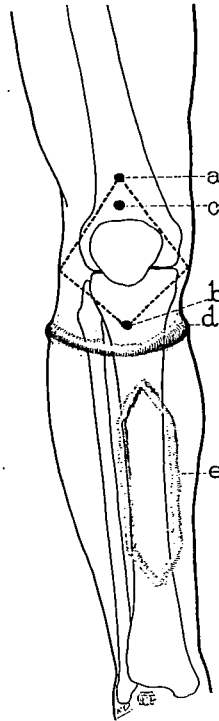


FIG. 10. Block anesthesia for operations on the knee: A triangular intradermal injection is made around the knee from points *a* and *b*. A deep injection from skin to bone is made at *a* and *b* and at points just lateral to the knee joint. At *c*, a needle is introduced from skin to bone and toward the knee joint and some of the anesthetic solution diffuses into and around the joint and subpatellar bursa. For certain operations below the knee, a bracelet type of block is sometimes helpful, as shown in *d*. Field block *c* shows an area blocked off on the anterior surface of the tibia for such operations as removal of a bone splint. This injection (intradermal) is made from skin to bone as illustrated.



choice. It should be remembered that it usually will require a relatively large quantity of local anesthetic solution (procaine, metycaine, and so forth) to anesthetize the hip region, for example, and it is felt that the small quantity of procaine which would be needed to produce satisfactory subarachnoid anesthesia would be no more toxic to the patient than the large amount of anesthetic solution injected locally near the site of operation.

*Block Anesthesia for Operations on the Knee.*—For operations on the knee joint, a diamond-shaped area is blocked off on the dorsal surface around the knee by injecting a 0.5 per cent solution of procaine with epinephrine from skin to bone from points *a* and *b* (Fig. 10) to points just lateral to the knee joint. The needle is introduced through the skin and advanced perpendicularly toward the knee joint and an injection of the same solution is made which will diffuse into and around the joint

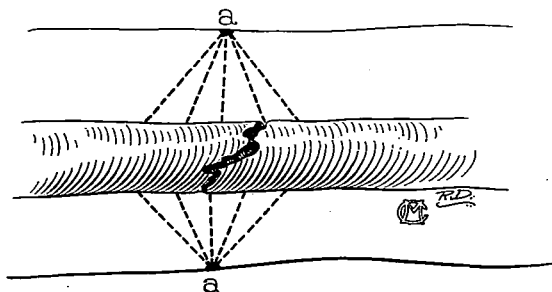


Fig. 11. Method of local anesthesia for treatment of old fractures.

and subpatellar bursa (Fig. 10). Ten to 15 cc. of solution is sufficient to inject beneath the patella.

For the treatment of old fractures of the tibia and fibula, the infiltration must be carried down to the periosteum on both sides of the fracture and circumferentially about the fractured bone. A 0.5 per cent solution of procaine with epinephrine is used for the infiltration anesthesia between skin and bone, but a 1 per cent solution (20 to 30 cc.) of procaine with epinephrine is injected against the periosteum near the site of the fracture (Fig. 11). In the case of recent or acute fractures, and in the presence of a hematoma, a 2 per cent solution of metycaine is suggested. When the needle has entered the hematoma (which can be determined by aspirating some blood from it), the solution should be injected slowly; it will disperse through the blood clot and provide anesthesia for the reduction of the fracture.

The anterior surface of the tibia is used as a source of many bone grafts and the removal of bone from this region can be accomplished

readily under anesthesia. An area sufficiently large, depending on the size of the bone graft, is blocked with 0.5 per cent solution of procaine with epinephrine, injected intradermally, subcutaneously and along the periosteum of the tibia (Fig. 10).

#### OPERATIONS ON THE FOOT

The nerve supply of the whole foot can be interrupted by using a bracelet block at the ankle and by injecting a 1 per cent solution of procaine with epinephrine on the surface of the posterior tibial and an-

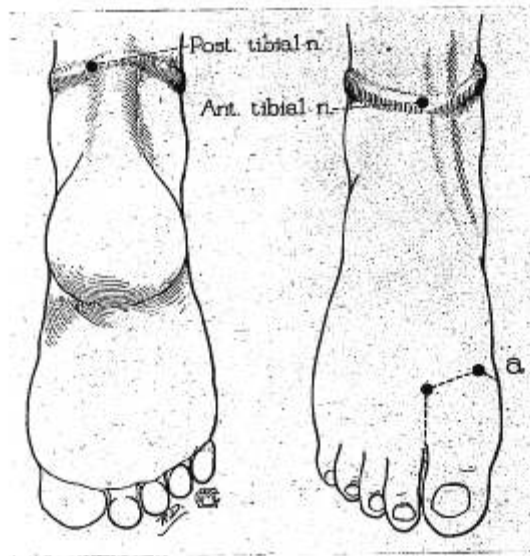


FIG. 12. Block anesthesia for operations on the foot, showing sites of injection for posterior and anterior tibial nerves and field block of great toe. (From Lundy, J. S.: The Technic of Nerve Blocking for Various Orthopedic Operations, Proc. Staff Meet., Mayo Clin. 4: 77-79 (Mar. 6) 1929.)

terior tibial nerves (Fig. 12). An attempt should be made to produce paresthesia with the needle before the solution is injected.

Local anesthesia for operations on the digits is very satisfactory, and for bunion operations block anesthesia of the great toe usually is preferred to all other forms of anesthesia, chiefly because anesthesia is easily established and vascular oozing is minimal. The nerve supply of the great toe can be interrupted by means of an L-shaped injection. A skin wheal is raised over the proximal end of the first interosseous space

on the dorsal surface of the foot, and an injection of 1 per cent solution of metycaine or procaine is made from the skin of the dorsal surface to the plantar surface of the foot. The injection then is carried intradermally to the inner side of the foot, and two injections are made from the skin perpendicularly toward the head of the first metatarsal bone. Twenty to 30 cc. of 1 per cent solution of metycaine or procaine is sufficient to produce satisfactory anesthesia. A similar type of injection is used for other digits of the foot, except that the second, third and fourth digits must be blocked on each side in the intervening web between the toes rather than in just one space between the toes. The deep injection toward the plantar surface and toward the heads of the metatarsal bones is identical with the block described for the great toe. Less anesthetic solution is required to anesthetize the smaller toes.

#### REFERENCES

1. Labat, Gaston: *Regional Anesthesia: Its Technic and Clinical Application*. Philadelphia, W. B. Saunders Company, 1922. 496 pp.
2. Lundy, J. S.: A Method for Producing Block Anesthesia of the Sacral Nerves, *Am. J. Surg.* 4: 262-270 (Mar.) 1928.
3. Tuohy, E. B.: Local Anesthesia. In Lewis, Dean: *Practice of Surgery*. Hagerstown, Md., W. F. Prior Company, Inc., 1938, vol. 1, chap. 4, 81 pp.
4. Lundy, J. S.: The Technic of Nerve Blocking for Various Orthopedic Operations, *Proc. Staff Meet., Mayo Clin.* 4: 77-79 (Mar. 6) 1929.

---

#### COMING EXAMINATION

AMERICAN BOARD OF ANESTHESIOLOGY: Written, Part I. Various cities throughout the United States, November 1, 1941. Final date for filing application is August 4, 1941. See., Dr. Paul M. Wood, 745 Fifth Ave., New York, N. Y.

---

Physician-anesthetists desiring certification whose practice is not limited exclusively to anesthesiology should obtain information from the Committee on Fellowship of the American Society of Anesthetists, Inc., E. H. Eliasberg, M.D., Secretary, 275 Central Park West, New York City.

If the practice of physician-anesthetists is limited exclusively to the specialty, they may be eligible for certification by the American Board of Anesthesiology, Inc., Paul M. Wood, M.D., Secretary, 745 Fifth Avenue, New York City. It is suggested that possible applicants read the statement of the American Board of Anesthesiology, Inc., in the *Journal of the American Medical Association*, which statement is appearing in alternating current issues.