

## SUPRASCAPULAR NERVE BLOCK \*

H. M. WERTHEIM, M.D., F.A.C.S., AND E. A. ROVENSTINE, M.D.

*New York, N. Y.*

THE shoulder is a frequent site of intractable pain. Such convenient diagnoses as subdeltoid bursitis or arthritis are frequently confirmed, but often the pathology is not exactly determined, and more often accurate determination as to etiological factors escapes diagnostic acumen. Many painful shoulders are self-limiting in their course. However, during the acute phase, pain is often so intense that the patient is totally disabled and more than simple immobilization and sedation are needed. An accessory method to alleviate or relieve the pain is desirable. Frequently only the relief of intense pain will permit other indicated therapeutic adjustments such as traction, manipulation and massage to be adequately applied. An analgesic block of the suprascapular nerve at the lesser scapular notch is the procedure of choice as a supplement in the treatment of this type of disability. This nerve block is also useful as an adjunct in the treatment of chronic pain of the shoulder.

The suprascapular is a peripheral nerve composed of motor, sensory and sympathetic elements. Its sensory components form a vital pathway for pain fibers from the shoulder joint, acromioclavicular joint and the peri-articular structures about the shoulder joint. The articular and peri-articular branches leave the nerve in the supra- and infraspinatous fossae so that to obtain interruption of the sensory impulses from the involved structures the nerve must be blocked before division takes place. There are no branches of this nerve to the shoulder joint given off before it passes through the lesser scapular notch.

### ANATOMY

The suprascapular nerve arises from the upper trunk of the brachial plexus which is formed by the fifth and sixth cervical nerves. It courses laterally and caudad under the posterior belly of the omohyoid muscle lying anteriorly to the trapezius, and then under the superior scapular ligament medial to the transverse scapular vessels. It then passes under the supraspinatous muscle and around the lateral border of the spine of the scapula beneath the inferior transverse scapular ligament to the infraspinatous fossa. Branches are distributed to the supra- and infraspinatous muscles, articulation and peri-articular structures of the shoulder joint and the acromioclavicular joint. A small segment

\* From the Division of Surgery, Department of Anesthesia, New York University College of Medicine, New York, N. Y.

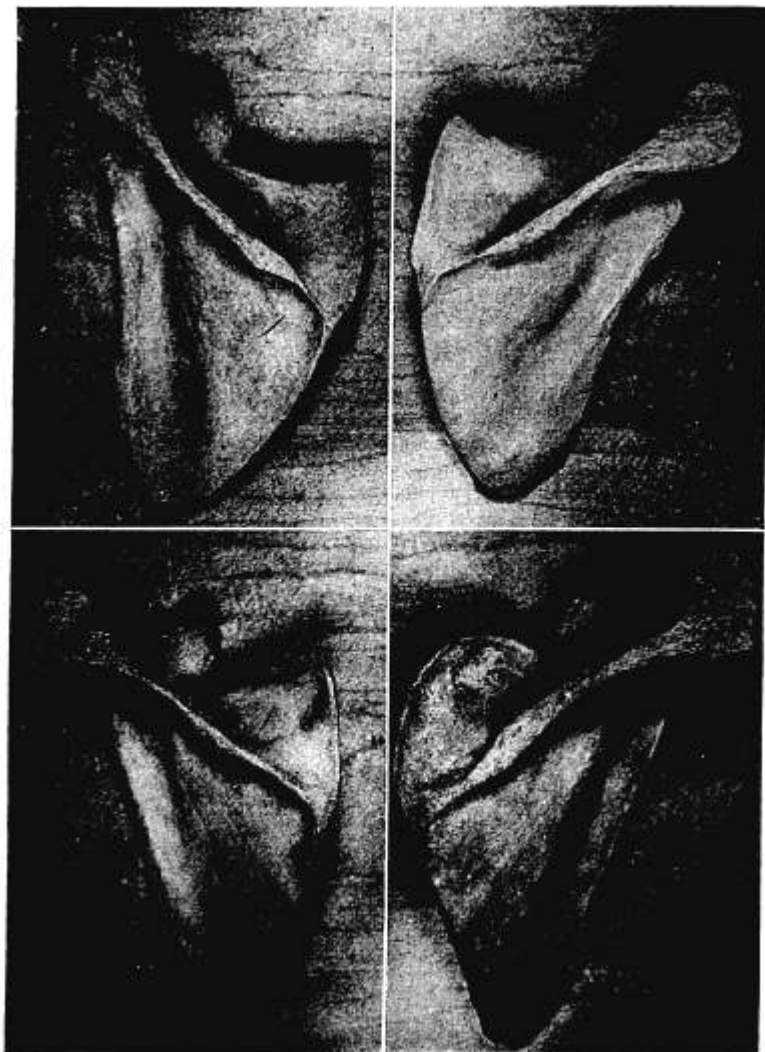


FIG. 1. Photographs of scapulae illustrating the variation in size and contour of supra-scapular notch.

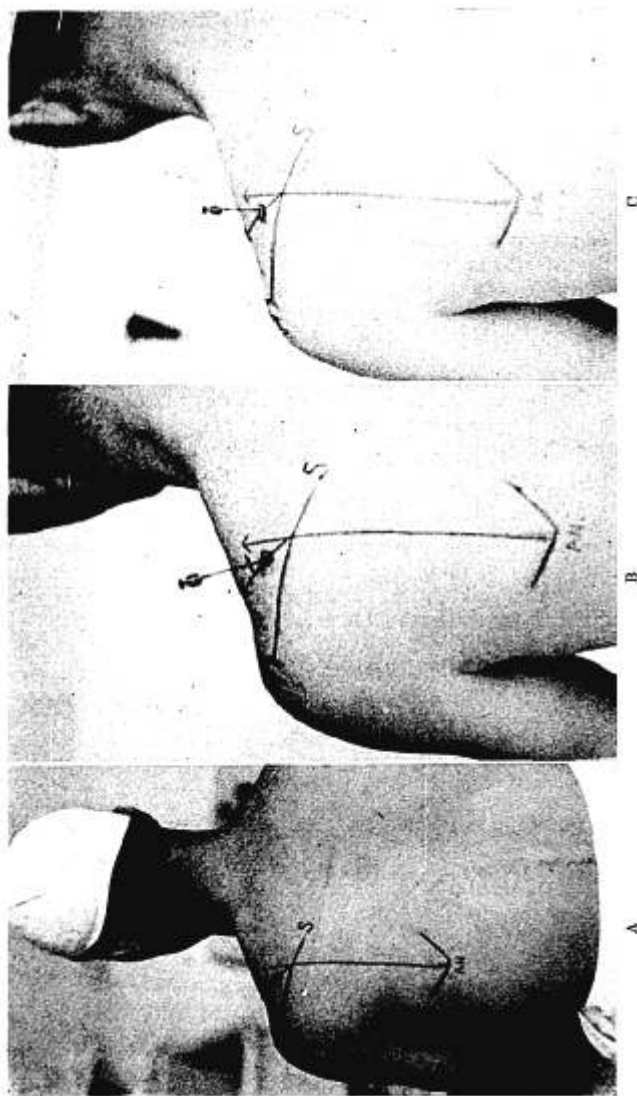


FIG. 2. The superficial landmarks outlined on the skin for suprascapular nerve block. (a) Skin-marking. (b) The needle in contact with scapula. (c) The needle placed in the suprascapular notch.

of skin at the apex of the shoulder derives its innervation from this nerve.

The lesser scapular notch in the adult is semi-circular, with an average width of  $1\frac{1}{4}$  cm. It is formed by a deficiency of the most lateral extremity of the superior border of the body of the scapula. The lateral boundary is formed by the medial border of the base of the coracoid process. The superior transscapular ligament, which occasionally may be ossified, converts the notch into a foramen. Considerable variation in the size and contour of the notch has been observed in various scapulae. Common variations are shown in Figure 1. It should be noted that the inferior angle of the scapula is in the same perpendicular plane as the lesser scapular notch, and that the distance of the notch from the base of the spine of the scapula varies slightly.

### TECHNIC

To block the suprascapular nerve the patient is placed in the sitting position with the upper extremities hanging at the sides. The hands may rest on the thighs. The head and shoulders are slightly flexed. (See Fig. 2.)

The superficial landmarks are determined and outlined with a skin-marking pencil. First, a line is drawn to mark the upper edge of the base of the spine of the scapula extending from the tip of the acromion to the medial border of the bone. The inferior angle of the scapula is then traced on the skin. It is bisected and the bisector is drawn cephalad crossing the line which marks the base of the spine. The

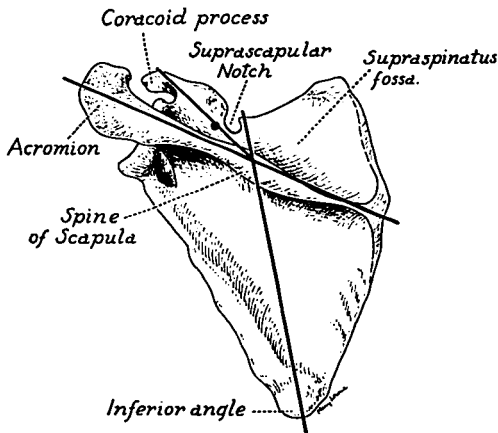


FIG. 3. The skin markings for suprascapular block drawn upon a scapula. The black dot to the left of suprascapular notch indicates the point where the needle is introduced.

upper outer triangle formed by the intersecting lines is also bisected. On this line a point  $1\frac{1}{2}$  cm. marks the site of introduction of the needle. (See Fig. 3.)

An analgesic wheal is raised, through which an  $80 \times 8$  needle, fitted with a recorder, is introduced so that the shaft is directed slightly downward and medially to make contact with the smooth surface of the supraspinatous fossa lateral to the notch above the suprascapular fossa. (See Fig. 2*b*.) In this position the needle will be in contact with the medial extremity of the base of the coracoid process. The recorder is then withdrawn 1 cm. from the skin surface and the needle is reintroduced medially until the point enters the notch. (See Fig. 2*c*.) Radiating paresthesias should accompany contact with the nerve, the maximum intensity of which occurs at the apex of the shoulder. The aspiration test will ascertain that the open end of the needle is not in a blood vessel.

For therapeutic purposes 5 cc. of a 2 per cent procaine or similar solution is injected. If the relief of pain follows within ten to fifteen minutes, then 5 cc. of an oil-analgesic solution (5 per cent intracaine in oil-Squibb) is injected without disturbing the needle. The analgesic effect from such an injection may continue from four to six weeks; usually sufficient time for the acute pathology to subside. If pain recurs after several weeks have elapsed due to chronicity of underlying disturbance, the same technic may be used but 2 cc. of 95 to 100 per cent alcohol is substituted for the oily solution.

477 First Avenue.

---

The program for the Section of Anesthesiology of the American Medical Association which will meet in Atlantic City, N. J., in 1941 is being prepared. Those who wish to offer papers for consideration should apply to Dr. John S. Lundy, Rochester, Minn., care of the Mayo Clinic, before October 31, 1941.

---

#### COMING EXAMINATION

AMERICAN BOARD OF ANESTHESIOLOGY: Written, Part I. Various cities throughout the United States, November 1, 1941. Sec., Dr. Paul M. Wood, 745 Fifth Ave., New York, N. Y.