

INTRASPINAL AMMONIUM SALTS FOR THE INTRACTABLE PAIN OF MALIGNANCY

BERNARD D. JUDOVICH, M.D., WILLIAM BATES, M.D., AND
KINGSLEY BISHOP, M.D.

Philadelphia, Pa.

In 1935 Judovich (1) reported the use of pitcher plant distillate (*Sarracenia purpurea*) as being of value in the treatment of certain forms of neuralgia. In 1939, Stewart, Hughes, Judovich and Walti (2) reported evidence that the activity of the pitcher plant was due to the NH_4 ion. Judovich then attempted the use of ammonium salts intrathecally for the intractable pain of malignancy.

In 1942, Bates and Judovich (3) published a preliminary report upon the use of this procedure as a method of therapy. A solution of either ammonium sulfate or ammonium chloride in 6 per cent solution (each cubic centimeter containing 60 mg.) was used. The total amount administered varied from 200-400 mg. of ammonium salt. This was a highly concentrated solution and it was necessary to dilute it freely with spinal fluid by means of barbotage in order not to have too high a concentration of the ammonium salts at any point within the intrathecal space. Too high a concentration of the ammonium salts at any point within the intrathecal space would affect all fibers, causing bowel, bladder and motor disturbance.

In the preliminary report, bowel, bladder and motor involvement was mentioned. This was thought to result from insufficient dilution of the ammonium salts, or perhaps from metastatic infiltration which caused a block, preventing rapid dissemination of the solution.

Since the original publication which included a series of 50 cases, we have knowledge of 6 cases of bowel and bladder involvement. This figure includes reports by others who have employed this method, as well as additional cases in our own series.

In an effort to eliminate bowel, bladder and motor effect following the intrathecal administration of the ammonium salts, our technic has been modified. Instead of depending upon barbotage as a means of diluting the ammonium salt solution, 50 cc. of spinal fluid is withdrawn. The ammonium salt solution is diluted with the spinal fluid, mixed, and the mixture is injected into the intrathecal space. This technic makes certain that there will be no unequal concentration of ammonium salt solution.

In addition, the dosage of the ammonium salt has been reduced to 200 mg. Thus, when diluted in 50 cc. of spinal fluid, each cubic centi-

meter of spinal fluid contains not more than 4 mg. of the ammonium salt. The hydrogen-ion concentration of the ammonium salt solution is adjusted to 7.2 with ammonium or sodium hydroxide, before ampouling and autoclaving.

The use of a spinal anesthetic of procaine before the injection has been eliminated. Although the procedure is severely painful without the procaine anesthesia, it was noted that spinal anesthesia plus the addition of the ammonium salt solution produced more complications than when the procaine anesthesia was omitted. Also, adequate premedication makes it unnecessary. Morphine and barbiturate premedication in heavy dosage eliminates most of the pain. The pain has been further reduced by the lowered dosage of 200 mg.

To determine the amount of preoperative medication one should take into consideration the doses of opiates to which the patient has previously been accustomed. In a patient who has not become addicted, $\frac{1}{4}$ to $\frac{1}{2}$ grain of morphine plus 3 grains of amytal may be administered. Atropine sulfate, $\frac{1}{16}$ grain, will be of aid in lessening nausea and vomiting. A sensation of burning pain and heat may follow the injection. Most of these reactions are controlled by the premedication.

Before attempting to apply this procedure, a proper evaluation of the patient's physical status should be made. If the symptoms appear to be visceral in nature the procedure should not be used. If, however, there are signs of root irritation; if the pain is aggravated by change in position, coughing and sneezing and is associated with tenderness, especially of segmental distribution, this type of therapy is considered favorable. Other signs and symptoms which suggest that spinal metastases are the cause of pain are further indications that the procedure will probably be of benefit. It was noted in the group of failures that in nearly all instances pain was not associated with tenderness of the sensory segments.

If the examination reveals that the disease process has already caused motor weakness or other neurologic disturbances, intraspinal therapy may hasten an impending paralysis. The degree and extent of pain and tenderness should be noted in all cases so that changes following treatment may be accurately evaluated. Before attempting any form of intraspinal therapy, the family should be notified of all possible complications, and written permission should be secured for the procedure.

We believe, at the present stage, that this form of therapy should be attempted only when the patient is suffering intractable pain which is not relieved by another form of therapy. Many of the results we have obtained, and many of those reported, have been excellent. When good results are obtained, the area of distribution is much wider than can be safely obtained with alcohol. However, at the present time, it must be considered a procedure with some degree of risk.

PROCEDURE

Premedication.—The patient is given 3 grains of amytal or seconal forty minutes before lumbar puncture. Sufficient morphine and $\frac{1}{2}$ grain of atropine sulfate is administered hypodermically twenty minutes before lumbar puncture. The bowels and bladder are emptied. Fluids are limited and the preceding meal is omitted.

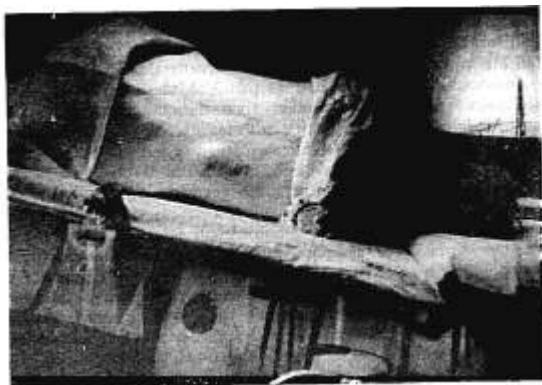


FIG. 1.—The table is inclined so that the head is kept well below the site of lumbar puncture. This position must be maintained throughout the procedure. Lifting the head may cause severe headache.

Technic.—The patient is placed on the side with the head down and the hips elevated. A lumbar puncture is performed at the proper level and 50 cc. of spinal fluid is removed. If there is difficulty removing 50 cc. of spinal fluid, a small amount of air may be injected to replace the fluid. The syringe is removed and the needle left in position. To the 50 cc. of spinal fluid is added 3 cc. of ammonium sulfate or ammonium chloride, each cubic centimeter containing 60–65 mg. (6–6.5 per cent solution). The solutions are well mixed, and the entire amount is reinjected into the intrathecal space. Care should be taken not to move the position of the needle when detaching and attaching the syringe. *The head should be kept well below the plane of the tapping site all during the procedure.* After the mixture of the spinal fluid and ammonium salt solution has been replaced, the patient is placed flat on the back, and kept in this position for an hour (twenty-four hours or longer if air has been injected), after which the bed may be levelled. The patient should be kept in bed for twenty-four hours to prevent postspinal headache. Further medication may be repeated as indicated during the next several hours.

The following group of cases were treated by the technic of diluting the ammonium salts in 50 cc. of spinal fluid.

Case 1.—A man (G. M.), age 55, had carcinoma of the prostate with metastases. The patient had pain through the lower back and at the site of a pathologic fracture in the left femur. There was a six months' history of pain so severe he had contracture of the leg and was bedridden. He could not be touched without screaming.

Five cubic centimeters (60 mg. per cubic centimeter) of the preparation of ammonium chloride in 50 cc. of spinal fluid was injected. No premedication was given.

There was a severe reaction, with nausea, vomiting, "burning," and headache which lasted for five hours. He had "drawing sensations" in the legs. Nurses often found him up walking on the pathologic fracture and he could not understand why he should not since he had no pain. After five months he still had relief from pain. At the end of that time the pain recurred. Following nephrectomy for hypernephroma the patient died.

Case 2.—A woman (P. S.), age 75, complained of pain in both legs and feet caused by advanced arteriosclerosis associated with diabetes. She also complained of low back pain. The patient was very uncooperative, probably because of cerebral arteriosclerosis.

Five cubic centimeters (60 mg. per cubic centimeter) of the preparation of ammonium chloride in 50 cc. of spinal fluid was injected intrathecally *without premedication*.

There was a severe reaction with nausea, vomiting, "burning," and headache. No further reaction occurred after this, and there was no relief of pain. The nerves were subsequently crushed surgically, also without relief, and the legs were eventually amputated.

Case 3.—A woman, age 45 (referred by Dr. A. Herman), had metastases in the spine from a carcinoma of the breast. The pain in the back and legs was excruciating. She was unable to turn in bed or move her legs. Previous treatment for her pain consisted of roentgen therapy, administration of opiates, and cobra venom. She obtained no relief from any of these therapeutic measures. She was admitted to the Graduate Hospital and given an intraspinal injection of 300 mg. of ammonium sulfate. Following this injection the patient obtained complete relief of the pain in the back and legs. The day after treatment she was able to walk about the ward. Relief of pain continued for seven months, until the time of her death.

Case 4.—A woman (B. P.), age 55, had severe pain in both legs and lower back from advanced sarcoma with metastases. The left buttock was twice its normal size due to extension of the lesion. She had a spinal cordoma which had begun to produce neurologic symptoms in both legs. Five cubic centimeters (60 mg. per cubic centimeter) of ammonium chloride in 50 cc. of spinal fluid was injected intrathecally. This was preceded by 100 mg. of procaine hydrochloride as a spinal anesthetic. Premedication consisted of barbiturates and morphine sulfate, $\frac{1}{4}$ grain, and scopolamine, $\frac{1}{150}$ grain. Nausea, vomiting, and some headache followed the injection. The immediate reaction of pain was not marked. Permanent loss of bowel and bladder control, and paralysis of the left leg developed. The original pain was relieved, but the end result "was not worth it."

Case 5.—A woman (N. M.), age 68, had an osteogenic sarcoma with metastases to the lungs. There was a pathologic fracture of the left femur. The site of fracture and the entire back, especially the lower portion, were very painful. The leg was held in flexion and could not be touched without the patient screaming. Three cubic centimeters of ammonium chloride (60 mg. per cubic centi-

meter in 50 cc. of spinal fluid was injected intrathecally. The ammonium chloride solution was adjusted to a pH of 7.2 with ammonium hydroxide. Premedication consisted of amytal, 3 grains, morphine sulfate, $\frac{1}{2}$ grain, and atropine sulfate, $\frac{1}{75}$ grain. The patient remained asleep on the premedication during most of the procedure. The immediate reaction was practically nil. The patient retched twice, with no other symptoms. The next day she was unaware that anything had been done, except that her pain was gone. Pain relief persisted for over a month, although the patient was in bad condition with advanced sarcomatosis, and had bed sores that stuck to the bedding. She died free of pain.

Case 6.—A woman (M. II., colored), age 66, had carcinoma of the rectum with metastases. There was pain throughout the lower back, associated with tenderness. A colostomy had been performed. The patient was addicted to morphine, taking $\frac{1}{4}$ to $\frac{1}{2}$ grain every four hours. Three cubic centimeters of ammonium chloride (60 mg. per cubic centimeter, pH adjusted to 7.2 with ammonium hydroxide) in 50 cc. of spinal fluid was injected intrathecally. Premedication consisted of morphine sulfate, $\frac{1}{4}$ grain, atropine sulfate, $\frac{1}{75}$ grain, intravenously just before injection. The immediate reaction was some nausea, followed by slight headache. The next day she had drawing sensations in the legs and she had quite a bit of discomfort for three days thereafter. At the last report she was feeling fine and had had no pain for over three weeks, at the end of which time she was started on malarial therapy. For over a month now there has been no complaint.

Case 7.—A man (F. K.), age 43, had tabes dorsalis. He complained of severe tabetic pain in the abdomen and legs. Four cubic centimeters of ammonium chloride (60 mg. per cubic centimeter, pH adjusted to 7.2 with ammonium hydroxide) in 50 cc. of spinal fluid was injected intrathecally. Premedication consisted of morphine sulfate, $\frac{1}{4}$ grain, atropine sulfate, $\frac{1}{75}$ grain, given intravenously just prior to injection. Immediate reaction was some nausea followed by slight headache. The next day he had drawing sensations in the legs, and he had quite a bit of discomfort for three days thereafter. At the last report he was feeling fine and had had no pain for over three weeks, at the end of which time malarial therapy was begun. For over a month now there has been no complaint.

Case 8.—A man (F. G.), age 43, had carcinoma of the rectum with metastases. He had had an abdominal perineal resection one year before examination. His complaint was severe pain in the lower back. The patient was very apprehensive. Three cubic centimeters of ammonium chloride (60 mg. per cubic centimeter, adjusted to a pH of 7.2 with ammonium hydroxide) in 50 cc. of spinal fluid was injected intrathecally. Premedication consisted of morphine sulfate, $\frac{1}{4}$ grain, atropine sulfate, $\frac{1}{75}$ grain, given intravenously just before the procedure. The immediate reaction was so severe that he could not talk for two hours. This was followed by complete relief of pain which lasted for two weeks. Then swelling in one leg developed due to lymphatic obstruction, which caused recurrence of pain. He was given a second injection in spite of the fact that we felt the outlook was not too hopeful. He obtained complete relief again which lasted for one month. At the end of this time he requested another injection. However, the patient was failing rapidly at this time, and the injection was not given.

Case 9.—J. B. (Service of Drs. A. A. Creecy and R. L. Kurman of the Elizabeth Buxton Hospital, Newport News, Va.) This patient is a colored male, 57

years of age, and was first seen in the hospital on February 16, 1941, complaining of frequency, nocturia, and dysuria. On examination, the prostate gland was found to be enlarged and hard. On April 19, 1941, transurethral prostatectomy was done. At this time, carcinoma of the prostate was diagnosed. The patient got along well until March 1942, when he started to complain of difficulty in voiding, dysuria, hematuria, and severe pain in the back. He was readmitted to the hospital on May 4, 1942, and had an orchidectomy on May 5, 1942. Roentgenograms at that time showed extensive metastatic lesions of the pelvis and spine. He was discharged on May 9, 1942, in good condition. He resumed his regular work at the shipyard and was well until June 1943. He complained of severe pain in the right hip and extremities. Roentgenograms of the extremities and hips revealed that the pain was caused by extensive metastasis. He was given 5 mg. of stilbesterol daily and was discharged on July 30, 1943, condition somewhat improved, with instructions to continue taking stilbesterol at home. Since his dismissal from the hospital, he was confined to bed most of the time and required morphine and codeine for relief of pain. He was readmitted to the hospital on September 22, 1943, and ammonium sulfate was injected intraspinally. The severe pain in his lower extremities was relieved. He had no reaction from the injection and was discharged on September 25, 1943, complaining only of a mild headache. At present, the patient complains of severe pain in the lumbar and thoracic spine, probably caused by metastasis of these regions.

The group of patients who were given the ammonium salts with the pH adjusted to 7.2, and who received heavy premedication instead of procaine anesthesia, had the minimum reaction of pain or complications. As a matter of fact no patients in the group thus treated had any bowel, bladder or motor complications. Although the treatment by this method of pain caused by cancer has not reached a completely satisfactory stage, these modifications have made the procedure less formidable. It is our opinion that the procedure as outlined is less dangerous and yields more satisfactory relief of pain than does intraspinal administration of alcohol.

In the preparation of the ammonium sulfate or ammonium chloride for intraspinal use, the adjustment of the pH should be done by means of an electric potentiometer. Chemically resistant alkali free glass should be used. Indicator paper with colorimetric standards is not as accurate and too high a pH may cause the liberation of free ammonia in the ampule.

In one reported case which developed bowel and bladder paralysis, analysis of the preparation showed that the contents had a pH of 11 and smelled strongly of free ammonia.

Although we cannot state that omitting the procaine anesthesia does away with bowel, bladder and motor effect, it is our impression, at the present time, that it appears to lessen the incidence of such reactions.

REFERENCES

1. Judovich, B. D.: Relief of Pain, *M. J. & Rec.* 141: 583-585 (June 19) 1935.
2. Stewart, W. B.; Judovich, B. D.; Hughes, J., and Walti, A.: Ammonium Chloride in the Relief of Pain, *Am. J. Physiol.* 129: 474 (May) 1940.
3. Bates, W., and Judovich, B. D.: Intractable Pain, *Anesthesiology* 3: 663-672 (Nov.) 1942.