

INTRASPINAL SEGMENTAL ANESTHESIA: A PRELIMINARY REPORT * †

MEYER SAKLAD, M.D., CLEMENT S. DWYER, M.D., SANFORD KRONENBERG, M.D.,
EDMUND NEVES, M.D. AND MORRIS SORKIN, M.D.

Providence, R. I.

Received for publication November 4, 1946

SERIOUS sequelae still result from intraspinal injections of anesthetic agents. The hazards of low blood pressure, respiratory paralysis and damage to the subarachnoid nerve elements, particularly the cauda equina, still exist. If it were possible to limit anesthesia to the operative field and to use anesthetic agents in more dilute solutions and in smaller doses, certain undesirable effects of spinal anesthesia might be avoided. It is the purpose of this paper to describe a new technic of spinal anesthesia in which the extent of sensory, motor and autonomic effects may be limited. This segmental anesthesia can be produced by dilute solutions of anesthetic drugs in very low dosage.

In 1932, Kirschner (1) described a technic for the production of an intraspinal segmental anesthesia. With the patient in lateral head-down position, the spinal fluid in the lower end of the dural canal was withdrawn and replaced by air. A hypobaric nupercaine solution was floated on the spinal fluid beneath the air. Further injections of air would move the anesthetic agent cephalad. Phillipides (2) modified this technic by omitting the injection of air. Fay and Gotten (3) were able to obtain segmental anesthesia by using two needles, one in the lumbar subarachnoid space and the other in the cisterna magna. Vehrs (4) and others obtained segmental anesthesia by doing high spinal punctures.

With the advent of the catheter technic for fractional administration of drugs for spinal anesthesia and with the knowledge of the efficacy of dilute solutions, a more satisfactory method of segmental spinal anesthesia has been evolved.

TECHNIC

The patient is placed in a lateral decubitus position with the table horizontal. A spinal puncture is performed at the second or third lumbar interspace with a 16 gauge Huber-pointed needle. The opening of the needle is in proper position to point a catheter passing through

* Read before the New England Society of Anesthesiologists, Boston, Mass., September 17, 1946.

† From the Department of Anesthesia, Rhode Island Hospital, Providence, R. I.

it in a cephalad direction when the notch in the hub is turned toward the head of the patient. A 1:2000 solution of pontocaine hydrochloride is prepared by diluting 0.5 cc. of 1 per cent pontocaine with 9.5 cc. of spinal fluid. A 3½ French Tuohy continuous spinal catheter, graduated in 1 and 5 cm. markings, containing a soft stainless steel stilet, is inserted into a spinal needle. At times, difficulty is encountered in passing the catheter beyond the tip of the needle. By steadying the catheter with one hand and slightly withdrawing the

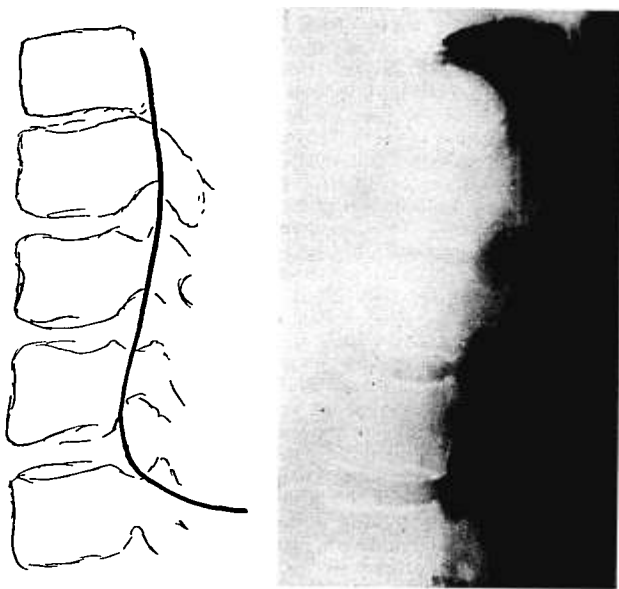


FIG. 1. Catheter properly placed.

needle with the other, the catheter can be advanced with ease. Occasionally paresthesias are elicited. If there is resistance to the passage of the catheter through the subarachnoid space, force should not be used. The catheter is gently pushed cephalad until it has been inserted a distance of 25 to 35 cm. as measured at the hub of needle (fig. 1). The length of catheter within the subarachnoid space is determined by subtracting the length of the needle (9.5 cm.) from this figure. The needle should not be rotated with the catheter in place, and no attempt

should be made to withdraw the catheter once it has passed through the tip of the needle. The sharp edge of the Huber point may sever the catheter or shave off pieces from its side unless the needle is first removed from the patient's back. After removal of the needle the stilet is withdrawn from the catheter, and a 10 cc. syringe, containing the pontocaine solution, is attached to the catheter by a snug-fitting needle. The catheter is fastened to the skin by adhesive tape. The patient is turned supine, and the syringe is brought up behind his shoulder. In order to prevent a back-flow of spinal fluid into the syringe, a piece of adhesive tape is fastened along the barrel and piston.

An initial dose of 2 to 4 cc. of the pontocaine solution (1 to 2 mg.) is injected and the levels of anesthesia determined. If the catheter has been properly placed, anesthesia develops rapidly with sharp lines of demarcation. Additional injections of 1 or 2 cc. are made if anesthesia is inadequate. The solution leaves the tip of the catheter with considerable force, and a rapid rate of injection will cause wider spread of the agent, with consequent dilution. Slow injection provides greater assurance that the concentration of pontocaine at the desired level within the subarachnoid space will more nearly approach that of the solution in the syringe. Thus, an almost true volumetric displacement is obtained. Injections of 0.5 to 1 cc. (0.25 to 0.5 mg.) at thirty minute intervals adequately maintain anesthesia during long operative procedures. Additional doses are given when an indication exists, such as when relaxation for closure can be improved or when visceral sensation is annoying to the patient. An attempt is made, however, to distinguish between discomfort or pain arising in the operative field and restlessness resulting from inadequate premedication, oxygen want, position or nausea. Although we recognize the frequent need for complementary or supplementary agents during spinal anesthesia, we have purposely premedicated these patients lightly and have given minimal quantities of drugs during the operation to evaluate the action of intraspinal segmental anesthesia more accurately.

The operating table is level during induction of anesthesia and throughout the operation unless a change is required for the surgical procedure. No special precautions are necessary to prevent the spread of the agent cephalad since the solution is nearly isobaric. From the standpoint of technic, we do not hesitate to place the patient in steep Trendelenburg position at any time. An intravenous infusion is started at the ankle after the patient is warned that he will feel a needle prick. The upper and lower limits of the anesthetized area are repeatedly determined during the operation by pinching the skin with an Allis clamp to demonstrate loss of sensation in segmental dermatomes. A descending upper level indicates that an additional injection of pontocaine is necessary. Persistent motor control of the lower extremities is demonstrated by having the patient move his toes or feet and raise his knees against the hand of the anesthetist.

RESULTS

This preliminary report includes our first 24 cases of intraspinal segmental anesthesia. In all of these the anesthesia was given for abdominal surgery. In 20 cases anesthesia was satisfactory. In two cases it was necessary to supplement with nitrous oxide-oxygen because of visceral sensation. Four cases were technical failures owing to faulty placement of the catheter. In one of these the catheter was curled upon itself within the subarachnoid space (fig. 2), and in another

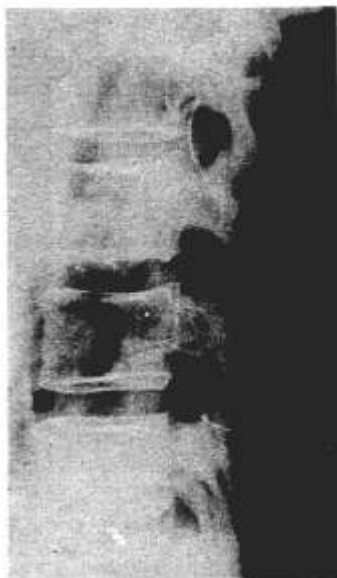
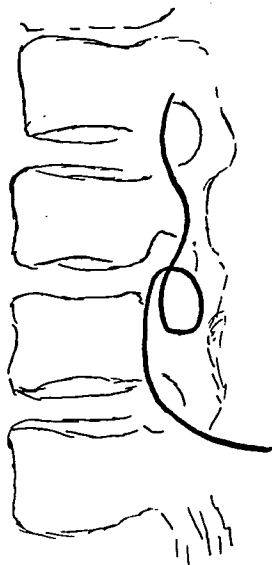


FIG. 2. Improper placement of catheter. The catheter was inserted without stilet. It has curled upon itself and has not advanced sufficiently far cephalad for satisfactory anesthesia.

the tip of the catheter had turned and was directed caudad (fig. 3). These catheters had been inserted without stilets. We now employ fine, stainless steel stilets to make certain that the catheters will pass directly cephalad within the subarachnoid space. In the third case, although roentgenologic examination was not made, it was believed that the catheter had not been advanced for a sufficient distance. The

fourth failure resulted from the inadvertent use of an ordinary ureteral catheter in place of the Tuohy catheter. The ureteral catheter has three lateral openings near its tip, whereas the Tuohy catheter has a single hole located at its extreme end. The latter provides a directional flow (cephalad) of the injected anesthetic solution.

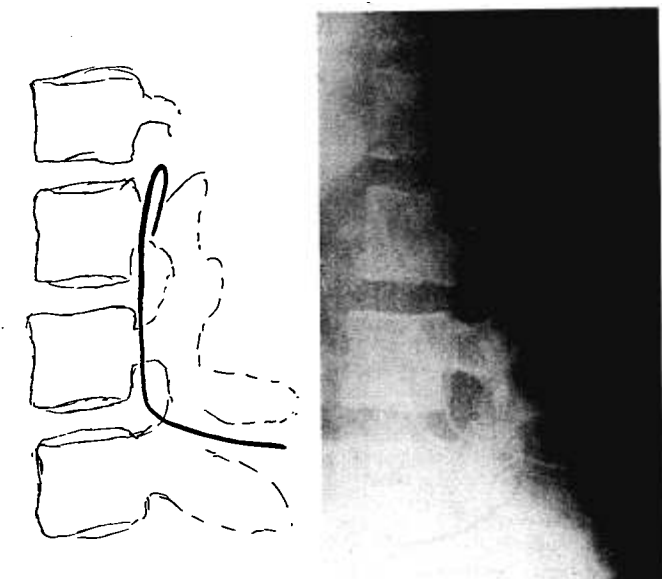


FIG. 3. Improper placement of catheter. The catheter was inserted without stilet. It has reversed its direction and too low an anesthesia was obtained.

Paresthesias were occasionally produced by the needle or catheter during their insertion, but neurologic sequelae have not appeared in these patients.

The following are résumés of cases of intraspinal segmental anesthesia.

Figure 4 is the record of a 37-year-old, obese man with a large incisional hernia. Puncture was done at the third lumbar interspace. The length of catheter within the subarachnoid space was 14 cm. The patient tolerated well the repair of an extensive defect. A segmental distribution of anesthesia was illustrated by the fact that it was necessary for the surgeon to infiltrate the

scrotum with procaine to insert a drain while anesthesia of the abdomen was still entirely satisfactory. The operation lasted four hours and fifteen minutes. A total dose of 5.5 mg. of pontocaine was injected.

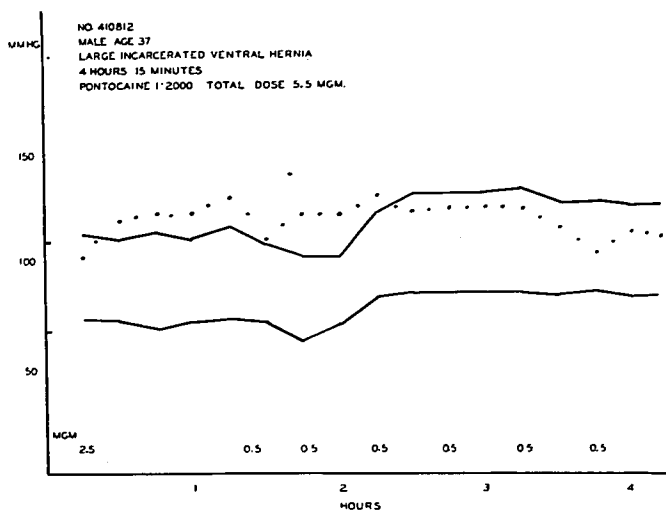


FIG. 4. Man, age 37; repair large incarcerated ventral hernia. Duration 4 hours 15 minutes; total dose pontocaine 5.5 mg.

Figure 5 represents the longest anesthesia of the series. A 50-year-old man was operated on because of carcinoma of the pancreas. Puncture was done at the second lumbar interspace. The length of catheter within the subarachnoid space was 20 cm. The operation required six hours and fifty minutes. An extensive resection of the duodenum and pancreas was performed. A total dose of 6 mg. of pontocaine was given. The patient died on the second post-operative day because the hepatic artery had been accidentally ligated.

Figure 6 is the chart of a 49-year-old man with a perforated peptic ulcer. Puncture was done at the second lumbar interspace. The length of catheter within the subarachnoid space was 17 cm. Satisfactory anesthesia for closure of the perforation was produced by the injection of 5 cc. (2.5 mg.) of pontocaine and 1 cc. (0.5 mg.) twenty minutes later. After one hour and thirty minutes of surgery, anesthesia was present between the sixth thoracic and third lumbar segments.

Figure 7 represents a 70-year-old man on whom cholecystectomy was performed. Puncture was done at the third lumbar interspace. The catheter was inserted 24 cm. within the subarachnoid space. The maximum extent of

anesthesia was from the first to the twelfth thoracic segments. The operation lasted one hour and forty minutes. The total dose of pontocaine was 4 mg.

Figure 8 is the chart of a 70-year-old woman on whom cholecystectomy was performed. Puncture was done at the second lumbar interspace. The length of catheter within the subarachnoid space was 15 cm. An initial injection of 5 cc. (2.5 mg.) produced anesthesia between the third thoracic and second lumbar segments. After fifty-five minutes an additional 2 cc. (1 mg.) was given. The operation was completed fifty-five minutes later. Forty-five minutes

NO 41012
 MALE AGE 50
 CA. PANCREAS WHIPPLE OPERATION
 6 HOURS 50 MINUTES
 PONTOCAINE 1:2000-TOTAL DOSE 6 MGM.

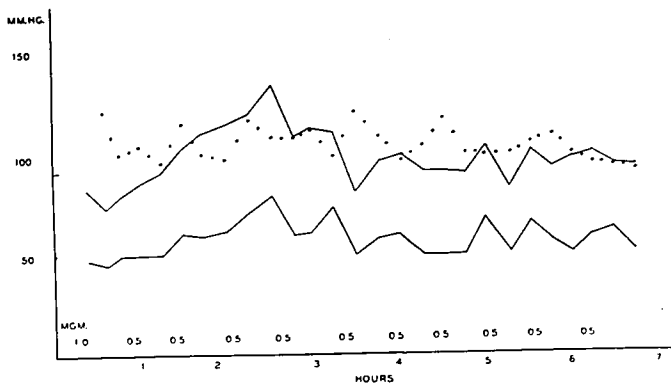


Fig. 5. Man, age 50; Whipple operation. Duration 6 hours 50 minutes; total dose pontocaine 6.0 mg.

after the patient left the operating room, anesthesia was present between the seventh thoracic and first lumbar. The total dose of pontocaine was 3.5 mg.

Figure 9 is the record of a 63-year-old woman. Puncture was done at the third lumbar interspace. The length of catheter within the subarachnoid space was 15 cm. The repair of a strangulated umbilical hernia lasted one hour and ten minutes, and required only 1 mg. of pontocaine. Anesthesia extended from the eighth to the twelfth thoracic segments.

Figure 10 illustrates that the lower level of anesthesia can be too high for the operation. Puncture was done at the second lumbar interspace. The catheter was advanced 21 cm. within the subarachnoid space. An initial injection

tion of 2 cc. (1 mg.) produced anesthesia between the fourth and eighth thoracic segments. The surgeon was unable to proceed because of inadequate anesthesia at the operative site. Two additional injections of 2 cc. each failed to produce the desired result. The catheter was then withdrawn 5 cm., and 2 cc. again injected. The lower level promptly changed to the twelfth thoracic. A strangulated, internal hernia was repaired. The operation lasted one hour and ten minutes. A total dose of 4 mg. was given.

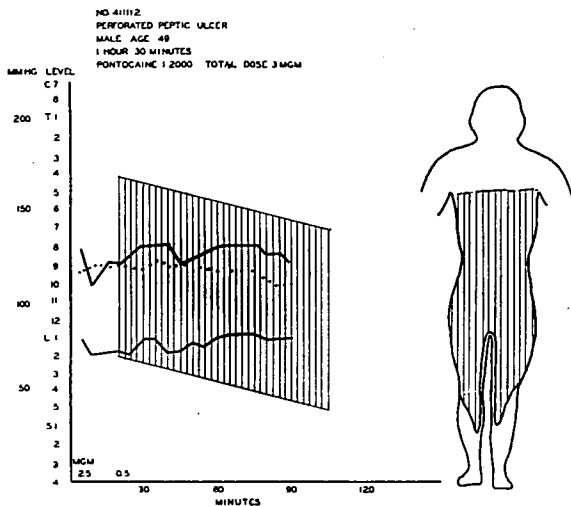


FIG. 6. Man, age 49; suture perforated peptic ulcer. Duration 1 hour 30 minutes; total dose pontocaine 3 mg.

DISCUSSION

Certain technical and theoretical considerations of intraspinal segmental anesthesia produced by a 1:2,000 pontocaine solution will be discussed in relation to first, the agent, and second, the method.

AGENT

The solution of anesthetic drug in this dilution (5 mg. of pontocaine hydrochloride in 10 cc. of spinal fluid) is more nearly isobaric and isotonic than the solutions which are ordinarily employed for spinal anesthesia. Its hydrogen-ion concentration deviates little from that of spinal fluid. These characteristics will be considered individually because they are novel to agents employed in spinal anesthesia.

Dilution.—Lindemulder (5) described damage in the spinal cord and nerve roots of patients dying soon after having received a subdural anesthetic. Nicholson and Eversole (6) reported a series of cases with neurologic sequelae following spinal anesthesia. Van Lier (7), Wossidlo (8), Spielmeier (9) and Davis and his associates (10) showed that toxic degenerative changes of the subarachnoid nerve elements may occur following spinal anesthesia. Lundy (11), in an experimental study, concluded that the concentration of the agent is as im-

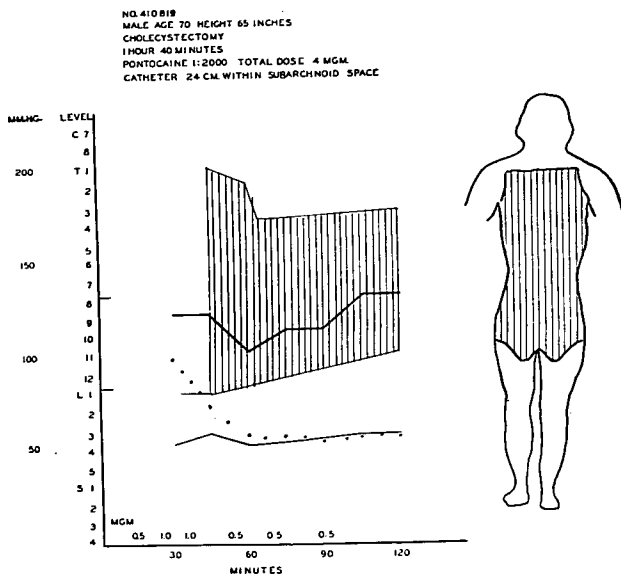


Fig. 7. Man, age 70; cholecystectomy. Duration 1 hour 40 minutes; total dose pontocaine 4.0 mg.

portant as the total dose in producing permanent paralysis. Other experiments (12, 13) in animals demonstrated that those portions of the cord and nerves which are exposed to the highest concentration of the drug are most severely affected. Livingstone and her co-workers (14) reported findings of nerve involvement in cases of death following spinal anesthesia. She stated, "Probably there is in every case some toxic reaction produced in nervous tissue by agents used for spinal anesthesia but, in the majority of cases, repair of this damaged tissue

is apparently rapid and complete. Occasionally, due to some local or general condition of the patient, recovery is retarded or impeded and therefore we have a few, but widely varied, neurologic sequelae which may be temporary or permanent."

Paraplegia, quadriplegia, cauda equina syndrome, neuropathy, myelopathy, encephalopathy and meningitis have been described by numerous observers. Nicholson and Eversole (6) stated that "In the concentration employed, most spinal anesthetic drugs have a toxicity but little short of that which would produce paralysis in a higher percentage of cases."

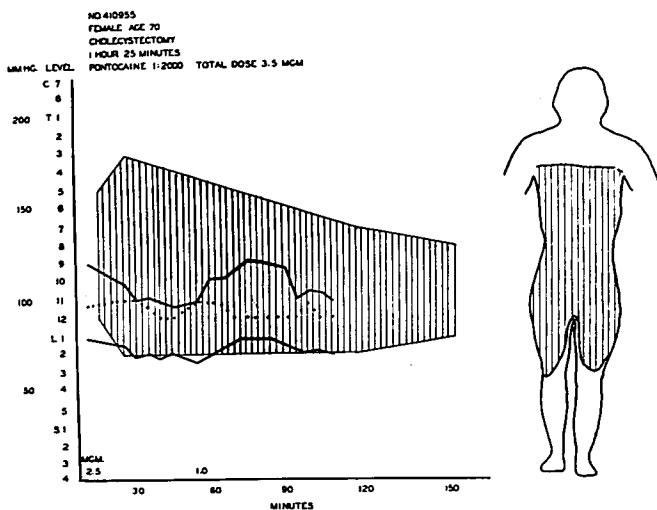


Fig. 8. Woman, age 70; cholecystectomy. Duration 1 hour 25 minutes; total dose pontocaine 3.5 mg.

Because of these pathologic changes and sequelae which have been described, it is desirable to inject into the subarachnoid space the lowest possible concentrations of anesthetic agents that will produce satisfactory anesthesia. A concentration of 1:2000 pontocaine is an effective anesthetic solution only when it is deposited in the immediate vicinity of the nerve roots. This is accomplished by injecting it through a catheter. The necessity of employing more concentrated solutions as when the injection is made into the lumbar region is obviated.

Tonicity.—Certain physical and chemical properties of anesthetic solutions may be partly responsible for organic changes in nerve tissues and meninges. Irritative and degenerative changes may result when tissues are exposed to solutions of different tonicity. Tainter (15) has pointed out in his studies of local anesthetic agents that hypertonic solutions cause shrinkage of cells and hypotonic solutions cause swelling of cells. Wagner (16) has demonstrated in dogs that intrathecal hypotonic solutions are much more harmful than isotonic or hypertonic

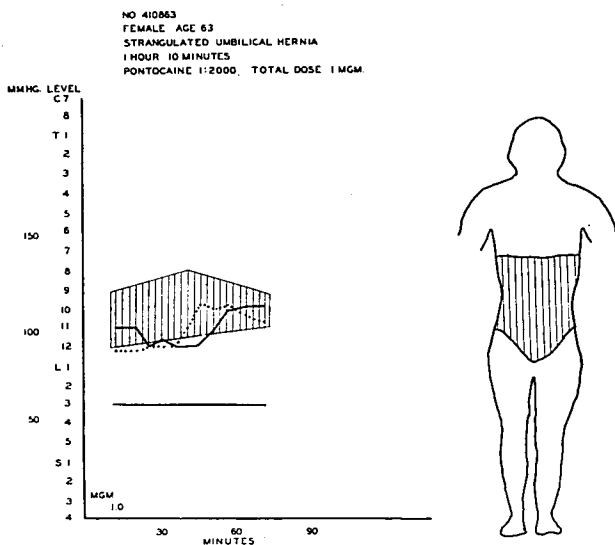


Fig. 9. Woman, age 63; repair strangulated, umbilical hernia; duration 1 hour 10 minutes; total dose pontocaine 1.0 mg.

solutions. *In vitro* experiments on tissue slices show that the tonicity of the medium will alter normal metabolism (17). Therefore, it is advisable to use an anesthetic solution as nearly isotonic as possible.

Baricity.—In the ordinary techniques, a hyperbaric solution is injected, and the patient is turned supine. The primary effect is on the posterior roots, and there is a wider area of sensory loss than of motor paralysis. It becomes difficult for the anesthetist to assure himself of the extent of muscle relaxation. When a hypobaric solution is injected and the patient is turned supine, a greater number of anterior roots are affected

and there is a wider area of motor paralysis than of skin anesthesia. The anesthetist may not be aware of a high level of intercostal paralysis. On the other hand, after the injection of hyperbaric and hypobaric solutions and the patient is turned prone, there is predominantly a motor and sensory loss, respectively.

The use of pontocaine in small amounts in spinal fluid makes an anesthetic solution which is nearly isobaric. The minute quantity of the solute exerts a negligible effect on the specific gravity. Such a

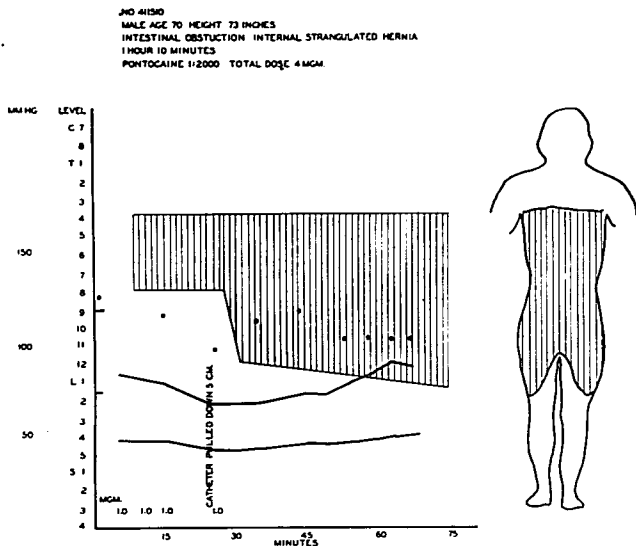


Fig. 10. Man, age 70; reduction internal, strangulated hernia; duration 1 hour 10 minutes; total dose pontocaine 4.0 mg.

solution, deposited in a selected area of the subarachnoid space, has little tendency to spread cephalad or caudad and to involve adjacent segments of the cord and its nerves. Regardless of the position of the patient, the isobaric solution bathes corresponding anterior and posterior nerve roots simultaneously and thus achieves a more nearly equal distribution of motor paralysis and sensory loss.

Hydrionicity.—A chemical factor which may influence the toxicity of an anesthetic agent is the pH of its solution. Tainter (15) stated that highly acid and highly alkaline local anesthetic solutions are ob-

jectionable because they may cause damage to cells. Weaver and Kitchin (18) have demonstrated morphologic changes in cats' sciatic nerves after injection of solutions which are hypotonic and which have an abnormal hydricity. The pH of tissue is about 7.4, while solutions of the commonly employed anesthetic drugs are definitely acid. One per cent pontocaine hydrochloride in saline solution, with acetone bisulfite as a stabilizing agent, has a pH of 3.4, while a 1 per cent aqueous solution of crystals of pontocaine hydrochloride has a pH of 5.5. Spinal fluid is used as the diluent in the preparation of 1:2000 pontocaine and, because of its buffer systems, the solution is as nearly isohydronic as possible. The pH of spinal fluid is reduced about 0.15 in making the 1:2000 solution with 1 per cent pontocaine-acetone bisulfite solution. The pH alteration in making 1:2000 solution of pontocaine crystals in spinal fluid is about 0.02. The anesthetic solution which comes in contact with nerve tissues approaches physiologic values in its specific gravity, tonicity and hydrogen-ion concentration.

METHOD

The standard technics for spinal anesthesia require solutions of anesthetic agents which differ considerably in specific gravity from that of spinal fluid. To obtain diffusion of the agent inside the subarachnoid space, a relatively concentrated solution is injected into the lumbar region so that its concentration will still be effective when it reaches the nerve roots of distant levels. By advancing a catheter within the subarachnoid space, one is able to bathe the specific roots directly with a weak yet effective concentration of the drug without depending on diffusion. Further dilution of the pontocaine solution by spinal fluid *in situ* results in its failure to produce a complete motor or sensory block. Thus the extent of spread of segmental anesthesia depends almost entirely upon the volume of solution injected at any one time. The deposition of a given volume of this solution about selected nerve roots results in a segmental spinal anesthesia with well demarcated upper and lower limits. Since there is little spread of the anesthetic solution in a caudad direction, lumbar, sacral and coccygeal nerves may not be blocked during an intraspinal segmental anesthesia.

The method will be evaluated first, from the standpoint of persistent somatic motor activity and, second, from that of persistent autonomic activity.

Motor.—It is interesting to speculate as to whether the blood pressure fall will be less pronounced with this method than with the usual technics of spinal anesthesia. The cause of hypotension during spinal anesthesia is still uncertain. It is difficult to discuss how the mechanisms involved might be modified by a segmental technic without omitting many important considerations. Since this report represents a small number of cases, no valid conclusion can be drawn from our clinical results.

It has been claimed that muscle paralysis is one of the contributing factors to the fall in blood pressure. SeEVERS and WATERS (19) stated that skeletal muscle paralysis is one of the factors in the chain of events that leads to hypoxia, hypotension and respiratory paralysis. The theory of stagnation of blood in the postarteriolar bed has been defended by SMITH and his associates (20). They stated that there is a pooling of blood in the paralyzed musculature causing a decreased venous return, a diminution in the stroke volume of the heart and a fall in arterial blood pressure. Intraspinal segmental anesthesia for upper abdominal surgery limits the amount of muscular paralysis, for, in every case, it is intended that motor control in the lower extremities shall persist. The muscles of the lower limbs are innervated by nerves which arise below the first lumbar segment of the spinal cord. It is not necessary to block lumbar nerves for surgery of the upper abdomen.

Respiratory paralysis is the greatest single hazard of spinal anesthesia. This type of respiratory failure results from action of anesthetic agents on anterior nerve roots supplying the upper intercostal muscles and the diaphragm. The possibility of its occurrence from uncontrolled spread of the agent is markedly reduced in an intraspinal segmental anesthesia. The technic affords greater control over the anesthetic solution since it is placed directly into the vicinity of selected nerve roots. The hazard is further reduced because the dilution of the agent approaches its minimal effective concentration. Somatic motor fibers are more resistant to the effects of anesthetic drugs than are sensory fibers. EMMETT (21) demonstrated that motor paralysis occurs after loss of sensation during the induction of spinal anesthesia. SOLKOW (22), SARNOFF and ARROWOOD (23) showed that pain sensation can be abolished without producing motor paralysis by intrathecal injections of procaine. Diffusion of 1:2000 pontocaine within the subarachnoid space will result in a concentration insufficient to produce motor paralysis.

Phlebothrombosis may occur less frequently after the use of intraspinal segmental anesthesia since patients are able to move their legs during the operation and the immediate postoperative period. In most cases of phlebothrombosis, clots begin to form in the smaller veins of the foot and calf. Trauma of surgery predisposes to intravascular clotting, and the period of immobilization of the limbs during the ordinary spinal anesthesia adds stagnation of venous flow. It has been said that many cases of phlebothrombosis begin on the operating table. According to HOMANS (24) "Although the proper combination of factors can surely occasion thrombosis at any time, the early hours and days (after operation) are especially liable to it." In view of the above, it may be of distinct advantage to maintain muscular tone in the lower extremities. This is one aim of segmental spinal anesthesia.

Autonomic.—Opposed to the theory of the cause of blood pressure fall already discussed is the concept of paralysis of the vasoconstrictor

fibers in the anterior spinal nerve roots. Ferguson and North (25) stated that the degree of depression of blood pressure is in direct ratio to the number of white rami anesthetized. Co Tui (26) conceived the fall of blood pressure to be the result of somatic and visceral vasodilation. Koster (27) studied the hypotension of spinal anesthesia in normal, unoperated man and concluded that the hypotension is primarily due to arteriolar dilatation. Sarnoff and Arrowood (23), employing the technic of "differential spinal block," stated that the reduction of blood pressure is entirely the result of blocking of sympathetic fibers. Many vasoconstrictor fibers to the lower extremities leave the spinal cord below its twelfth thoracic segment. In the majority of cases of this series complete loss of sensation did not extend below the twelfth thoracic dermatome. Some central vasomotor control in the lower extremities should persist in these patients and the degree of blood pressure fall may be less pronounced. Studies to determine the extent of persistent sympathetic activity during segmental spinal anesthesia have not been completed.

The question of sympathetic innervation of skeletal muscle and its effect on muscle tone has not been settled. Kuntz (28) has reviewed this problem and has concluded that there is evidence to support the contention that sympathetic system activity tends to increase tone of muscles and that sympathectomy is followed by a reduction in muscle tone. This must be considered in evaluating the advantages of segmental spinal anesthesia. The maintenance of normal muscle tone should influence venous return from the extremities, thereby supporting cardiac output, limiting the extent of blood pressure fall, and reducing the incidence of phlebothrombosis.

Anesthesia confined to nerve roots above those which innervate the urinary bladder may lead to a reduced incidence of postoperative urinary disturbances. The mechanism of voluntary micturition is dependent upon a cortical control over certain somatic and autonomic reflexes within the spinal cord (fig. 11). Sympathetic control of the bladder is mediated through the upper lumbar spinal segments by way of the hypogastric nerves. Sympathetic impulses are inhibitory to the detrusor muscle and motor to the trigone, internal sphincter and the smooth muscle of the proximal portion of the urethra. The parasympathetic innervation arises in the first four sacral segments and reaches the bladder through the pelvic nerves. Parasympathetic impulses are motor to the detrusor muscle and inhibitory to the internal sphincter. The pudendal nerves comprise the somatic nerve supply and control the external sphincter. Afferent fibers essential for reflex movements of the bladder are contained in the pelvic nerves, those for movements of the urethra in the pudendal nerves. Sympathetic nerves carry no afferent fibers necessary for the important reflex mechanisms. Denning (29) has shown that section of either the pudendal or hypogastric nerves or both has little effect on voluntary urination, while

section of the pelvic nerves brings about profound functional and trophic disturbances of the bladder. Although premedication, the supine position, trauma of surgery and pain may produce urinary retention during the postoperative period, urinary disturbances may be less frequent following intraspinal segmental anesthesia than after the usual spinal anesthesia.

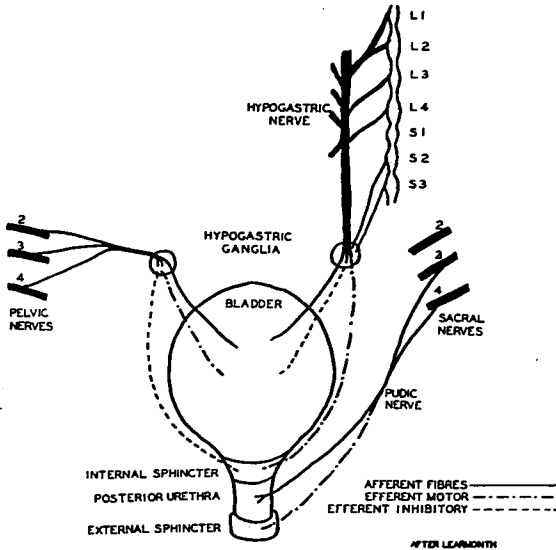


FIG. 11. Innervation of urinary bladder.

SUMMARY

1. A practical and simple method of obtaining a segmental distribution of spinal anesthesia is presented. A limited number of spinal nerve roots are bathed by an anesthetic solution within the subarachnoid space.

2. A solution of pontocaine hydrochloride in a dilution of 1:2000 is injected through a fine catheter which has been passed cephalad within the subarachnoid space a distance of 15 to 25 cm.

3. A 1:2000 dilution of pontocaine is of sufficient concentration to produce satisfactory spinal anesthesia by this technic.

4. The total dose of pontocaine is a small fraction of that ordinarily required for spinal anesthesia.

5. The following practical and theoretical advantages of intraspinal segmental anesthesia have been discussed:

a. The dilute solution of pontocaine in spinal fluid may be considered to be nearly isotonic, isobaric and isohydronic. Local toxic effects and neurologic sequelae are, therefore, less likely to result.

b. The accurate deposition of such a weak solution of anesthetic agent within the subarachnoid space reduces the hazard of respiratory paralysis.

c. Persistence of motor power in the lower extremities may result in a more efficient return flow of blood to the heart and may have a beneficial effect on the systemic circulation during anesthesia.

d. Maintenance of muscle tone in the legs may result in a decreased incidence of phlebothrombosis.

e. Postoperative urinary disturbances may be less common.

Note.—Since submitting this report, we have found that the 1:2000 concentration of pontocaine in spinal fluid produced inadequate analgesia in an occasional patient. For this reason, we now employ a 1:1000 solution. The pH of spinal fluid is reduced about 0.18 using 1 per cent pontocaine-acetone bisulfite solution and 0.03 using pontocaine crystals to make the latter preparation.

REFERENCES

1. Kirschner, M.: Spinal Zone Anesthesia, Placed at Will and Individually Graded, *Surg., Gynec. & Obst.* **55**: 317-329 (Sept.) 1932.
2. Phillipides: Spinal Anesthesia, Segmental Block, Nupercaine Anesthesia, *Arch. Klin. Chir.* **189**, 1937.
3. Fay, T., and Gotten, N.: Controlled Spinal Anesthesia; Its Value for Establishing Appropriate Levels for Chordotomy, *Arch. Neuro. & Psychiat.* **30**: 1276-1281 (Dec.) 1934.
4. Vehr, J. R.: Spinal Anesthesia, St. Louis, C. V. Mosby Co., 1934.
5. Lindemulder, F. G.: Spinal Anesthesia, Its Effect on the Central Nervous System, *J. A. M. A.* **99**: 210-212 (July 16) 1932.
6. Nicholson, M. J., and Eversole, U. H.: *J. A. M. A.*, in press.
7. Van Lier, E. H.: Histologischer Beitrag zur Rückenmarks-anästhesie, *Beitr. z. Klin. Chir.* **54**: 413, 1907.
8. Wossido, E.: Experimentelle Untersuchungen über Veränderungen der nissischen Granula bei der Lumbalanästhesie, *Arch. f. Klin. Chir.* **86**: 1017, 1908.
9. Spielmeier, E.: Veränderungen des Nervensystems nach Stovain-Anästhesie, *München med. Wehnschr.* **55**: 1629, 1908.
10. Davis, L.; Haven, H.; Givens, J. H., and Emmett, J.: Effects of Spinal Anesthetics on the Spinal Cord and Its Membranes, *J. A. M. A.* **97**: 1781 (Dec. 12) 1931.
11. Lundy, J. S.; Essex, H. E., and Kernohan, J. W.: Experiments with Anesthetics. IV. Lesions Produced in the Spinal Cord of Dogs by a Dose of Procaine Hydrochloride Sufficient to Cause Permanent and Fatal Paralysis, *J. A. M. A.* **101**: 1546-1550 (Nov. 11) 1933.
12. MacDonald, A. D., and Watkins, K. H.: An Experimental Investigation into the Cause of Paralysis Following Spinal Anesthesia, *Brit. J. Surg.* **25**: 879-883, 1937-1938.
13. Klöse, H., and Vogt, H.: Physiologische und Anatomische Untersuchungen zur Lumbalanästhesie und zur Frage ihrer Klinischen Verwertbarkeit, *München Med. Wehnschr.* **56**: 505-507, 1909.
14. Light, G.; Sweet, W. H.; Livingstone, H., and Engel, R.: Neurological Changes Following Spinal Anesthesia, *Surgery* **7**: 138-156 (Jan.) 1940.

15. Tainter, M. L.: Summary of Studies on the Optimal Composition of Local Anesthetic Solutions, *Anesthesiology* 2: 489-502 (Sept.) 1941.
16. Wagner, J. C.; Sievers, R. F.; Bennett, A. L., and McIntyre, A. R.: Spinal Anesthesia in the Dog, *J. Pharmacol. & Exper. Therap.* 68: 437-453 (April) 1940.
17. Rapport, D., and Canzanelli, A.: Personal communication.
18. Weaver, H. M., and Kitchin, F. C.: Observations on Peripheral Nerves Following Local Injections of 1) Isotonic Solutions of Varying pH and 2) "Iso-pH" Solutions of Varying Tonicity, *J. Dent. Res.* 17: 431 (Dec.) 1938.
19. SeEVERS, M. H., and Waters, R. M.: Respiratory and Circulatory Changes During Spinal Anesthesia, *J. A. M. A.* 99: 961-968 (Sept.) 1932.
20. Smith, H. W.; Rovenstine, E. A.; Goldring, W.; Chasis, H., and Ranges, H. A.: The Effects of Spinal Anesthesia on the Circulation in Normal Unoperated Man with Reference to the Autonomy of the Arterioles and Especially Those of the Renal Circulation, *J. Clin. Investigation* 18: 319-341 (May) 1939.
21. Emmett, J. L.: Subarachnoid Injections of Procaine Hydrochloride. The Quantitative Effects of Clinical Doses on Sensory Sympathetic and Motor Nerves, *J. A. M. A.* 102: 425-432 (Feb. 10) 1934.
22. Solkow, M. L.: Selective Sensory (Posterior) Spinal Root Block; a Preliminary Report, *Anesth. & Analg.* 24: 261-262 (Nov.-Dec.) 1945.
23. Sarnoff, S. J., and Arrowood, J. G.: Differential Spinal Block, *Surgery* 20: 150-159 (July) 1946.
24. Homans, J.: *Circulatory Diseases of the Extremities*, New York, Macmillan Co., 1939.
25. Ferguson, L. K., and North, J. P.: *Experimental Spinal Anesthesia*, *Surg., Gynec. & Obst.* 54: 621-634 (Apr.) 1932.
26. Co Tui, F. W.: Further Studies in Subarachnoid Anesthesia, *Anesth. & Analg.* 13: 183-192 (Sept.-Oct.) 1934.
27. Koster, H.: Blood Pressure Changes During Spinal Anesthesia in Non-operative Cases, *Arch. Surg.* 45: 596-605 (Oct.) 1942.
28. Kuntz, A.: *The Autonomic Nervous System*, Philadelphia, Lea & Febiger, 1945.
29. Denning, H.: Untersuchungen über die Innervation der Harnblase und des Mastdarmes, *Ztschr. f. Biol.* 80: 239-254, 1924.

AWARD OF SWEDISH ORDER OF VASA TO
DR. RALPH M. WATERS

His Majesty, the King of Sweden, recently honored Dr. Ralph M. Waters of Madison, Wisconsin, by making him a knight of the Order of Vasa, First Class. Mr. G. Oldenburg, Swedish consul-general, of the Swedish Consulate in Chicago, made the presentation at a dinner in Madison, March 17, 1947. The dinner was attended by the executive committee of the Medical School, University of Wisconsin and many of Dr. Waters' colleagues from the State of Wisconsin General Hospital. This award was granted in appreciation of Dr. Waters' public services to Sweden in the training of three Swedish doctors in the field of Anesthesiology.

Dean William S. Middleton presided as toastmaster. Following pertinent and accurate complimentary remarks concerning Dr. Waters, he introduced the Swedish consul-general. Mr. Oldenburg reviewed the history of the Order of Vasa and made known the gratitude of the Swedish medical profession to Dr. Waters for public service to them by training their first anesthesiologists. In Dr. Waters' acceptance of the medal, he characteristically pointed out that such an honor was not purely a personal one, but one which included the fine spirit of cooperation and "team-work" which exists among the medical faculty at Wisconsin. Dr. Eric Nilsson, the third Swedish doctor to study in Madison, on behalf of himself and his predecessors, thanked Dr. Waters for his many kindnesses and wise counsel.