

sion of the rebreathing bag. The pulse was imperceptible for a short period. Spontaneous respirations returned but they were very noisy. It was noted that the noise was coming from the wound. At 9:30 a.m. apnea occurred again and the pulse could not be palpated at the wrist. At 9:50 a.m. the patient was turned supine and a left perivertebral upper abdominal incision was made through which cardiac massage was performed. Cardiac injection was attempted. However, straw-colored fluid was aspirated instead of blood so the injection was not made. Cyanosis increased progressively and the patient was pronounced dead at 10:30 a.m.

The surgeon was unable to account for the fatal outcome. Very little hemorrhage had been encountered. The sympathetic chain had been sectioned without a change in the patient's condition. He did not believe that the right pneumothorax in itself could be the cause of death. The patient became pulseless and apneic just prior to starting the closure.

The anesthesiologist had been very pleased with the patient's vital signs before the appearance of the apnea. It was thought that the anesthetic agents which had been used were not the cause of the patient's death. The pneumothorax was apparently well controlled by positive pressure.

Necropsy was performed. A summary of the findings is as follows: Near the apex of the right lung, posteriorly, at the level of the second and third ribs, at the costovertebral junction, two tears were observed in the parietal pleura. Each tear measured about 1 cm. in diameter. There was slight hemorrhage into the soft tissues about the margins of the tears.

Upon opening the pericardial sac, it was found to contain about 150 cc. of clear yellow fluid. The heart was lying free in

the pericardial sac. It appeared enlarged owing to dilatation of the right chambers. On nicking the right ventricle, large amounts of fine, frothy fluid welled from within. The appearance was typical of air embolism. Inspection of the superior vena cava, superior intercostal vein and the vena azygos major showed the presence of fine bubbles of air. Similar frothy blood was present in the upper part of the inferior vena cava. The point of entry of the air was evidently through the tears in the parietal pleura in the upper right chest by way of the superior intercostal vein.

The pulmonary artery contained large amounts of fine frothy blood. The cut surfaces of the lungs were pink in color and quite dry. The rest of the examination including the brain did not reveal any abnormal findings. A possible explanation appears below.

The air embolism was probably the result of the following mechanism. Openings were made into both the superior intercostal vein and the parietal pleura. A partial pneumothorax occurred. When a moist sponge was placed in the wound a closed system resulted. During inspiration the air in the pleural cavity was forced through the tear in the pleura, raising the pressure in the wound. The air entered the superior intercostal vein easily because of its low venous pressure. Probably a large amount of the air found at autopsy was forced into the veins during the attempt at resuscitation.

This case history records an unusual manner in which air embolism may occur. It also illustrates the importance of performing a necropsy in all cases of sudden death occurring during anesthesia.

R. W. BURNAP, M.D.,
*University of Alberta Hospital,
Edmonton, Alberta.*

AIRWAYS—A NEW MAKE AND A NEW TYPE

We wish to introduce airways made of a plastic material, cellulose acetate butyrate, and a new type of intubating airway.

The advantages of a plastic airway are its transparency, easy insertion and removal in case of spasm of the jaw muscles,

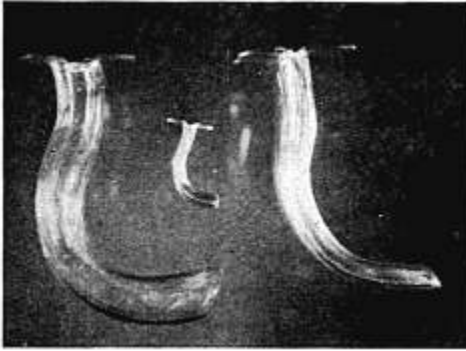
the ease with which it can be cleaned, a tensile strength of 800 pounds, its permanency and low cost. The disadvantage of these airways is that they cannot be boiled or autoclaved. They are maintained sterile in bichloride of mercury solution.

The ordinary pharyngeal airways are being manufactured of plastic in all sizes, ranging from the infant to the large male type.

The intubating airway is similar in length and shape to the ordinary Guedel airway with the difference that it is made of plastic and its lumen is circular, admitting tubes up to size 38 French.

with a thrust. The tube and airway are easily anchored to the face with adhesive.

The intubating airway has been successfully used in over 100 cases and has often succeeded where direct laryngoscopy was difficult or had failed. It has proved successful when patients had to be intubated who were in the lateral or prone position during operation. It can be inserted in



The technic of intubating is similar to that used in the blind nasal method. The endotracheal tube is inserted into the airway to its tip and the airway is then inserted into the mouth. The left hand tilts the flange of the airway back and forth while the right hand holds the outer end of the tube close to the ear, listening for the point of maximum intensity of respiration. At the point of maximum inspiration the tube is slipped into the trachea

comatose patients and their tracheas can be cleared of mucus easily with a tracheal suction catheter. The many advantages of these airways are a definite aid to the anesthesiologist.

BERNARD CAPPE, M.D.,
Jewish Hospital of Brooklyn,
Brooklyn 16, N. Y., AND
ROBERT BERMAN, M.D.,
Mount Sinai Hospital,
New York, N. Y.

SEVERE HEMORRHAGE WITH ASSOCIATED TRANSFUSION REACTION: REPORT OF CASE *

A man, age 25 years, gave a history of shrapnel injury in November 1944 while

* Published with the permission of the Chief Medical Director, Department of Medicine and Surgery, Veterans Administration, who assumes no responsibility for the opinions expressed, or conclusions drawn by the author.

in France. At that time he received wounds of the head, face, back and right chest and was unconscious for about twelve days. A tracheotomy and partial removal of the right mandible were performed shortly after injury. In 1945 scar tissue was removed from the face and a bone graft placed in the mandible. There