

child was returned immediately to the oxygen hood.

The following day, the condition of the patient was very satisfactory. Respirations were reduced to about 40 per minute and were regular and without effort. A roentgenogram of the chest showed complete expansion and aeration of the left lung. The infant was kept in the oxygen hood for several days following the surgical procedure and then removed completely. Small feedings were started slowly.

The child was discharged from the hospital to await a period of growth until such time as repair of the abdominal defect is deemed advisable. The left lung now shows only a small area of atelectasis at the apex.

Lt. COL. JOHN GARDINER, M.C.,
Chief, Anesthesia and Operating
Section,
Walter Reed General Hospital,
Washington, D. C.

REFERENCES

1. Singleton, H.; Magill, I. W.; Clausen, R. J., et al.: *Anesthetics in Children*, Proc. Roy. Soc. Med. 19: 1-8 (Nov. 6) 1925.
2. Dunlop, J. G.: *Anesthetic Practices in Thoracic Surgery*, Current Researches in Anesth. & Analg. 18: 301, 1939.
3. Gillespie, N. A.: *Endotracheal Anesthesia*, ed. 2, University of Wisconsin, Madison, Wis., 1948.
4. Cope, R. W.; Aserman, D., and Magill, I. W.: Discussion On Anesthesia In Children, Proc. Roy. Soc. Med. 40: 54-544 (March 28) 1947.
5. Sise, L. F.: *Anesthesia for Thyroid Surgery*, J. Indiana M. A. 30: 180-185 (April) 1937.
6. Nosworthy, M. D.: *Anesthesia in Chest Surgery with Special Reference to Controlled Respiration and Cyclopropane*, Proc. Roy. Soc. Med. 34: 479-506 (June) 1941; Proc. Roy. Soc. Med. 34: 1 (April 4) 1941.
7. Tuffier, T.: *L'ouverture de la Plèvre sans Pneumothorax*, Presse méd., Paris 14: 57-60, 1906.

SUBSTITUTE NASOPHARYNGEAL AIRWAY

To reduce the incidence of epistaxis in patients when using manufactured nasopharyngeal airways and to effect economy

owing to continuous losses, an economical and satisfactory substitute was developed by this department. The materials used

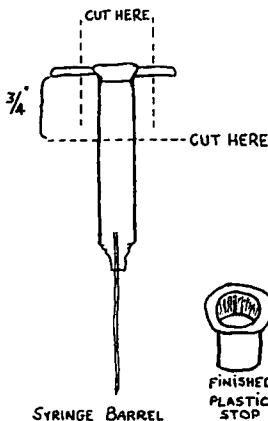


FIG. 1.

are (1) discarded plastic disposable penicillin syringes and (2) black latex laboratory tubing.

The barrels of the syringes are cut to size (see drawing), and then smoothed with a grindstone. These serve as a stop to prevent the tubing from passing through the external nares.

Black latex laboratory tubing, which is manufactured in various sizes and is very soft and pliable, is then cut into desired lengths and beveled at one end. The beveled end can be smoothed by inserting the tip into the flame of a Bunsen burner for thirty seconds and then smoothing with a knife. Talcum powder is rubbed on the end to prevent stickiness. An alternate method is to rub the edges with ether-soaked gauze and then apply the talcum powder.

The plastic stop can be inserted into the tubing by stretching the end with a nasal

speculum. The completed nasopharyngeal airway can be sterilized only in a solution that is not a solvent. Autoclaving or alcohol and other organic solvents destroy the plastic stop. We have found benzalkonium chloride ("zephiran") solution to be satisfactory.

The incidence of epistaxis caused by nasopharyngeal airways has been reduced by the substitution of black latex laboratory tubing for the red rubber tubing ordinarily used. This latex tubing is so smooth, soft, and pliant that it will, when well lubricated, slip past most obstructions, polyps, and so forth, with minimal trauma. The cost of such an airway is so small that replacement is no longer an economic problem.

LEONARD KERNIS, M.D.,
*Department of Anesthesiology,
Michael Reese Hospital,
Chicago, Illinois*