

CURARE IN THE MANAGEMENT OF AUTONOMIC REFLEXES * †

C. L. BURSTEIN, M.D.; A. JACKSON, M.D.; HAROLD F. BISHOP, M.D.,
AND E. A. ROVENSTINE, M.D.

New York, N. Y.

Received for publication May 17, 1949

As early as 1856, Claude Bernard demonstrated that curare causes muscular paralysis and that it also depresses certain autonomic reflexes. In his lesson on the effects of curare on vagal reactions he showed that whereas it is possible, under normal circumstances, to stop the movements of the heart by an electrical stimulus to the vagus nerve, cardiac arrest cannot be produced by the same stimulus to the vagus in a curarized animal (1).

In 1918 Langley reported similar results and, in addition, showed that curare can also prevent arterial hypotension incident to vagal stimulation (2). His experiments and those of Bernard have remained classic physiologic observations without practical clinical application despite numerous untoward effects encountered during surgical intervention involving vagal stimulation.

Recently similar experiments have been completed in the laboratory confirming the results described by these eminent physiologists and extending the observations to include the effects from stimulating other autonomic pathways in the curarized animal. Figure 1 illustrates a confirmatory experiment in which curare prevented arterial hypotension due to vagal stimulation. In addition, curare has been used to treat hypotension and bradycardia when they followed surgical stimulation of autonomic reflexes in anesthetized man (3). These laboratory and clinical observations are the basis of this report.

VAGAL STIMULATION

The effectiveness of curare in the management of arterial hypotension during an intrathoracic operation can be adduced from the following clinical experience.

Case 1.—A 55-year-old man was undergoing a right pneumonectomy. Anesthesia was being maintained with cyclopropane and ether. A closed orotracheal airway was in place. When dissection of the hilum was started there was a fall

* Published by permission of the Chief Medical Director, Veterans Administration, who assumes no responsibility for the opinions expressed or the conclusions drawn by the authors.

† From the Veterans Administration Hospital, Bronx, N. Y., and the Department of Anesthesia, New York University College of Medicine, New York, N. Y.



FIG. 1. Alteration in vagal reflex following the administration of d-tubocurarine in a dog anesthetized with ether. Upper tracing, arterial blood pressure. Lower tracing, base line.

- a*—Time of stimulation of vagus nerve with faradic current.
b—Time of cessation of vagal stimulus.

- A—Stimulation of the right vagus nerve in the lower cervical region caused the arterial blood pressure to fall from 100 mm. systolic to 12 mm. and temporary asystole was produced.
 B—Stimulation of the right vagus nerve as in A five minutes after the intravenous injection of d-tubocurarine (1.5 units per kilogram) caused no change in arterial blood pressure level and the pulse rate slowed from 96 to 80 per minute.

in the arterial blood pressure from 116 mm. of mercury systolic and 70 diastolic to 88 systolic without change in the pulse rate. After persistence of this hypotension for ten minutes, 50 units of d-tubocurarine was given intravenously. Five minutes later, the arterial blood pressure had returned to its previous level. Ten minutes later, the arterial blood pressure had risen even higher—to 140 mm. of mercury systolic and 90 diastolic. Ten minutes later the blood pressure was determined at its previous normal level and it was maintained for more than an hour despite continued manipulations about the hilum (fig. 2).

CAROTID SINUS REFLEX

Heymans demonstrated that pressure stimulation of the carotid sinus can cause arterial hypotension and bradycardia (4). The afferent arc of the reflex is conveyed by the sinus nerve (branch of the glossopharyngeal) the efferent pathway of which is by way of the cardiac vagus. Such reflexes are not uncommon during surgical procedures involving structures of the neck and may be treated by curare as shown in the following case.

Case 2.—A 68-year-old man was undergoing a radical neck dissection for metastatic carcinoma. Five months previously, laryngectomy, tracheostomy and gastrostomy had been performed for an extensive carcinoma of the larynx. On the day of the operation, the patient was given 6 mg. of morphine sulfate and 0.3 mg. of atropine sulfate hypodermically. An hour and a half later, he was anesthetized with pentothal sodium administered intravenously in appropriate quantities from an infusion solution of 0.1 per cent concentration in physiologic saline. This was combined with nitrous oxide and oxygen in 50 per cent concentrations administered through a tracheotomy opening by means of an endo-

tracheal tube. An hour after the start of the operation, while the surgeons were handling the glandular mass in the neck and pulling on the carotid bulb, there was a decrease in the arterial blood pressure from 132 mm. systolic and 60 diastolic to 100 mm. systolic and 60 diastolic while the pulse rate decreased from 110 to 90 per minute. Five minutes later, the blood pressure had diminished further

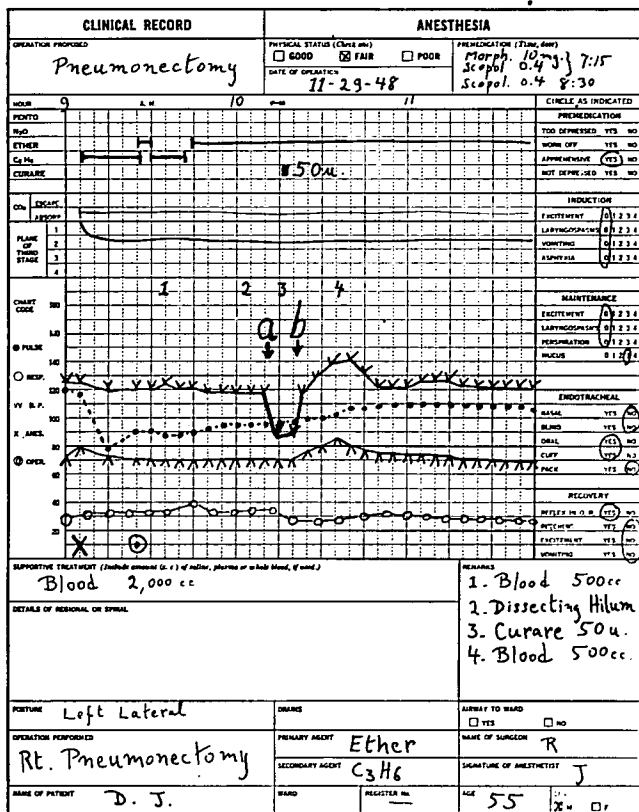


FIG. 2. Treatment of a vagal reflex during pneumonectomy. Manipulation of the hilum, at a, caused a fall in the arterial blood pressure from 116 mm. systolic to 88 mm. without change in the diastolic pressure. Ten minutes later 50 units of d-tubocurarine was injected intravenously. After five minutes, at b, the arterial blood pressure returned to its previous level.

CLINICAL RECORD		ANESTHESIA	
OPERATION PERFORMED Radical Neck Dissection		PHYSICAL STATUS (Check one) <input type="checkbox"/> GOOD <input checked="" type="checkbox"/> FAIR <input type="checkbox"/> POOR	PREMEDICATION (Drug, Dose) Morph. 6mg Atrop. 0.3} 10:10 A.M.
DATE OF OPERATION 11-3-48			
HOURS 11:30	A.M.	12:30	1:00
PENTO		CIRCLE AS INDICATED	
N ₂ O		PREMEDICATION	
ETHER		TOO DEPRESSED YES NO	
C ₂ H ₆		WORN OFF YES NO	
CURARE		APPROXIMATE YES NO	
		NOT DEPRESSED <input checked="" type="checkbox"/> NO	
CO ₂ ESCAPE			INDUCTION
APPROX.			FACEWENT 0 1 2 3 4
1			LARYNGOSPASM 0 1 2 3 4
2			VOMITING 0 1 2 3 4
3			APNOEA 0 1 2 3 4
4			
PLANE OF THIRD STAGE			MAINTENANCE
1			FACEWENT 0 1 2 3 4
2			LARYNGOSPASM 0 1 2 3 4
3			PERSPHATION 0 1 2 3 4
4			MUCUS 0 1 2 3 4
CHART CODE			ENDOTRACHEAL
180			NASAL YES NO
160			BEHND YES NO
140			DIPAL YES NO
120			CLIP YES NO
100			PACK YES NO
80			RECOVERY
60			REFLEX IN O B YES NO
40			ITCHING YES NO
20			STIMULANT YES NO
			SMITHING YES NO
SUPPORTIVE TREATMENT (Indicate amount (c. c.) of saline, plasma or whole blood, if used.)		REMARKS	
DETAILS OF REGIONAL OR SPINAL		a. Stimulation of Carotid Bulb b. Curare	
POSTURE Supine	DRAINS	AIRWAY TO WARD <input type="checkbox"/> YES <input type="checkbox"/> NO	
OPERATION PERFORMED Radical Neck Dissection	PRIMARY AGENT Pentothal	NAME OF SURGEON P	
NAME OF PATIENT N.C.	SECONDARY AGENT N₂O	SIGNATURE OF ANESTHETIST J.	
	WARD	REGISTER NO.	AGE 68
			SEX <input checked="" type="checkbox"/> M <input type="checkbox"/> F

FIG. 3. Treatment of a carotid sinus reflex during a radical neck dissection. Manipulation about the carotid bulb caused decrease in the arterial blood pressure from 132 mm. systolic and 60 diastolic to 40 mm. systolic and 22 diastolic, while the pulse rate diminished from 110 to 54 per minute (a). After the intravenous injection of 40 units of d-tubocurarine the arterial blood pressure resumed its previous level (b) and the pulse rate rose to 72 per minute.

to 60 mm. systolic and 36 diastolic, and the pulse rate was reduced to 72 per minute. Five minutes later, the circulatory depression was even more pronounced; the systolic arterial pressure then was 40 mm., the diastolic 22 and the pulse rate 54 per minute. At this point, 40 units of d-tubocurarine was injected intrave-

nously. Three minutes later, the blood pressure was 100 mm. systolic, 50 diastolic, and the pulse rate had increased to 72 per minute despite continued cervical dissection. Five minutes later the blood pressure was 130 mm. systolic and 76 diastolic with maintenance of the pulse rate at 72 per minute. These levels were maintained throughout the operation which continued another hour (fig. 3).

Another case of radical neck dissection which presented a similar circulatory depression was treated in the same manner with similar results.

Experimental investigations in 8 dogs produced similar effects as the following protocol indicates. A dog of 9 kg. was given 18 mg. of morphine sulfate subcutaneously. Twenty-five minutes later, anesthesia was induced with pentothal sodium, 25 mg. per kilogram in a 2 per cent solution, injected intravenously. The right femoral artery




FIG. 4—Alteration in carotid sinus reflex following the administration of d-tubocurarine in a dog during pentothal sodium anesthesia. Upper tracing, arterial blood pressure. Lower tracing, time in second intervals.

a—Time of stimulation of the carotid sinus.

b—Time of cessation of carotid sinus stimulation.

A—Stimulation of the carotid sinus before the injection of d-tubocurarine caused the arterial blood pressure to decrease from 80 to 28 mm. systolic and the pulse rate diminished from 180 to 130 per minute.

B—Stimulation of the carotid sinus six minutes after the injection of d-tubocurarine (1 unit per kilogram) produced no change.

was cannulated to register the blood pressure. The right common carotid artery was isolated to its bifurcation and a tape was applied about the carotid bulb. The arterial blood pressure was 100 mm. systolic and the pulse rate was 96 per minute. Upon pulling the tape at the carotid bulb, the blood pressure fell to 70 mm. and the pulse rate diminished to 36 per minute (fig. 4A). Upon release of the tape, the blood pressure and pulse rate returned to their original readings. Ten units of d-tubocurarine was then injected intravenously. This resulted in paralysis of the intercostal muscles and a temporary decline in the arterial blood pressure. Three minutes later similar stimulation of the carotid sinus as done previously caused only a negligible decrease in the blood pressure without change in the pulse rate (fig. 4B). Repeated stimulation of the carotid sinus during the next fifteen minutes failed to elicit any greater alteration in circulatory reaction. Forty minutes after the administration of the d-tubocurarine, the intercostal muscles resumed their activity. Stimulation of the carotid sinus at this time again produced arterial hypotension and bradycardia though not as intense as when the same stimulus had been applied before the injection of d-tubocurarine.

CELIAC PLEXUS REFLEX

The first observation here of the beneficial effects of curare on autonomic reflexes was during an abdominal operation after a celiac plexus reflex was elicited. Muscular rigidity often complicates such reflex activity during abdominal surgery (5, 6). In an effort to obtain better muscular relaxation during gastric resection, the injection of curare was followed not only by the desired muscular relaxation but also by an improvement of the circulatory depression. The following is an illustrative report.

Case 3.—A 56-year-old man had a gastric ulcer for which gastric resection was proposed. Preanesthetic blood pressure was 120 mm. systolic and 70 diastolic with a pulse rate of 80 per minute. Anesthesia was induced with cyclopropane and ether was used for maintenance. Twenty minutes after the start of the operation, when intra-abdominal manipulation was first begun, there was a sudden fall in arterial blood pressure to 68 mm. systolic and 50 diastolic and the pulse rate was 76 per minute. Surgical manipulation was interrupted for five minutes. The blood pressure then was 80 mm. systolic and 50 diastolic and the pulse rate was 80 per minute. A blood transfusion was started and the operation resumed. Five minutes later the blood pressure diminished to 68 mm. systolic and 50 diastolic and the pulse rate was 76 per minute. Five minutes later the blood pressure dropped further to a systolic of 60 mm. and diastolic of 50 with the pulse rate at 80 per minute. During the next fifty minutes there was no change in the patient's hypotension and the condition was complicated by the development of marked rigidity of the abdominal muscles which interfered seriously with surgical progress. A small dose of curare was given to produce muscular relaxation. The drug, d-tubocurarine (40 units), was injected intravenously and surgical manipulation was continued. Muscular

relaxation was adequate after two minutes and the blood pressure increased to 96 mm. systolic and 60 diastolic while the pulse rate was increased to 90 per minute. During the next twenty-five minutes there was a progressive rise in the arterial blood pressure to 130 mm. systolic and 60 diastolic and the pulse rate was 96 per minute. This normal arterial blood pressure level was main-

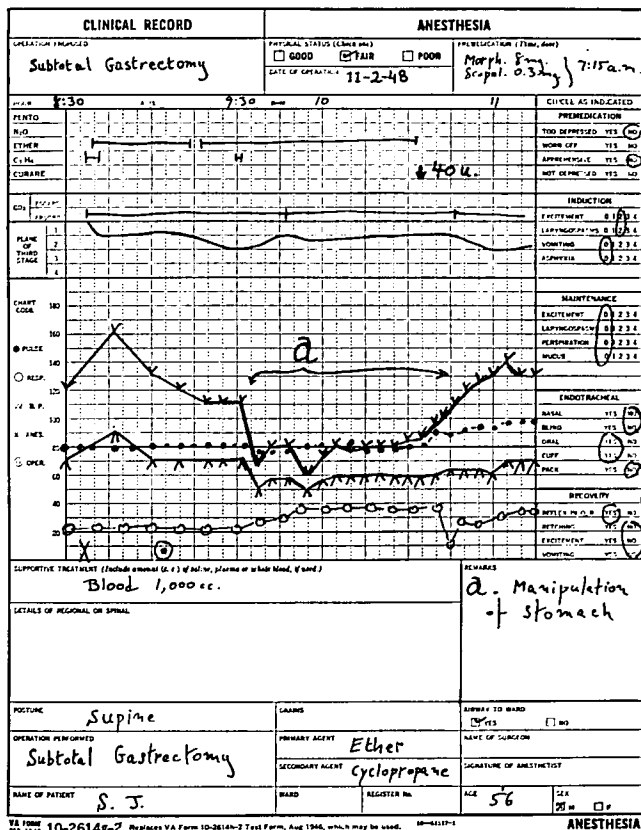


FIG. 5. Treatment of a celiac plexus during gastric resection.

Abdominal manipulation, at a, resulted in a decrease in the arterial blood pressure from 120 mm. systolic and 70 diastolic to 60 systolic and 50 diastolic, with maintenance of the pulse rate at 80 per minute. After the intravenous injection of 40 units of d-tubocurarine the arterial blood pressure returned to its previous level.

tained during the next five hours of operating (fig. 5). The patient's post-operative convalescence was uneventful.

Eleven other significant cases have been observed. All 12 patients were given d-tubocurarine and the results have been similarly effective in each instance.

Experimental investigations in 8 dogs corroborated the clinical observations as indicated in the following protocol. A dog weighing 10 kg. was given subcutaneously morphine sulfate 20 mg. and atropine sulfate 1 mg. Thirty minutes later, ether anesthesia was induced and maintained by means of the closed carbon dioxide absorption technic. An endotracheal airway was utilized. The right femoral artery was cannulated to register arterial blood pressure. The abdomen was opened through a longitudinal midline incision and the celiac plexus identified. The arterial blood pressure before stimulating the celiac plexus was 150 mm. systolic and 125 diastolic with a pulse rate of 144 per minute. Immediately following compression of the celiac plexus (fig. 6A) there was a fall in the blood pressure to 116 mm. systolic and 110 diastolic. The pulse rate also declined to 132 per minute. Following release of the compression of the celiac plexus the blood pressure and pulse rate returned to their original levels. A similar response followed on two other occasions. Twenty units of d-tubocurarine was given intravenously. This produced a slight fall in the blood pressure to 130 mm. systolic and 100 diastolic with a diminution in pulse rate to 104 per minute. Repetition of compression of the celiac plexus five minutes after the administration of the d-tubocurarine then gave a different response. Instead of a fall, there was a rise in the arterial blood pressure to 160 mm. and 132 diastolic. The pulse pressure and pulse rate remained unchanged (fig. 6B). Upon release of the compression of the celiac plexus, the previous level was reestablished.

It is imperative that the underlying mechanism for circulatory depression during abdominal surgery be determined if the use of curare is proposed. Curare will not remedy arterial hypotension resulting from shock, cardiac complications, or direct mechanical pressure on the large vessels in the abdomen. The last complication was involved in the following experience.

Case 4.—A 34-year-old man had an acute cholecystitis necessitating surgical intervention. His preoperative temperature was 104°, his pulse rate 118 per minute and the blood pressure 180 mm. systolic, 104 diastolic. He was given morphine sulfate, 10 mg., and scopolamine hydrobromide, 0.4 mg., hypodermically. An hour and twenty-five minutes later anesthesia was induced with cyclopropane. The patient's hypertension and tachycardia were sustained during the first hour of surgery. When the peritoneal cavity was entered an acutely inflamed gallbladder containing many stones was found. The surrounding area was protected by packing. Coincident with compression transmitted by retractors placed in the right abdomen there was a sudden decline in the arterial blood pressure from 200 mm. systolic and 122 diastolic to 130 mm. systolic and 92 diastolic whereas the pulse rate rose from 132 to 144 per minute. Twenty units




FIG. 6. Change in response in the arterial blood pressure owing to compression of the celiac plexus following the administration of d-tubocurarine in a dog during ether anesthesia. Upper tracing, arterial blood pressure. Lower tracing, time in second intervals.

a—Compression of the celiac plexus.

b—Release of compression.

A—Compression of the celiac plexus caused a fall in the arterial blood pressure from 150 mm. systolic and 125 diastolic to 116 systolic and 110 diastolic. The heart rate decreased from 144 to 132 per minute.

B—Compression of the celiac plexus five minutes after the injection of d-tubocurarine (2 units per kilogram) caused no change in pulse pressure or pulse rate with a rise in systolic arterial blood pressure from 130 to 160 mm.

of d-tubocurarine was injected intravenously and the same dose was repeated eight minutes later without change in the circulatory picture. The relative arterial hypotension continued for twenty-five minutes until the pressure in the abdominal cavity was removed by releasing the compression caused by retractors.

There was a sudden return of the arterial blood pressure to its previous level of 200 mm. systolic and 122 diastolic. It is not unlikely that the arterial hypotension in this case was not caused by compression of the celiac plexus but that it was the result of compression of some large vessels in the right upper quadrant.

Curare was found ineffective in the treatment of an arterial hypotension during gastric resection for a patient who may have developed a cardiac complication, as described in the following report.

Case 5.—A 52-year-old man suffered from cholecystitis. Cholecystectomy was proposed. His preoperative condition was complicated by syphilitic heart disease with hypertension; his systolic arterial blood pressure was 210 mm. and the diastolic 80. On the day of the operation he was given morphine sulfate, 10 mg., and scopolamine hydrobromide, 0.4 mg., hypodermically. An hour later, anesthesia was induced by the intravenous injection of 0.3 Gm. of pentothal sodium in a 2.5 per cent concentration. This was followed by cyclopropane and ether. Orotracheal intubation was accomplished without difficulty twenty minutes after anesthesia was begun. Just prior to induction of anesthesia, the arterial blood pressure was 130 mm. systolic and 60 diastolic with a pulse rate of 80 per minute. There was no change in the circulatory status produced by the induction of anesthesia. Twenty minutes after the start of the surgical operation, when abdominal exploration was begun, there was a sharp drop in the arterial blood pressure to 80 mm. systolic and 50 diastolic. The pulse rate also decreased from 80 to 42 per minute. Forty units of d-tubocurarine was injected intravenously. Five minutes later, the arterial pressure had declined further to a systolic of 60 mm. and a diastolic of 40 with continued bradycardia at a rate of 42 per minute. Surgical manipulations were suspended for five minutes but the circulation was not improved. Another 20 units of d-tubocurarine was injected intravenously and this resulted in respiratory arrest which was immediately controlled by artificial respiration. The arterial blood pressure remained at 60 mm. systolic and 40 diastolic while the pulse rate diminished to 34 per minute. Since there was no improvement from the cessation of surgical manipulations nor from the administration of curare, and since the patient was known to have syphilitic heart disease, the possibility of a heart block became evident. Because of the arterial hypotension and bradycardia, it was decided to inject 10 mg. of ephedrine sulfate intravenously. Three minutes later, the arterial blood pressure was 130 mm. systolic and 60 diastolic, and the pulse rate had increased to 72 per minute. Spontaneous respiratory movements were resumed in the next five minutes and surgical intervention was continued. The operation lasted another hour and a half without any apparent disturbance in circulation.

PELVIC REFLEXES

Stimulation of the pelvic nerve during operations on or about the rectum or other pelvic structures may result in two different types of disturbing reflexes. In the one referred to as the "pelvolaryngeal reflex," laryngeal spasm follows stimulation of the pelvic nerve. Administration of curare can prevent or remedy such a reflex. Therapeutic management with curare of a pelvolaryngeal reflex is described in the following case report.

CLINICAL RECORD		ANESTHESIA	
OPERATION PROPOSED Epididymectomy		PHYSICAL STATUS (ASA) <input checked="" type="checkbox"/> GOOD <input type="checkbox"/> FAIR <input type="checkbox"/> POOR	PREMEDICATION (Time, dose) Morph. 10 mg. } 8:00 a.m. Scopol. 0.4 mg. }
DATE OF OPERATION 1-31-49			
OPERATION TIME 9:00	10:00	11:00	CIRCLE AS INDICATED
PENTO	40u		PREMEDICATION
ETHN	40u		TOO DEPRESSED YES <input type="checkbox"/> NO <input checked="" type="checkbox"/>
C ₂ H ₆			WORN OFF YES <input type="checkbox"/> NO <input checked="" type="checkbox"/>
CURARE			APPREHENSIVE YES <input type="checkbox"/> NO <input checked="" type="checkbox"/>
			NOT SERVICED YES <input type="checkbox"/> NO <input checked="" type="checkbox"/>
CO ₂			INDUCTION
FLASK OF THIRD STAGE			EXCITEMENT <input type="checkbox"/> 2 2 2
			LARYNGEAL REFLEX <input type="checkbox"/> 2 2 2
			VOMITING <input type="checkbox"/> 2 2 2
			SPUNGE <input type="checkbox"/> 2 2 2
CHART CODE			MAINTENANCE
● PULSE			EXCITEMENT <input type="checkbox"/> 2 2 2
○ RESP.			LARYNGEAL REFLEX <input type="checkbox"/> 2 2 2
IV B.P.			PERSPICUOUS <input type="checkbox"/> 2 2 2
X ANCL.			MUCUS <input type="checkbox"/> 2 2 2
⊙ OPR.			ENDOTRACHEAL
			INSAL YES <input type="checkbox"/> NO <input checked="" type="checkbox"/>
			INFLD YES <input type="checkbox"/> NO <input checked="" type="checkbox"/>
			ORAL YES <input type="checkbox"/> NO <input checked="" type="checkbox"/>
			CUFF YES <input type="checkbox"/> NO <input checked="" type="checkbox"/>
			RAPE YES <input type="checkbox"/> NO <input checked="" type="checkbox"/>
			RECOVERY
			REFLEX IN O.R. YES <input type="checkbox"/> NO <input checked="" type="checkbox"/>
			RETURNING YES <input type="checkbox"/> NO <input checked="" type="checkbox"/>
			EXCITEMENT YES <input type="checkbox"/> NO <input checked="" type="checkbox"/>
			VOMITING YES <input type="checkbox"/> NO <input checked="" type="checkbox"/>
SUPPORTIVE TREATMENT (Include amount (c.c.) of saline, plasma or whole blood, if used)		REMARKS A. Traction on Cord and Testicle. b. Traction Released. c. Curare 40u. d. Curare 40u.	
DETAILS OF REGIONAL OR SPINAL			
POSITION Supine	LAGGERS	AIRWAY TO WARD <input checked="" type="checkbox"/> YES <input type="checkbox"/> NO	
OPERATION PERFORMED Epididymectomy	PRIMARY AGENT N ₂ O	NAME OF SURGEON	
NAME OF PATIENT L. O.	SECONDARY AGENT Pentothal 1.2 Gm.	SIGNATURE OF ANESTHETIST	
	WARD	REGISTER NO.	AGE 54 SEX M <input type="checkbox"/> F <input checked="" type="checkbox"/>

VA FORM 10-2614g-2 Replaces VA Form 10-2614b-2 Test Form, Aug. 1946, which may be used. 10-54117-1

ANESTHESIA

FIG. 7 Treatment of a pelvic cardiac reflex during an epididymectomy.

Manipulation was followed by decrease in the arterial blood pressure from 120 mm. systolic and 70 diastolic to 80 systolic and 62 diastolic (a). Cessation of surgical intervention was followed by a return of the arterial blood pressure. When manipulations were resumed the arterial blood pressure again diminished to 72 mm. systolic and 60 diastolic (b). Two minutes after the intravenous injection of 40 units of d-tubocurarine, (c) the arterial blood pressure rose to 120 mm. systolic and 72 diastolic.

Case 6.—A 45-year-old woman was to have repair of a cystocele and rectocele. One hour following preanesthetic medication with morphine sulfate, 10 mg., and scopolamine hydrobromide, 0.4 mg., anesthesia was induced by the intravenous injection of 0.3 Gm. of pentothal sodium in a 2 per cent concentration. Anes-

thesia was continued with cyclopropane. Fifteen minutes after the start of the operation, as the surgeons were manipulating the perineal structures the patient manifested severe crowing which persisted for fully ten minutes. Laryngoscopy revealed that the vocal cords were adducted in spasm with but brief periods of recoil on expiration. The arterial blood pressure rose, during this period, from 140 mm. systolic and 80 diastolic to 160 mm. systolic and 100 diastolic. The pulse rate was slightly increased from 74 to 90 per minute but the rhythm became irregular owing, possibly, to extra systoles. Fifty units of d-tubocurarine was injected intravenously. Thirty seconds after the injection there was a sudden cessation of the laryngeal spasm; the crowing ceased abruptly and laryngoscopy showed normal vocal cord function. The pulse rate diminished to 70 per minute and the rhythm became regular. The blood pressure declined to 130 mm. systolic and 80 diastolic. Surgical intervention was completed without further complication.

A second type of pelvic reflex is the "pelvocardiac reflex." Here, the efferent portion of the reflex is conveyed by way of the cardiac vagus to produce arterial hypotension and bradycardia. The following report describes such a reflex and demonstrates the favorable response to the administration of curare.

Case 7.—A 54-year-old man was undergoing an epididymectomy. Anesthesia was provided by the combined use of pentothal sodium intravenously and nitrous oxide with oxygen by inhalation. Preoperative arterial blood pressure was 110 mm. systolic and 72 diastolic with a pulse rate of 106 per minute. Soon after the start of the operation, following traction of the spermatic cord and pressure on the testis, there was a diminution in the arterial blood pressure to 80 mm. systolic and 62 diastolic. Cessation of surgical manipulation was followed by a return of the arterial blood pressure to its normal level. This level was maintained during the next ten minutes while no manipulations were in progress. An attempt to resume surgical operation following this lapse of time again resulted in arterial hypotension. Forty units of d-tubocurarine was given intravenously. Two minutes later the arterial blood pressure rose from 72 mm. systolic and 60 diastolic to 120 mm. systolic and 72 diastolic. This level was maintained during the next twenty minutes despite continued intermittent traction and pressure on the spermatic cord and testis. A second dose of 40 units of d-tubocurarine was followed by a rise in arterial blood pressure to 134 mm. systolic and 84 diastolic which was maintained for ten minutes and then gradually declined to 120 mm. systolic and 70 diastolic. This latter level was continued during the remainder of the operation (fig. 7).

DISCUSSION

The mechanism of action of curare in the production of muscular relaxation is said to be the prevention of the receptor substance of muscle from responding to acetylcholine (7). Since many autonomic synapses also are affected by the acetylcholine-choline esterase balance, it is conceivable that curare can interfere with synaptic transmission of the normal chemical mediator as it does at the myoneural junction.

It is significant to point out that the dose of curare or of d-tubocurarine necessary to abate the various autonomic reflexes herein de-

scribed is variable. This individual variation in the effective dosage of curare required is observed in like manner when the objective desired is muscular relaxation; for some patients 30 units suffice, for others 100 units is necessary. In the majority of cases, an amount of curare that produces intercostal paralysis is sufficient to depress active untoward autonomic reflexes. In several instances when the disturbance was pronounced it was necessary to give doses of d-tubocurarine that produced respiratory arrest. It is likely that individual variability exists in the acetylcholine-cholinesterase balance. The administration of premedicant and other drugs, and the pharmacologic effects of various anesthetic agents can alter chemical synaptic efficiency.

SUMMARY

Disturbing autonomic reflexes that may occur during surgical anesthesia may be alleviated by the administration of curare in doses that produce temporary intercostal paralysis.

Autonomic reflexes which have been found to respond to this treatment include the carotid sinus reflex, the vagal reflex, the celiac plexus reflex, the pelvolaryngeal reflex and the pelvocardiac reflex.

REFERENCES

1. Bernard, Claude: *Leçons sur les Effets des Substances Toxiques et Medicamenteuses*, ed. 2, Paris, J. B. Bailliere & Fils, 1857, p. 348.
2. Langley, J. N.: On Stimulation and Paralysis of Nerve Cells and Nerve Endings. Paralysis by Curari, Strychnine, and Brucine, and its Antagonism by Nicotine, *J. Physiol.* **52**: 247, 1918.
3. Burstein, C. L.; Jackson, A., and Rovenstine, E. A.: Effects of Curare on Autonomic Reflexes, *Proc. Soc. Exper. Biol. & Med.* **70**: 718, 1949.
4. Heymans, C.; Bouckaert, J. J., and Regnier, P.: *Le Sinus Carotidien*, Paris, G. Doin & Cie, 1933.
5. Burstein, C. L., and Rovenstine, E. A.: Circulatory Disturbances Reflexly Inaugurated by Stimulation of Celiac Plexus. Preliminary Report, *Arch. Surg.* **35**: 599-602 (Sept.) 1937.
6. Burstein, C. L., and Rovenstine, E. A.: Reflex Complicating Anesthesia during Abdominal Surgery, *Anesth. & Analg.* **17**: 134-143 (May-June) 1938.
7. Cullen, S. C.: *Anesthesia in General Practice*, The Year Book Publications, Chicago, 1946.

AMERICAN BOARD OF ANESTHESIOLOGY, INC.

The Secretary-Treasurer, Curtiss B. Hickcox, M.D., has announced that the national headquarters of the American Board of Anesthesiology, Inc., will be changed on August 1, 1950, from New York City to:

Hartford Hospital
80 Seymour Street
Hartford, Connecticut

All information and inquiries should be directed to the new location after August 1, 1950.