

CURRENT COMMENT AND CASE REPORTS

CURRENT COMMENT is a section in **ANESTHESIOLOGY** in which will appear invited and unsolicited professional and scientific correspondence, abbreviated reports of interesting cases, material of interest to anesthesiologists reprinted from varied sources, brief descriptions of apparatus and appliances, technical suggestions, and short citations of experiences with drugs and methods in anesthesiology. Contributions are urgently solicited. Editorial discretion is reserved in selecting and preparing those published. The author's name or initials will appear with all items included.

RETROPERITONEAL HEMORRHAGE AS A COMPLICATION OF LUMBAR PARAVERTEBRAL INJECTIONS: REPORT OF THREE CASES

Lumbar sympathetic block has become well established as a therapeutic, diagnostic and prognostic procedure for peripheral vascular disease of the lower extremities. As with injections elsewhere, occasional untoward events may occur. Fortunately, these are uncommon. We wish to call attention, however, to retroperitoneal hemorrhage as a complication and suggest a method for reducing its incidence and severity.

The most commonly employed technic for lumbar sympathetic block is as follows: skin wheals are raised 5 cm. lateral to the midline at the level of the upper third of the lumbar spinous processes or directly opposite the interspaces. A 4-inch needle is inserted through each wheal perpendicular to the skin surface until the transverse process is encountered (3 to 5 cm. deep to the skin); the needle is then redirected medially, either cephalad or caudad to the transverse process, and inserted more deeply until the vertebral body is contacted, after which it is advanced about 2 to 2.5 cm. along the body. This brings the point close to the sympathetic trunk. Two to four needles are used, the sites extending from the first to the fourth lumbar levels. Procaine, 5 to 10 cc. of a 0.5 per cent or 1 per cent solution (or equivalent doses and concentrations of other agents) is deposited through each needle following a careful aspiration test to avoid intravascular injection (1, 2, 3, 4, 5, 6, 7).

Hemorrhage as a result of lumbar paravertebral injections is not a surprising occurrence if the anatomy of the lumbar region is kept in mind. The lumbar sympathetic chains lie on the anterolateral aspect of the vertebral bodies and, hence, in close relationship to the aorta and inferior vena cava with their branches and tributaries. Of these, the lumbar arteries and veins are especially vulnerable in their winding course about the vertebral bodies where they directly underlie the sympathetic trunks (fig. 1). Difficulty during sympathectomy is sometimes experienced when these vessels are torn. The fact that blood vessels are frequently entered is manifested by the common appearance of blood at the hub of one or more block needles during their placement. In the majority of such cases the bleeding is spontaneously arrested and no troublesome complications develop.

Sometimes, however, such bleeding is likely to continue unchecked, producing severe symptoms because of the formation of a retroperitoneal hematoma. Derangement of the normal clotting mechanism is particularly likely to set the stage for such prolonged bleeding. In 2 of the cases to be described the prothrombin time was abnormally increased by the administration of anticoagulants (figs. 2 and 3).

Case 1. A 56-year-old white man was admitted to the hospital on July 29, 1949, with the complaint of pain in the left calf

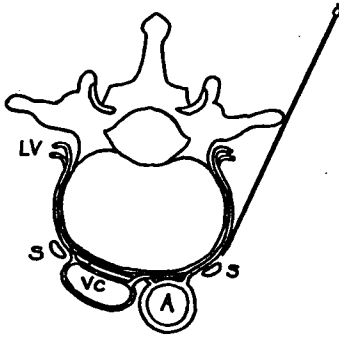


FIG. 1. Diagrammatic cross-section through the lumbar area showing the relationship of the sympathetic nerve trunks to blood vessels. LV, lumbar artery and vein; S, sympathetic nerve trunk; VC, inferior vena cava; A, aorta.

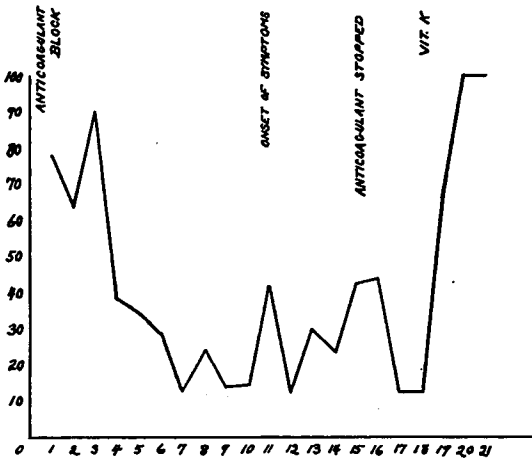


FIG. 2. Case of R. L. P. Graphic course of events in hospital. Ordinate represents values of prothrombin time (Quick Method) in per cent of normal; abscissa is marked off in hospital days.

and difficulty in walking, both of three weeks' duration.

Physical examination revealed that the patient was well developed and nourished. There was tenderness in the left calf and

Homans' sign was positive on the left. A diagnosis was made of thrombophlebitis of the left leg.

Treatment, consisting of hot packs and intensive anticoagulant therapy with hepa-

rin and dicumarol was begun the evening of the day of admission. The next morning (July 30, 1949) the surgeon performed a lumbar sympathetic block on the left with three needles.

Ten days (August 9) after the injection the patient complained of tenderness and swelling along the course of the spinal muscles. An ice bag was applied to the area. Two days later (August 11) he was weak and became dizzy and faint when he went to the bathroom. Pain, tenderness and swelling over the left paravertebral area persisted and were treated with hot compresses, analgesics and sedatives. The symptoms were aggravated by moving about and pain was also present in the left thigh and leg.

A spot film of the lumbar spine was taken on August 8, 1949, and was too small to show the psoas shadows. Urinalysis on admission was negative. No blood counts or hematocrit readings were taken. Daily determinations of the prothrombin time were performed. Two days after the block

the prothrombin time was 39 per cent of normal and it continued to fall to even lower levels where it hovered at the onset of symptoms. Anticoagulant therapy was discontinued on August 13 and vitamin K was administered on August 16, 1949. On August 30, 1949, eleven days after the onset, the patient felt much improved.

Case 2. A 39-year-old white man was admitted on May 13, 1949, with the complaint of pain in the right leg of two days' duration. Sudden, severe pain in the right calf was first noted while the patient was lifting a heavy object onto a truck. It was aggravated by walking and was described as a muscle cramp. A similar pain had been noted two weeks earlier.

Physical examination disclosed a cool, pale, right foot and marked tenderness of the right calf. A tentative diagnosis was made of thrombophlebitis with arterial spasm.

On the morning following admission anticoagulant therapy, 3 cc. of heparin in Pitkin's menstruum and 300 mg. of dicu-

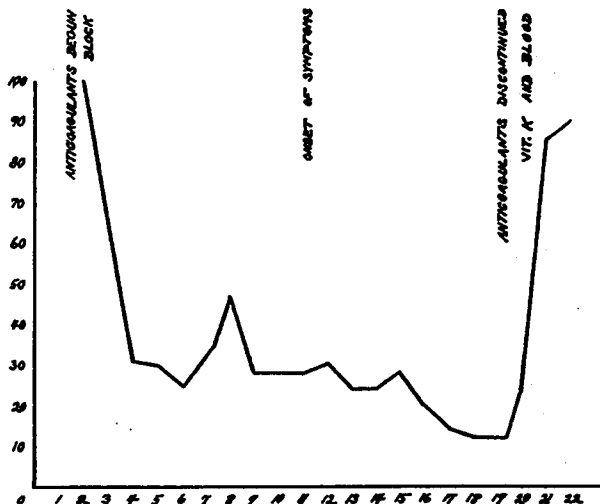


FIG. 3. Case of D. B. Graphic course of events in hospital. Ordinate represents values of prothrombin time (Quick Method) in per cent of normal; abscissa is marked off in hospital days.

marol, was started. On the afternoon of the same day a paravertebral lumbar sympathetic block was done on the right with three needles. No injection was made through the third needle because of the appearance of blood during aspiration. Following the block no increase in skin temperature was observed, although definite drying of the skin took place. The patient stated that his leg felt much better.

Two days later (May 16, 1949) a caudal block was performed to determine the difference in response of the two legs to sympathetic blocking. The results demonstrated an occlusion of the right popliteal artery as evidenced by coldness and pallor of the right foot and absence of pulsations of the dorsalis pedis and posterior tibial arteries; the left foot was normal. A sharp line of demarcation was present a few inches above the right ankle

proximal to which the skin color and temperature were normal. Later that day femoral arteriography was attempted without success, the dye having extravasated into the tissues.

Administration of anticoagulants was continued and the patient seemed to improve somewhat until the eleventh day (May 23, 1949) when a severe, cramping pain developed in the right costovertebral angle with radiation into the thigh and leg. This pain continued for one week, during which time he complained bitterly and appeared acutely ill. Throughout this interval he ran a fever of 100° . One week after the onset of these symptoms the urine was grossly bloody. The hematocrit reading was 30 and the prothrombin time 12.5 per cent (fig. 3). A soft, fluctuant, tender mass was palpable in the right lower quadrant. An intravenous pyelogram

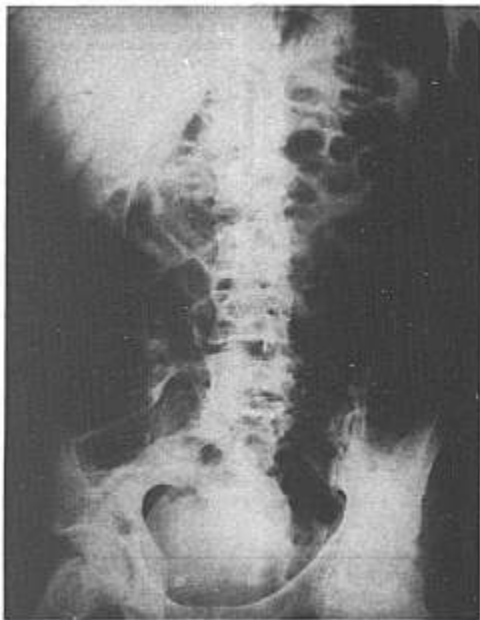

FIG. 4.

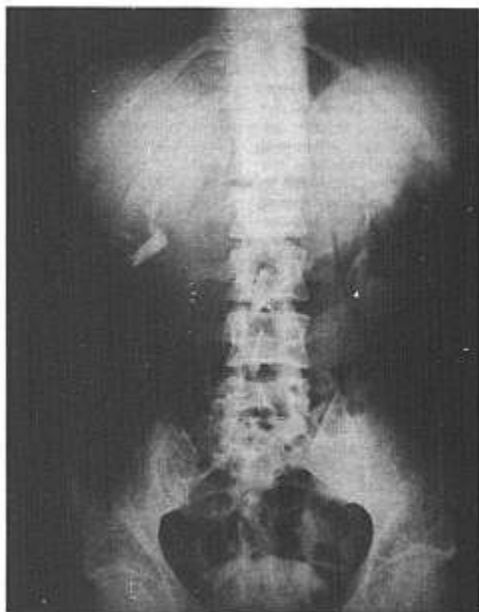


FIG. 5.

FIGS. 4 and 5. X-rays of D. R. (Case No. 2) showing distorted psoas shadow on the right and displacement of abdominal viscera to the opposite side.

showed distortion and enlargement of the right psoas shadow (figs. 4 and 5) with displacement of the distended intestine to the opposite side of the abdomen. Administration of dicumarol was stopped and vitamin K and whole blood were given, after which the urine cleared and the patient's condition steadily improved.

At the time of discharge there was minor discomfort in the right inguinal region and slight weakness of the right leg. Arterial pulsations in the right foot could not be palpated, although it was warm. The diagnosis was occlusion of the right popliteal artery, of undetermined causes.

Case 3. A 32-year-old white man was admitted to the hospital on December 12, 1948. A roentgenogram revealed a fracture of the left talus, sustained in an auto-

mobile accident the day before entry. Closed reduction and application of a plaster cast were done on December 13, 1948, under pentothal anesthesia. The next day (December 14) the following findings were present: swelling of the left foot and ankle, inability to move the toes and numbness and cyanosis of the toes. The cast was removed, with no improvement. The leg was placed in an ice pack and elevated, and a sympathetic block was performed under spinal anesthesia. The circulation improved after this procedure. Sensation returned, but the ankle remained moderately swollen and discolored from the hematoma. On December 16, 1948, under general anesthesia open reduction was done and a cast applied. Before the patient was awakened, a left lum-

bar sympathetic block was performed with 2 per cent intracaine in oil, with the hope of preventing postoperative circulatory impairment.

Two weeks later (December 30, 1948) the patient complained of constant pain in the lumbar region and of extreme tenderness in that area. An intravenous pyelogram was done and was within normal limits. On December 31, 1948, the temperature was 103° and was accompanied by increased back pain and tenderness in the lumbar area and costovertebral angles. The abdomen was slightly distended and mildly tender, but there was no rigidity. Urinalysis showed 8 to 10 white blood cells and many bacteria; there were no urinary symptoms. The white count and hemoglobin were normal. Penicillin was given, but pain continued in the back. An intravenous pyelogram on January 4 disclosed good function of both kidneys and slight lateral displacement of the right ureter; the roentgenologist's impression was possible hematoma in the retroperitoneal space. On January 5, 1949, the temperature was 101°. Tenderness persisted in the lumbar region and in the costovertebral angle. The abdomen was tympanitic. Two days later (January 7) his condition was improved and the temperature was normal.

The diagnosis was simple, comminuted fracture of the left talus, with dislocation and possible retroperitoneal hematoma. The patient was discharged, asymptomatic on January 22, 1949.

Although a definite diagnosis of retroperitoneal hematoma was not made in this case, the symptoms and course were so suggestive that it could not be ruled out.

COMMENT

These cases demonstrate the occasional train of events following paravertebral injections. Doubtless there are others that escape notice, perhaps largely because of the relatively long interval between the block and the onset of symptoms, so that cause and effect may not be apparent.

Unnecessary trauma in the placement of the needles should be avoided because of the increased risk of injuring the deeply situated vessels in close proximity to the sympathetic nerve trunks.

It is the belief of the authors and of others that the use of anticoagulant therapy contraindicates the use of lumbar sympathetic blocks (8). Similarly, an abnormally prolonged clotting time from other causes should also interdict block therapy because of the possibility of subsequent uncontrollable bleeding.

SUMMARY

Three cases have been presented in which retroperitoneal hematoma occurred as a complication following lumbar paravertebral sympathetic block. Two of the patients received anticoagulant therapy, during which the prothrombin time fell to low levels.

These complications can be minimized by avoiding paravertebral injections when the clotting mechanism is deranged. Anticoagulant therapy is a contraindication to blocks.

REFERENCES

1. Pitkin, G. P.: *Conduction Anesthesia*, Edited by Southworth, J. L. and Hingson, R. A., Philadelphia, J. B. Lippincott, 1946.
2. White, J. C., and Smithwick, R. H.: *The Autonomic Nervous System*, New York, The Macmillan Company, 1941.
3. Flothow, P. G.: *Diagnostic and Therapeutic Injections of Sympathetic Nerves*, Am. J. Surg. 14: 591-604 (Dec.) 1931.
4. Ochsner, A., and DeBakey, M.: *Treatment of Thrombophlebitis by Novocain Block of Sympathetics; Technique of Injection*, Surgery 5: 491-497 (April) 1939.
5. Ruth, H. S.: *Diagnostic, Prognostic and Therapeutic Nerve Blocks*, J. A. M. A. 102: 419-424 (Feb. 10) 1934.
6. Lundy, J. S.: *Clinical Anesthesia*, Philadelphia, W. B. Saunders, 1942.
7. Seldon, T. H.: *Regional Anesthetic Procedures Around Vertebral Column*, Anesthesiology 2: 669-685 (Nov.) 1941.
8. Ochsner, Alton: Personal communication to the author, 1950.

L. O. LEARNED, M.D.,
*Chief of Anesthesiology,
 Department of Anesthesiology,
 Veterans Administration Hospital,
 Salt Lake City, Utah,*
 AND R. F. CAROON, M.D.,
*Department of Anesthesiology,
 University of Utah College of Medicine,
 Salt Lake City, Utah*