

THE FUNCTIONAL ANATOMY OF THE LUNG *

LEROY D. VANDAM, M.D.

Philadelphia, Pennsylvania

Received for publication July 23, 1951

A GREAT many new and important observations regarding pulmonary function have recently been made. It has been the author's experience, however, that many reports dealing with the physiology of the lungs neglect the anatomic substratum on which function depends. While anatomy has been underemphasized by some, it is worth while to recall that the lungs possess an anatomic structure which not only subserves efficient respiration but provides an efficient defense against infection and injury as well. It seems imperative then that function of the lungs be reviewed in an anatomic setting, since nowhere, with one possible exception (1), is there readily at hand a review of this nature. In the discussion which follows, the anatomic structures of the lung will be considered individually.

The Primary Lobule.—Before entering into a discussion of specific features of the lung, reference will first be made to the basic unit of the lung known as the primary lobule. This is advisable in order to establish the terminology which will henceforth be recurrent in this review. The concept of the primary lobule is the result of the painstaking reconstructions of William Snow Miller (2) and early forebears. It will be seen in figure 1 that the bronchi repeatedly divide until the small end-portion of the air-conducting system, the terminal bronchiole, is formed. This is an important landmark, for respiratory gas exchange is carried out beyond this point. Alveoli are present in the walls of the next sub-division, the respiratory bronchiole, and there is subsequent partition into alveolar ducts, atria, saccules and finally alveoli. The primary lung lobule comprises an alveolar duct and all of its offshoots. Primary lobules are grouped to give rise to larger units, secondary and tertiary lobules, which become macroscopically visible. A larger entity of significance is the lung segment. In figure 2, which is Jackson and Huber's schema of the lung segments (3), it will be apparent that several segments constitute a lobe of the lung. For the pathologist, bronchologist, radiologist and clinician the identification and designation of the lung segments have provided a common ground for understanding mutual problems.

* From the Department of Anesthesiology, Hospital of the University of Pennsylvania and the Harrison Department of Surgical Research, University of Pennsylvania School of Medicine, Philadelphia, Pennsylvania.

The Larynx.—Ordinarily the larynx is not mentioned in connection with pulmonary physiology. Occupying a commanding position at the entrance to the air passages, the larynx might well be implicated in respiratory exchange. Most people call the larynx the voice box, yet, to paraphrase Negus (4), a moment's reflection will reveal that many species with no voice at all have elaborately developed larynges. In his monograph on the comparative anatomy of the larynx, Negus pointed out that the larynx is primarily a valve of the respiratory tract. Originally a sphincter to guard the pulmonary outgrowth of the pharynx against inundation, the adult human larynx has evolved to the point where it is a muscular organ having the capacity for constriction and dilatation (fig. 3). Analysis of the functions of the

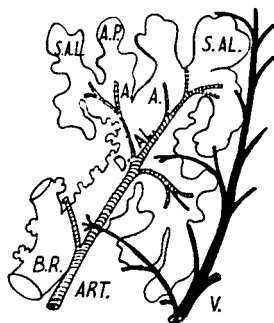


FIG. 1. Schematic longitudinal section of the lung beyond the terminal bronchiole. A primary lobule comprises an alveolar duct (D.A.L.), atria (A), alveolar sacculles (S.A.L.) and pulmonary alveoli (A.P.). A respiratory bronchiole (B.R.) with alveoli in its walls usually branches into several ducts. It can be seen that the pulmonary artery (ART) is always closely associated with the bronchial passages while the pulmonary vein (V) is situated as far removed from the bronchioles as possible. (Redrawn from William Snow Miller: *The Lung*, second edition, Courtesy of Charles C Thomas, Publisher, Springfield, Illinois.)

larynx uncovers the role played in respiration, circulation and maintenance of intrathoracic pressure.

Those who have directly observed the laryngeal aditus will remember that the vocal cords fluctuate with respiratory movements. During inspiration, the glottis is widened and during expiration narrowed. Acting as a narrow portal, the larynx participates in the development of the negative intrapleural pressure which is so vital for cardiac filling and output. A relative obstruction to the entry of air provides for a greater suction effect with consequent dilatation and filling of the intrathoracic vessels. In expiration, the reverse takes place with compression and passage onward of the blood already in the vessels. Whether the movements of the vocal cords assist in the

process of gas distribution in the alveoli is as yet an unanswered question. It is said that a tracheostomy will result in an elevation of the respiratory rate, perhaps on the basis of carbon dioxide accumulation. Too many intangibles enter into the tracheostomy situation for conclusions to be drawn, but it would be interesting to make controlled respiratory and circulatory measurements in such a case.

From the standpoint of defense against infection and the regulation of intrathoracic pressure, the larynx has other functions. For a cough

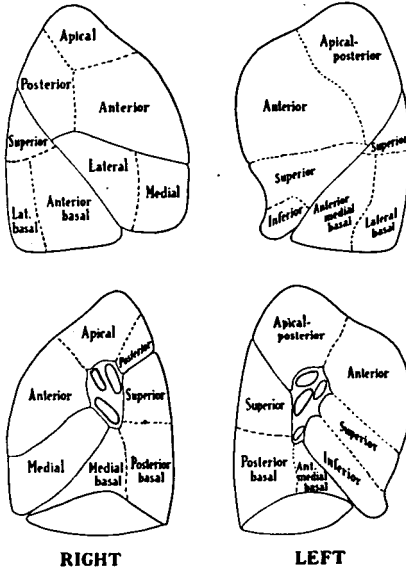


FIG. 2. The bronchopulmonary segments shown in both lateral (above) and mediastinal (below) aspects. (Reprinted by permission of the authors and publishers from Jackson, C. L., and Huber, J. F.: Correlated Applied Anatomy of the Bronchial Tree and Lungs with a System of Nomenclature, *Dis. Chest* 9: 319-326 (July) 1943.)

to be productive, air is entrapped and positive pressure accumulated before the expulsive efforts of the respiratory muscles are instituted. After a short inspiration, the laryngeal sphincter is closed, whereupon the intrinsic and extrinsic muscles of the chest forcibly contract. This is the Valsalva maneuver which eventuates in an elevated intrathoracic pressure. In coughing, the larynx suddenly opens and the accumulated positive pressure fulfills the purpose of the tussive reflex. To raise intrathoracic pressure for bearing down purposes,

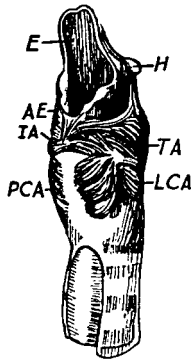


FIG. 3. Dissection of the larynx of a man to illustrate the musculature. The dilator components consisting of the posterior cricoarytenoid muscle (PCA) and the sphincteric group of muscles are pictured. In the latter classification are the aryepiglottic (AE), interarytenoid (IA), lateral cricoarytenoid (LCA) and thyroarytenoid (TA) muscles. H = hyoid bone and E = epiglottis. (Redrawn from "Comparative Anatomy and Physiology of the Larynx," V. E. Negus, Grune and Stratton, Inc.)

the larynx is kept closed to allow the abdominal muscles to contract against a fixed diaphragm. The dire consequences of prolonged positive intrathoracic pressures have been evident in several reports concerning "bedpan deaths" (5). Beecher (6) has recently called attention to the relative ineffectiveness of cough when an endotracheal tube maintains the patency of the larynx or when the chest is open during thoracic surgery. Similarly, a patient with a tracheostomy finds it difficult to expel secretions.

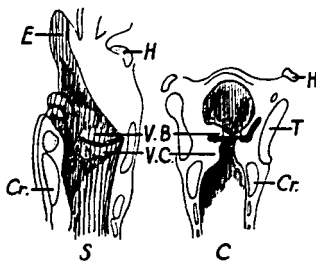


FIG. 4. Sagittal (S) and coronal (C) sections of the larynx of a man to illustrate the valves. The vocal cords (V.C.) act as inlet valves while the ventricular bands (V.B.) or false cords perform as outlet valves. The latter are more muscular, hence more efficient. CR = cricoid cartilage, T = thyroid cartilage, and H = hyoid bone. (Redrawn from "Comparative Anatomy and Physiology of the Larynx," V. E. Negus, Grune and Stratton, Inc.)

The stronger valvular portion of the larynx is made up of the ventricular bands or so-called false cords. That this is so may be apparent in figure 4. The ventricular bands are capable of effectively denying entrance to the glottis as any anesthesiologist who has witnessed laryngospasm will readily testify.

The Tracheobronchial Tree.—The tracheal tree originates just below the cricoid cartilage of the larynx approximately at the level of the sixth cervical vertebral body. The point of bifurcation of the trachea is marked by the angle of Louis or the fourth to fifth thoracic vertebral body. Not only is the right main stem bronchus more directly continuous with the trachea, but it is larger so that it is not uncommon for foreign bodies to lodge or endotracheal tubes to be advanced into the right side of the bronchial tree. Both trachea and bronchi have in their walls partial cartilaginous rings, the apparent function of which is to maintain patency and allow for changes in caliber at the same time. Without support, the air passages might collapse during inspiration and there would be little rationale for the presence of smooth muscle unless the rings were incomplete. If the cartilages are weakened as in prolonged pressure from goiter, it sometimes happens that the trachea collapses after thyroidectomy.

The respiratory passages are, with a few exceptions, lined from the nostrils to terminal bronchiole by a ciliated columnar epithelium with many interspaced mucous secreting goblet cells. A good many measurements of ciliary activity have been made, but those of Hilding (7) are most intriguing and appropriate from a practical viewpoint. Hilding has demonstrated in the intact frontal sinus of the dog as well as in isolated hens' tracheas that cilia moving plugs of mucus are capable of generating negative pressures up to 40 mm. of water. Occluding masses of mucus were passed through these tracheas by ciliary action, while the lower end was connected with a water manometer. Under the continued traction of cilia, mucous plugs were attenuated into fine films which burst easily with slight manipulation of the experimental preparation. The latter observation corresponds nicely with the clinical observation that atelectasis is sometimes relieved by relatively inconsequential therapeutic means. Certainly, lack of ciliary force is not to be underestimated as factor in atelectasis. In the administration of anesthesia possible depressant effects of pre-operative medication and anesthetics on ciliary activity must be reckoned with in the prevention of postoperative pulmonary complications. Virulent bacteria and aspirated necrotizing intestinal or gastric contents by destroying the protective respiratory epithelium with its cilia may clearly bring about overwhelming infection. This is probably in part the explanation for the origin of acute laryngotracheal bronchitis, or the aspiration pneumonia seen after periods of unconsciousness.

The Musculature of the Lung.—Although there are repeated clinical

reminders of the fact, few think of the lungs as muscular organs. In 1822 Reisseisen (8), carefully dissected the smooth muscle of the trachea and others (2, 9) have since elaborated on his description of the smooth muscle. The basic plan of distribution is that of a branched tubular network, neither longitudinal nor circular, extending outward around the tracheobronchial tree (fig. 5) as far as the alveoli. There is associated with the muscle an interwoven elastic layer (fig. 5) so that in essence a myo-elastic coating for the air passages exists in the walls between the mucosa and cartilage. Although the muscle is most developed and concentrated about the larger passages, it is far greater in proportion to the size of the lumen of the bronchiole. In the latter

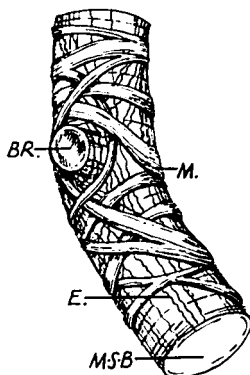


FIG. 5. Smooth muscle (M) and elastic fibers (E) at a place where a branch (BR) is given off the main stem bronchus (M.S.B.). The smooth muscle with a spiral type of arrangement can effect changes in the length and caliber of the bronchus. The elastic fibers are essentially longitudinal in direction. (Redrawn from William Snow Miller: *The Lung*, second edition, courtesy of Charles C Thomas, Publisher, Springfield, Illinois.)

location the so-called bronchospasm of asthma or the bronchospastic response to histamine, irritant or parasympathomimetic drugs can literally shut off air exchange. Even if smooth muscle does not extend over the alveoli as does the elastic tissue, it extends as far as the alveolar sacs where in cross section it resembles tiny sphincters.

The physiology and pharmacology of the muscle of the lungs has been somewhat confused by conflicting animal experiments but, in general, this muscle reacts as does smooth muscle elsewhere in the body. Indeed, if it is remembered that the lungs are in the embryo an outgrowth of the foregut, the lung muscle proves to be similar to that of the bowel. Movements of the bronchi can be observed with ease through the bronchoscope (10), as well as radiographically with opaque

media. There are transmitted movements from the heart and great vessels and twisting and turning movements to accommodate the lungs to varying capacities of the thorax. During inspiration, the bronchi increase in length and breadth. Part of the increased length may be the result of descent of the hili of the lung, but the major change is the aftermath of smooth muscle relaxation and the pull of negative intrapleural pressure. In expiration a reversal takes place with consequent diminution in caliber. Whether these changes in caliber are passive as some assert or neurogenic in origin is of small moment. Morphologically, the smooth muscle is abundantly innervated by the autonomic nervous system. Furthermore, it is alleged that the bronchi evince peristaltic movements which approach a state called tracheobronchial "vomiting" when foreign matter is being expelled.

With the foregoing résumé a number of practical points come to mind. For one thing, as Macklin (9) pointed out, it may be absurd to speak of the anatomical dead space as a fixed entity based on cast preparations in cadavers. It is a variable space and Douglas and Haldane (11) have shown that it can be augmented as much as four times during strenuous exercise. From a pharmacologic standpoint, since the bronchial muscles are active in cough, it seems reasonable to assume that opiates affect the cough reflex at several levels. A well known observation is that opium derivatives, after a brief stimulatory phase, inhibit smooth muscle. Hence morphine has the inherent possibility of dulling central perception, depressing the medullary phase of the cough reflex, and peripherally inhibiting cilia and smooth muscle. The bronchial muscles are under autonomic nervous regulation and there is abundant evidence, both clinical and experimental, that sympathomimetic drugs create bronchodilatation and parasympathomimetics the reverse (9). In the latter connection, the anesthetist is aware that several agents, cyclopropane, curare and pentothal for example, tend to foster bronchoconstriction.

Innervation of the Lung.—The nervous supply to the lung is of importance with the advent of attempts to interrupt the nerves either temporarily or permanently in disease states. Nervous influence in bronchial asthma has always been more than suspect, while diffuse vasospasm of neurogenic origin has been held responsible for some of the signs and symptoms of pulmonary embolism (12). Recently, the problem of interrupting afferent pain pathways has confronted those who feel obliged to treat sufferers with inoperable pulmonary disease (13). At the present time, results of operation for the several entities mentioned have been inconclusive (14). The fault may well lie in the nerve distribution which does not lend itself readily to dissection without compromising other vital functions.

In general, the innervation of the lungs is almost identical with that of the heart (15). Sympathetic motor fibers arise in the first five thoracic segments and proceed to the pulmonary plexus by way of

the sympathetic ganglions or cardiac nerves. Parasympathetic motor fibers from the vagus arising below the inferior laryngeal nerve in a number of filaments also traverse the mediastinum to reach the pulmonary plexuses. The latter, which are found anterior and posterior to the hili, not only receive a dual supply but are interconnected with one another unilaterally and bilaterally as well as with the cardiac plexuses. Familiarity with the complex distribution of the autonomic nervous system clarifies in part the difficulty encountered in completely denervating the lungs or in selectively sectioning either autonomic division. One of the most interesting reports is that of Klassen (16) who sectioned the vagus on one side with the result that pain sensation from the tracheobronchial passages as well as the cough reflex was unilaterally obtunded. However, when both vagi were severed below the inferior laryngeal nerves there arose the undesirable sequela in the gastrointestinal tract usually associated with extensive vagotomy. Furthermore, bronchospasm in asthmatic patients thus treated was not alleviated. Since autonomic ganglions are to be found throughout the interstitial tissues, it is not unlikely that bronchospasm is the result sometimes of intrinsic reflexes. A similar situation prevails in the denervated smooth muscle of the bowel. To summarize what seems to be fairly certain about nervous activity, it can be said that the sympathetics dilate the bronchi, constrict the bronchial arteries and decrease secretion while the parasympathetics perform oppositely (17).

The Blood Supply to the Lungs.—The dual blood supply to the lungs has always intrigued the anatomist and lately the physiologist. The pulmonary arteries with a low blood pressure subserve for respiratory gas exchange, while the bronchial arteries with a systemic pressure are concerned with the nutritional maintenance of the interstitial tissues. In the latter category are the trachea, bronchi, great vessels, nerves and supporting elements. Luschka (18) designated the pulmonary arteries as the vasa publica and the bronchials as the vasa privata or nutria.

The pulmonary arteries, like the cerebral and coronary vessels, seem to be very little under neurogenic influence, but more under the regulation of circulating metabolic gases like oxygen and carbon dioxide. Recent experiments suggest that concentrations of the same gases in the alveoli may regulate the caliber and resistance to passage of blood through pulmonary vessels (19). If this is so, the absence of cyanosis when there is blood flow through nonaerated pulmonary tissue is explainable. On the whole, pulmonary arterial tone is low, a circumstance which provides for a little resistance in the lesser circuit and a greater ability to adapt to changing blood volumes. Drinker (20) has pointed out that the lungs, because of their aeriform nature, lack the capacity to develop a pressure in the interstitial tissues which in other parts of the body decreases the tendency toward edema formation. It is fortunate, from the latter standpoint, that the hydrostatic

driving force in the pulmonary capillaries is relatively low, mean pressure equal to 10 mm. of mercury, and counteracted by a blood oncotic pressure equal to 25 to 30 mm. of mercury. In other words, the tendency toward fluid release from the capillaries is overbalanced by forces which effect the opposite result (fig.6). Furthermore, the lymphatics of the lung, with a distribution down to the terminal bronchioles, play a great part in the resorption of fluid (21).

The bronchial arteries have a diverse anatomic origin. Usually the left lung receives two of these vessels and the right one, from the aorta, internal mammary or intercostal arteries. To reiterate, the normal purposes of the bronchial arteries is nutritive for the interstitial tissues. Therefore, the usual extent of distribution is no farther than

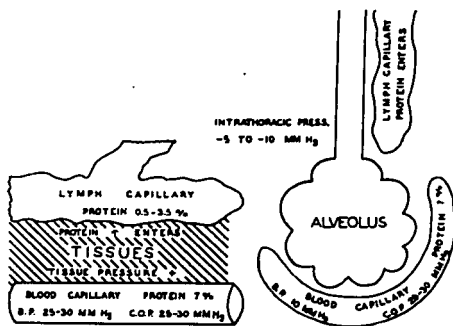


FIG. 6. The forces which influence fluid exchange in the tissues and in the alveolus of the lung are illustrated. Fluid accumulation in the lung is aided by the absence of tissue fluid tension and by the attraction of negative intrathoracic pressure. Fortunately, the hydrostatic pressure forcing fluid out of the capillaries is more than counterbalanced by oncotic pressure. (Reprinted by permission of the author and publishers from Cecil Kent Drinker: Pulmonary Edema and Inflammation, Cambridge, Mass., Harvard University Press, 1945).

the terminal bronchiole (2). Bronchial veins excluding those to the mediastinum drain into the pulmonary venous system, and thence to the left auricle. The possibility that bronchial venous contamination of oxygenated pulmonary venous blood might lead to arterial oxygen unsaturation has been the impetus for a number of studies on the bronchial circulation (22). Moreover, since the bronchial vessels are under neurogenic regulation and the mean arterial pressure is high, it has been thought that this system of vessels might be implicated in paroxysmal types of pulmonary edema of central origin. It is admittedly difficult to measure bronchial artery blood flow in man and not much easier in animals. However, Bruner and Schmidt (22) have estimated the maximal flow through the bronchial arteries of the dog

to be not more than 1 per cent of the cardiac output and in average circumstances much less. The minor nature of this figure suggests that there is little likelihood of implicating the blood flow of the bronchial artery in the genesis of paroxysmal pulmonary edema. Similarly, contamination of pulmonary venous blood with the above estimated bronchial blood flow is hardly sufficient to change significantly the oxygen tension of arterial blood.

In pathologic situations the bronchial artery achieves a greater significance. Wounds of the lung or pathologic erosions involving the bronchial artery are more likely to be fatal because of existing systemic blood pressure in these vessels. It is small wonder that pulmonary arterial occlusion by embolus seldom eventuates in frank infarction for the bronchial arteries maintain nutrition (23). As Liebow and co-workers have shown in most pathologic occlusions of the pulmonary artery, the bronchial arteries by extensive collateral

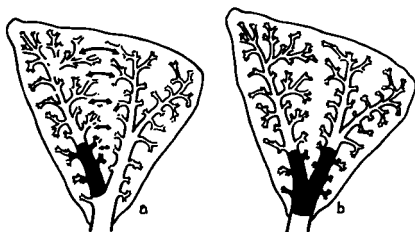


FIG. 7. Collateral ventilation in a lobe of the lung. In figure "a" where there is obstruction in a lobular bronchus collateral ventilation is effective while in "b" blockage of the main bronchus prevents collateral ventilation. [Reprinted by permission of the authors and publishers from Alley, R. D., and Lindskog, G. E.: *Pharmacologic Factors Influencing Collateral Respiration; Possible Relation to the Etiology of Pulmonary Complications*, *Annals of Surg.* 128: 497-508 (Sept.) 1948.]

production take over the respiratory function of the pulmonary artery (24). In some types of congenital heart disease with cyanosis in which there is pulmonary atresia, stenosis or reduced pulmonary arterial blood flow, extensive collateral circulation from the bronchial and other systemic vessels often supplies the lungs with blood for oxygenation (25).

Collateral Ventilation in the Lungs.—There is another defensive mechanism in the lungs which has not yet been accorded general recognition, and that is the concept of collateral ventilation. During the course of experimental studies of atelectasis Van Allen and Lindskog (26) noticed that obstruction of smaller bronchi did not, as expected, uniformly produce lobular or segmental collapse. Measurements of air flow soon revealed that the blocked pulmonary substance was being

“fed” collaterally by air from adjacent lobules (fig. 7). Further investigation established the fact that collateral ventilation, as it was designated, was present during quiet respiration to the extent that at least 10 per cent of the ordinary ventilation to the obstructed tissues was supplied. Others (27) have not only measured collateral ventilation in human beings, but have estimated its magnitude to be at least 40 per cent of the normal air flow. It is apparent that there must be communication between peripheral units of the lung for maintenance of the aforementioned type of ventilation. On an embryologic basis it was not to be expected that collateral channels would be present for the lungs develop by a process of repetitive budding and subdivision. Most morphologists, including Miller (2), now agree that there are such channels instead of the artefacts originally thought to be demonstrated (28). Probably the pathways for collateral exchange are identical with Kohn's pores known to pathologists for a long time.

The clinical significance of collateral air flow may be at least as important as collateral circulation. Apparently lung function is preserved not only in the circulatory but in the respiratory sphere as well. The effectiveness of cough is enhanced by collateral intralobar air transfer and any obstruction in the collateral channels can be expected to result in an extension of atelectasis and infection. It is probable that many measures directed toward minimizing postoperative pulmonary complications conserve collateral ventilation. Thus, avoidance of tight abdominal binders, minimizing wound pain, encouraging cough, deep breathing and early ambulation all abet the lungs' natural defenses.

SUMMARY

The foregoing review has been an attempt to present succinctly some of the aspects of the anatomic substratum of pulmonary function and defense. As stated at the outset, it was the author's purpose to gather in one place practical information which was not readily available elsewhere. Inherent in this discourse has been the theme that pulmonary function is intimately related to structure. The lungs possess a wealth of natural defenses. Most measures designed to prevent pulmonary complications merely support the lung's natural ability to maintain a normal status.

REFERENCES

1. Churchill, E. D.: *Segmental and Lobular Physiology and Pathology of Lung*, *J. Thoracic Surg.* 18: 279-293 (June) 1949.
2. Miller, W. S.: *The Lung*, Springfield, Ill., Charles C Thomas, 1947.
3. Jackson, C. L., and Huber, J. F.: *Correlated Applied Anatomy of Bronchial Tree and Lungs with System of Nomenclature*, *Dis. Chest* 9: 319-326 (July) 1943.
4. Negus, V. E.: *The Comparative Anatomy and Physiology of the Larynx*, New York, Grune and Stratton, 1949.
5. McGuire, J., Green, R. S., et al.: *Bed Pan Deaths*, *Am. Prac. & Digest of Treat.* 1: 23-28 (Jan.) 1950.

6. Beecher, H. K.: Principles, Problems, Practices of Anesthesia for Thoracic Surgery, *Arch. Surg.* **62**: 206-238 (Feb.) 1951.
7. Hilding, A. C.: Some Further Experiments in Production of Negative Pressure in Trachea and Frontal Sinus by Ciliary Action, *Ann. Otol. Rhin. & Laryng.* **54**: 725-738 (Dec.) 1945.
8. Reissisen, F. D.: Ueber den Bau der Lungen, Berlin, 1822.
9. Macklin, C. C.: The Musculature of Bronchi and Lungs, *Physiol. Rev.* **9**: 1-60 (Jan.) 1929.
10. Jackson, C.: Bronchoscopy and Esophagoscopy, ed. 2 Philadelphia, W. B. Saunders Company, 1927.
11. Douglas, G. D., and Haldane, J. S.: Capacity of Air Passages Under Varying Physiological Conditions, *J. Physiol.* **45**: 235-238 (Oct.) 1912.
12. deTakats, G.; Beck, W. D., and Fenn, G. K.: Pulmonary Embolism—An Experimental and Clinical Study, *Surgery* **6**: 339-367 (Sept.) 1939.
13. Morton, D. R.; Klassen, K. P., and Curtis, G. M.: Clinical Physiology of Human Bronchi; Pain of Tracheobronchial Origin, *Surgery* **28**: 699-704 (Oct.) 1950.
14. Phillips, E. W., and Scott, W. J. M.: Surgical Treatment of Bronchial Asthma, *Arch. Surg.* **19**: 1425-1456 (Dec.) 1929.
15. Braeucker, W.: Der Brustteil des Vegetativen Nervensystems und Seine Klinisch—Chirurgische Bedeutung, *Beitr. Klin. Tuberk.* **56**: 1-65, 1927.
16. Klassen, K. P.; Morton, D. R., and Curtis, G. M.: Physiological Evaluation of Vagus Section for Bronchial Asthma, *J. Thoracic Surg.* **20**: 552-570, (Oct.) 1950.
17. deBurgh, D.: Physiology of the Bronchial Vascular System, *Harvey Lect.* **31**: 235-236, 1935.
18. Luschka, H.: Die Anatomie des Menschen, I Abt. II. Tubingen, 1863.
19. Dirken, M. N. J., and Heemstra, H.: Alveolar Oxygen Tension and Lung Circulation, *Quart. J. Exper. Physiology* **34**: 193-211, 1948.
20. Drinker, C. K.: Pulmonary Edema and Inflammation, Cambridge, Massachusetts, Harvard University Press, 1945.
21. Courtice, F. C.: Absorption of Fluids from Lungs and Pleural Cavities, *Proc. Royal Australasian Coll. Physicians* **4**: 77-83 (July) 1949.
22. Bruner, H. D., and Schmidt, C. F.: Blood Flow in Bronchial Artery of Anesthetized Dog, *Am. J. Physiol.* **148**: 648-666 (March) 1947.
23. Bruner, H. D.: The Bronchial Artery in Pulmonary Infarction, *North Carolina M. J.* **8**: 306-310 (May) 1947.
24. Liebow, A. A.; Hales, M. R.; Harrison, W.; Bloomer, W., and Lindskog, G. E.: Genesis and Functional Implications of Collateral Circulation of Lungs, *Yale J. Biol. & Med.* **22**: 637-650 (July) 1950.
25. Bing, R. J.; Vandam, L. D., and Gray, F. D., Jr.: Physiological Studies in Congenital Heart Disease; Results of Preoperative Studies in Patients with Tetralogy of Fallot, *Bull. Johns Hopkins Hosp.* **80**: 121-141 (Feb.) 1947.
26. Van Allen, C. M.; Lindskog, G. E., and Richter, H. G.: Collateral Respiration; Transfer of Air Collaterally Between Pulmonary Lobules, *J. Clin. Investigation* **10**: 559-590 (Aug.) 1931.
27. Baarsma, P. R.; Dirken, M. N. J., and Huizinga, E.: Collateral Ventilation in Man, *J. Thoracic Surg.* **17**: 252-263 (April) 1948.
28. Loosli, C. G.: Inter-alveolar Communication in Normal and Pathological Mammalian Lungs, *Arch. Path.* **24**: 743, 1937.

AMERICAN COLLEGE OF ANESTHESIOLOGISTS

The written examinations of the American College of Anesthesiologists will be held in various locations on April 19, 1952. The oral examination will be held in Chicago, June 14, 1952.