

CONTRIBUTIONS OF ELECTROCARDIOGRAPHY TO ANESTHESIA FOR CHEST SURGERY * †

KATHERINE FISHER, M.D., AND TRAVIS WINSOR, M.D.

Los Angeles, California

Received for publication July 16, 1951

SINCE the original description of a lobectomy for carcinoma of the lung by Thomas and John Jones (1) in October 1931 and the first pneumonectomy for carcinoma by Graham (2) in September 1933, anesthesiologists have had opportunity to study respiratory physiology in a great variety of situations. Prior to this time few anesthetics were given for operations within the chest; thus, the field of anesthesiology did not involve many operations which altered cardiac physiology. With the increase in the number of surgical procedures performed within the thorax, it has become evident that anesthesiologists must understand certain aspects of cardiology in order to treat adequately the altered functions of the heart which occur frequently during chest surgery. This has been clearly pointed out by Burstein, LoPinto and Newman (3) who found evidence of electrocardiographic changes in 73 per cent of 57 patients during endotracheal intubation. The same authors reported an incidence of electrocardiographic abnormalities occurring in 68 per cent of 109 cases during anesthesia using cyclopropane or cyclopropane and ether. The changes included nodal rhythm, first degree A-V block, ventricular or sinus tachycardia and auricular fibrillation. Taylor (4) reported that 6.5 per cent of 41,690 patients receiving cyclopropane showed clinical evidence of such cardiac arrhythmias as tachycardia, bradycardia and auricular fibrillation. This incidence probably would have been greatly increased had electrocardiograms been recorded.

It is to the anesthesiologist's credit that cardiac emergencies during anesthesia generally are handled successfully when it is considered that treatment is based entirely upon the pulse rate, blood pressure and the clinical appearance of the patient. Yet a few dramatic cardiac crises which have not been successfully treated occasionally occur. The occurrence of these crises has given rise to numerous questions which

* From the Department of Anesthesiology and Thoracic Surgery, The Nash Cardiovascular Foundation, Hospital of the Good Samaritan and the Department of Medicine, University of Southern California Medical School, Los Angeles, California. The surgery was performed by Dr. John C. Jones, Dr. Joseph L. Robinson and their associates. Gratitude is expressed for their suggestions and encouragement throughout these studies.

† Presented at the meeting of the California Society of Anesthesiologists, San Diego, California, April 2-4, 1951.

might have been answered had an electrocardiogram been recorded during the surgical procedure. Some of these questions are as follows: (a) Was death due to sino auricular block resulting from excessive vagal tone? If so, the electrocardiogram might have revealed the presence of an A-V block which would have been a warning of impending death. Treatment with atropine or ephedrine given early might have prevented this condition (5). (b) Was death due to ventricular fibrillation? If ventricular fibrillation had been present prompt treatment with quinidine (6), pronestyl † (7) or electrical stimulation (8) might have proved life-saving. (c) Is a slow pulse rate as obtained by palpation a sinus bradycardia or is there coupling due to ventricular premature contractions so that only every other beat is felt by the anesthesiologist? In the former case atropine (9) would probably be effective in restoring sinus rhythm and in the latter quinidine (10) or pronestyl is indicated. (d) When should a retractor placed on the heart be removed? This can readily be answered by observing dramatic changes in the electrocardiogram indicating damage to the epicardium or compression of a coronary artery. (e) Has cardiac damage occurred during surgery which cannot be determined from the pulse rate, blood pressure and appearance of the patient, for example, a first degree heart block, right or left bundle branch block or intraventricular block? The recognition of these states is important as certain drugs, such as digitalis, quinidine and pronestyl, increase the conduction defect and should be given cautiously in the presence of these conditions.

One striking example in which proper treatment based upon an electrocardiographic diagnosis may mean the difference between life and death can be given: the pulse of the patient may reveal a slow cardiac rate. This may be caused in one instance by a third degree heart block with idioventricular rhythm in which the rhythm of the heart and life of the patient are dependent upon an irritable focus in the ventricle. The slow rate, on the other hand, may be the result of multiple premature contractions with every other beat being transferred to the wrist as previously described. In the latter incidence, quinidine or pronestyl would restore the pulse to normal rhythm; however in the former these medications would cause cardiac depression, thereby removing the irritable focus, upon which the rhythm of the heart depended and the case would end fatally.

It is the purpose of this paper to determine whether or not an electrocardiogram taken before, during or immediately after chest surgery would reveal useful information which could not be obtained from the blood pressure, pulse rate and clinical appearance of the patient and to determine whether or not a rational plan of therapy could be devised for the preoperative preparation, operative and immediate postoperative treatment of patients undergoing chest surgery.

† Pronestyl (*p*-amino-*N*-(2 diethylaminoethyl) benzamide hydrochloride) $C_{12}H_{21}H_2O \cdot HCl$ Squibb.

METHODS AND MATERIALS

One hundred and two patients whose ages averaged 42 years (range, 14 to 70) were studied (table 1). These included 26 patients treated by lobectomy, 23 of whom had pulmonary tuberculosis. There were 18 pneumonectomies, 9 of which were for pulmonary tuberculosis and 6 for carcinoma. Twelve thoracotomies were performed, 11 of which were for inoperable carcinoma. There were 10 coarctations of the aorta, 8 instances of patent ductus arteriosus and 23 miscellaneous disease states. Sixty per cent of the patients had cardiac disease with some degree of congestive heart failure prior to surgery. The majority of the patients with pulmonary tuberculosis had been bedfast for eight

TABLE 1
MORTALITY RATE OF PATIENTS UNDERGOING ANESTHESIA WITH AND WITHOUT
AID OF ELECTROCARDIOGRAM

With Electrocardiogram	Cases	Without Electrocardiogram	Cases
Lobectomies	10	Lobectomies	16
Thoracotomies	7	Thoracotomies	5
Coarctations	7	Coarctations	3
Patent ductus arteriosus	6	Patent ductus arteriosus	2
Pneumonectomies	5	Pneumonectomies	13
Mediastinal tumors	2	Mediastinal tumors	3
Diaphragmatic hernias	6	Decortications	3
Extrapleural pneumolysis with paraffin plumbage	2	Hemothorax due to spontaneous rupture of pleural adhesions	1
Pericardiectomies	1	Esophagectomy with esophago- gastrotomy	1
Pericardial cyst	1	Hamartoma	1
First stage Smithwick	1		
Large bowel resection	1		
Simple mastectomy	1		
Bone flap	1		
Lumbar sympathectomy	1		
		Total	50
Total	52	Mortality	6%
Mortality	0		

months; however, an occasional patient had been bedridden for ten years. Of the 102 patients, 52 were studied electrocardiographically before, during and, in special instances, after surgery. The remainder of the patients served as controls. Electrocardiograms were recorded using the Sanborn Visocardiette. During surgery the instrument was operated just outside the surgery door to avoid an explosion hazard. Frequent tracings were made throughout the progress of the operation. Lead II was used routinely unless there were changes which could be explained better by other leads. Anesthesia consisted of pentothal and curare for intubation, followed by ether and oxygen. Cyclopropane was avoided because of its tendency to increase cardiac irritability which may produce serious arrhythmias and death.

RESULTS

The mortality rate of 52 patients anesthetized with, and 50 subjects anesthetized without electrocardiographic aid were studied (table 1). All patients anesthetized under electrocardiographic control survived the surgical procedure and the hospital period, while 6 per cent anesthetized without electrocardiographic control succumbed. The previous mortality rate for chest surgery in 688 consecutive cases by the same group was 4 per cent. It is believed that the lowered mortality rate encountered in patients anesthetized under electrocardiographic control was due to better therapy which resulted from a knowledge of existing cardiac abnormalities which would otherwise not have been detected.

Electrocardiographic abnormalities occurring preoperatively are shown in table 2. The electrocardiogram was abnormal in 33 of the 52 patients and knowledge of these abnormalities influenced the pre-

TABLE 2
ELECTROCARDIOGRAPHIC ABNORMALITIES RECORDED PREOPERATIVELY

	Cases	%
Coronary insufficiency	13	39.40
Left ventricular strain	13	39.40
Partial A-V block	2	6.06
Ventricular extrasystoles	4	12.12
Right bundle branch block	1	3.03
Total	33	

operative therapy in all cases. Thirteen of the 52 had coronary insufficiency. These patients received aminophylline, $1\frac{1}{2}$ grains every four hours for twenty-four hours and 3 grains one hour before surgery. In selected cases $7\frac{1}{2}$ grains was administered by rectal suppository. Thirteen had left ventricular strain, all of whom received full digitalizing doses or two-thirds of a digitalizing dose of digitoxin. Two patients had partial A-V block. These patients were given atropine or banthine to determine whether or not the block was functional or organic. If functional, 100 mg. of banthine was given orally one hour before surgery. Pronestyl and quinidine were avoided if possible when the tracing showed the presence of a conduction disturbance such as an A-V block. Four subjects had ventricular extrasystoles. These patients were given quinidine, 3 grains every four hours for eighteen hours and 6 grains one hour before surgery or pronestyl, 500 mg. every four hours for eighteen hours before operation.

Electrocardiographic abnormalities developing during anesthesia for chest surgery are shown in table 3. Abnormalities occurred in 35 of 52 patients. Sixty-four abnormalities of ten different types were observed. Sinus tachycardia occurred in 32.8 per cent of electrocardiographic abnormalities. This was diagnosed when the cardiac

rate was greater than 110 beats per minute, the pacemaker being located within the sinus node. Cardiac rates as high as 155 were encountered. The causes of sinus tachycardia were multiple and included cardiac strain (as often occurred while clamping the aorta), hemorrhage, tracheal obstruction (from purulent or nonpurulent exudate, or pieces of tumor), surgical shock, retraction of the heart, swinging mediastinum, traction on the hilum, coronary insufficiency, myocardial infarction occurring during operation, infection, toxemia and other causes. The treatment of sinus tachycardia was directed at removing the cause. Digitalis was used to slow the rate when the tachycardia was due to cardiac failure.

S-T segment shifts constituted 26.3 per cent of the abnormalities. S-T segment shifts were often marked and typical; however, at times they were difficult to evaluate. An attempt was made to differentiate

TABLE 3
ELECTROCARDIOGRAPHIC ABNORMALITIES OCCURRING DURING ANESTHESIA
(52 ELECTROCARDIOGRAMS)

Type of Abnormality	Number	% of Total
Sinus tachycardia (rate over 110)	21	32.80
S-T segment shifts—not including those due to digitalis	17	26.40
Left axis deviation of QRS complexes due to ventricular strain	7	10.90
Ventricular extrasystoles	6	9.40
Nodal rhythm	5	7.80
Wandering pacemaker	3	4.70
Auricular fibrillation	2	3.20
Auricular ectopic beats	1	1.60
Ventricular tachycardia	1	1.60
Ventricular fibrillation	1	1.60
Total	64	100%

S-T segment shifts due to digitalis, myocardial strain, myocardial injury, tachycardia and large auricular T waves from shifts secondary to changes in the size of the QRS complexes. Shifts caused by digitalis were characterized by short Q-T intervals and saucer-shaped S-T segments. These shifts were often seen after administration of 1.2 mg. of digitoxin twenty-four hours before surgery but were seldom seen after administration of two-thirds of this dose. Shifts due to ventricular strain were characterized by a long Q-T interval, the T wave being opposite to the major deflection of the QRS complex with slight convexity of the segment in the same direction as the QRS complex. Shifts caused by injury were recognized by a prolonged Q-T interval with a monophasic type of action current or by coving. Segment shifts due to tachycardia were associated with a rapid cardiac rate and were not present when the rate was slowed. Secondary T waves were recognized by their association with QRS complexes of unusually large size. In this series 17 of 64 abnormalities were S-T

POSTERIOR INFARCT DEVELOPING DURING
REPAIR OF DIAPHRAGMATIC HERNIA

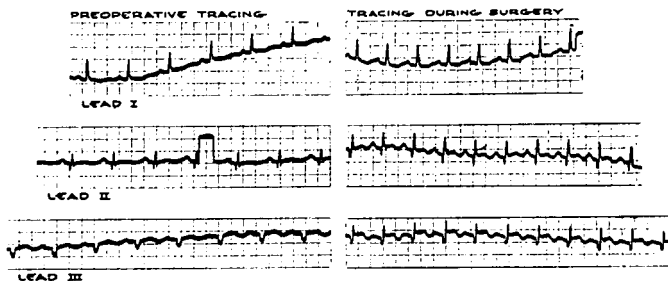
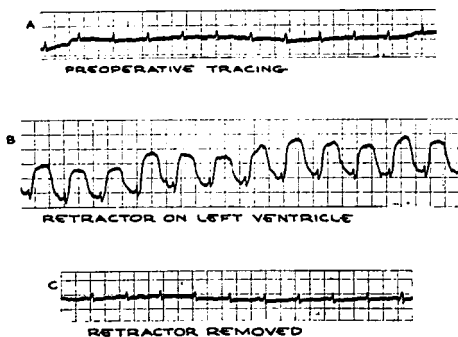


FIG. 1.

segment shifts due to causes other than digitalis. Eight of these were due to tachycardia or auricular T waves or were secondary, while 3 were probably due to subendocardial injury, one to posterior myocardial injury, 2 to anterior myocardial injury and 3 to ventricular strain.

S-T segment shifts due to an acute posterior myocardial injury associated with posterior infarction are demonstrated in the electrocardiogram of a 64 year old woman who was operated on for an hiatus hernia as shown in figure 1. The preoperative electrocardiogram was suggestive but not diagnostic of an old posterior myocardial infarct.

EFFECT OF TRAUMA TO LEFT VENTRICLE
DURING REPAIR OF COARCTATION OF AORTA*



* ALL TRACINGS ARE LEAD I

FIG. 2.

Surgery was uneventful except for the electrocardiographic findings which showed elevated S-T segment shifts in leads II and III with coving. This indicated injury to the posterior surface of the heart. There were no cardiac symptoms for one week, at which time a severe attack of coronary insufficiency with precordial pain, sweating and pallor occurred which was relieved by nitroglycerin. It is thought that this patient should have benefited materially by cardiac therapy administered immediately in the postoperative period. This brings up the possibility of myocardial infarction precipitated by surgery which would be unaccompanied by pain or other cardiac symptoms because of its occurrence during anesthesia.

S-T segment shifts due to an acute anterior epicardial injury are demonstrated in figure 2 by the electrocardiogram of a 19 year old

EFFECT OF SURGICAL REPAIR OF PATENT DUCTUS ARTERIOSUS
ON A NINETEEN YEAR OLD BOY

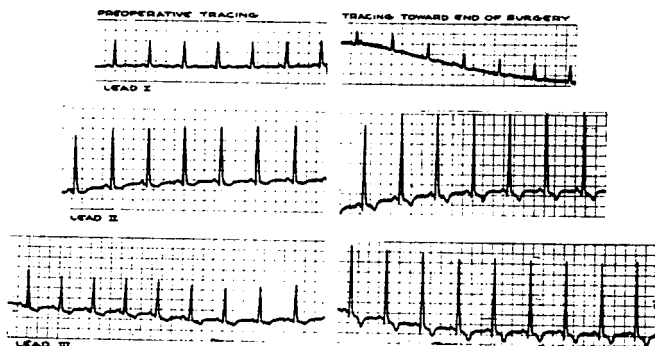


FIG. 3.

woman who was operated on for coarctation of the aorta. The preoperative electrocardiogram was essentially within normal limits (fig. 2A). The heart was retracted with the Robinson cardiac retractor, which was placed on the anterolateral surface of the left ventricle for approximately fifteen minutes, during which time positive S-T segment shifts developed which were of the monophasic type (fig. 2B). Approximately one minute after release of the retractor the electrocardiogram had returned to normal (fig. 2C).

Left axis deviation of the QRS complexes typical of left ventricular strain occurred in 7 of 52 patients. A typical tracing consisted of high voltage of the QRS complexes with discordant J, S-T segment and T wave of typical configuration. Left axis deviation of the QRS complexes occurred frequently as a result of change of body position,

movement of the heart or shift of the mediastinum. These were not included in the tabulated results as left axis deviation due to such causes was distinguished from left ventricular strain. Of those cases in which strain developed during operation 3 were associated with patent ductus arteriosus, 3 with coarctation of the aorta and one with a diaphragmatic hernia. The electrocardiogram of a 19 year old boy operated on for patent ductus arteriosus is shown in figure 3. The preoperative tracing showed evidence of left ventricular enlargement, indicated by high voltage of the QRS complexes with S-T segments and T waves characteristic of this condition. With the completion of surgery the QRS complexes in leads II and III had increased more than 25 per cent in amplitude with the appearance of deeply inverted T

EFFECT OF PRONESTYL ON MULTIFOCAL VENTRICULAR ECTOPIC BEATS DUE TO DIGITALIS

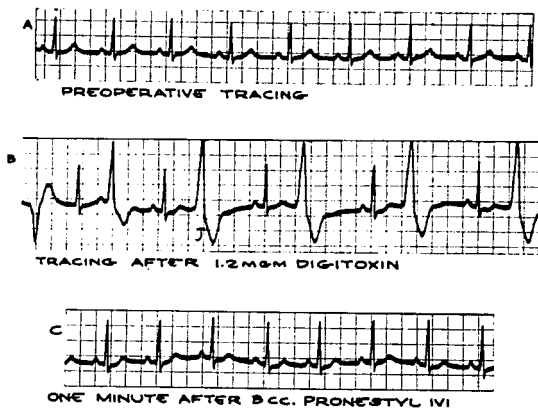


FIG. 4.

waves. It is thought that the electrocardiographic finding of acute left ventricular strain may precede cardiac failure and thus may be an important guide to proper therapy.

Ventricular extrasystoles constituted 9.4 per cent of the electrocardiographic abnormalities. In one instance these were multifocal and followed digitalization (fig. 4). Pronestyl, 3 cc., was injected intravenously which resulted in normal sinus rhythm within one minute after completion of the injection. Ventricular ectopic beats commonly occurred during cardiac manipulation. Patients having ventricular premature contractions before operation continued to have this arrhythmia in most cases. Pronestyl did not invariably eliminate the ectopic beats

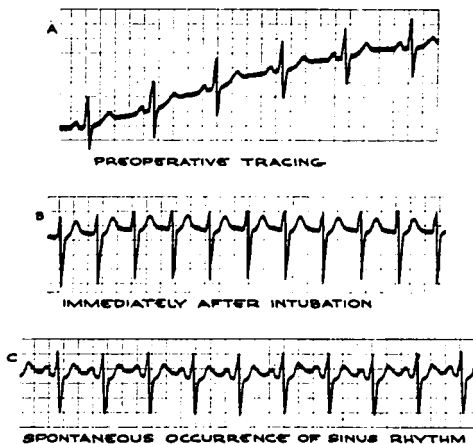
EFFECT OF INTUBATION
ON CARDIAC RHYTHM

Fig. 5.

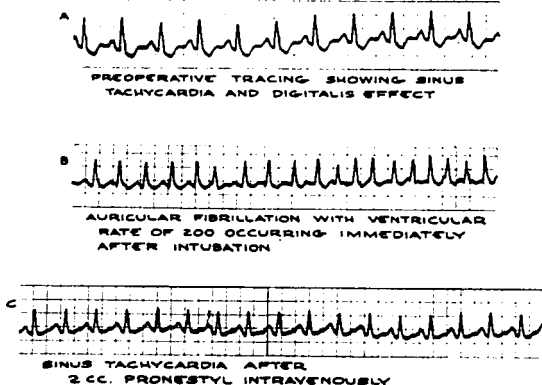
AURICULAR FIBRILLATION WITH RAPID
VENTRICULAR RESPONSE REVERTING TO
SINUS TACHYCARDIA WITH PRONESTYL

Fig. 6.

in these patients. On the other hand ectopic beats arising during the course of the surgical procedure usually responded more readily to this type of therapy.

Nodal rhythm constituted 7.8 per cent of the electrocardiographic abnormalities. In one instance this occurred immediately after intubation (fig. 5). Normal sinus rhythm returned spontaneously, making specific medication unnecessary. In the remainder of the cases nodal rhythm, lasting only a short period of time, occurred toward the end of the operation.

Wandering pacemaker constituted 4.7 per cent of the abnormalities. No specific treatment was administered for this condition.

EFFECT OF CEDILANID ON CARDIAC RATE IN A PATIENT WITH AURICULAR FIBRILLATION OCCURRING DURING SURGERY

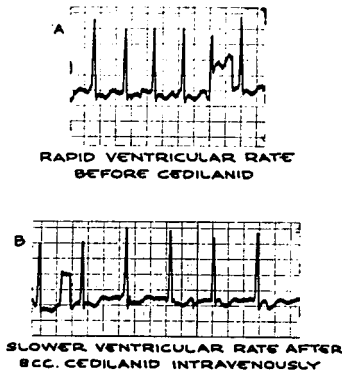


FIG. 7.

Auricular fibrillation constituted 3.2 per cent of the abnormalities, the ventricular rates being 155 and 200, respectively. In each instance the rhythm was reverted to normal sinus rhythm after the intravenous injection of 2 cc. of pronestyl (fig. 6). This is of particular interest because of the poor response of auricular fibrillation to this drug in the unanesthetized patient. This similarly occurs with intravenous administration of procaine which is generally effective in the anesthetized, and rarely effective in the unanesthetized patient. Cedilanid, 8 cc. in divided doses, administered to the undigitalized fibrillating patient was often effective in reducing the cardiac rate (fig. 7).

Auricular ectopic beats constituted 1.6 per cent of the abnormalities and were considered evidence of auricular irritability.

**EFFECT OF PRONESTYL
ON VENTRICULAR TACHYCARDIA DEVELOPING
DURING SURGERY FOR PATENT DUCTUS ARTERIOSUS**

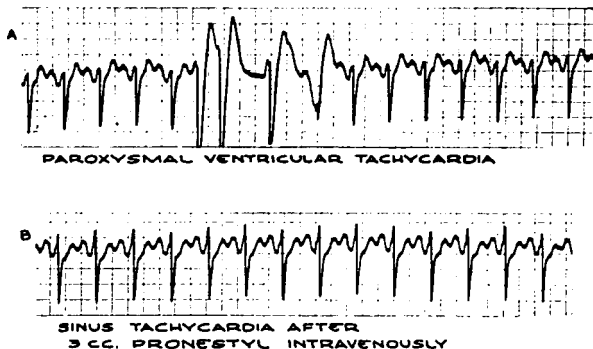


Fig. 8.

**EFFECT OF OPERATION WITHIN THE CHEST
ON THE ELECTROCARDIOGRAM IN A CASE
OF ESOPHAGECTOMY AND ESOPHAGOGASTROSTOMY**

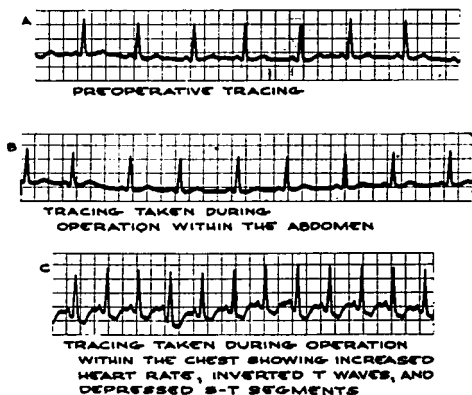


Fig. 9.

Ventricular tachycardia constituted 1.6 per cent of the abnormalities. These were controlled with 3 cc. of pronestyl intravenously (fig. 8).

The importance of an electrocardiogram recorded during chest surgery as compared with the importance of that recorded during surgery which produces less cardiac strain, for example abdominal surgery, is illustrated by tracings recorded on a patient in whom an esophagectomy and esophagogastrostomy were performed (fig. 9). The preoperative tracing and the one taken during the abdominal operation were quite normal. On the other hand a tracing during the chest surgery was quite abnormal as evidenced by inversion of T waves, depression of S-T segments and doubling of the cardiac rate.

VASOVAGAL RESPONSE WITHOUT BANTHINE PREOPERATIVELY

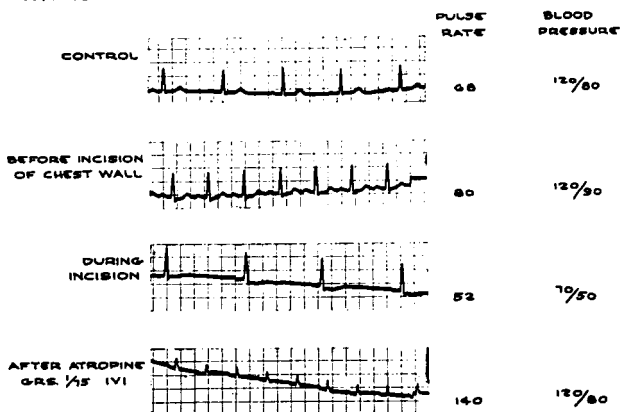


Fig. 10.

The vasovagal (11) attack was studied in 40 per cent of the 102 patients in whom it occurred (fig. 10). A drop in blood pressure associated with a slowing of the pulse rate which is thought to be due to overstimulation of the vagus is commonly spoken of as vasovagal or vagovagal reflex (12) and many times is serious or may be fatal. It was significantly more frequent when hypertension was present, occurring in 77 per cent of 29 subjects with hypertension as compared with 25 per cent of 73 nonhypertensive patients. An attempt to control this reflex with atropine given preoperatively was made but large doses were necessary to depress the vagus sufficiently to control the vagovagal reaction. This caused a rapid pulse rate in some patients which made

**MODIFIED VASOVAGAL RESPONSE
FOLLOWING 100 MG. BANTHINE ORAL PREOPERATIVELY**

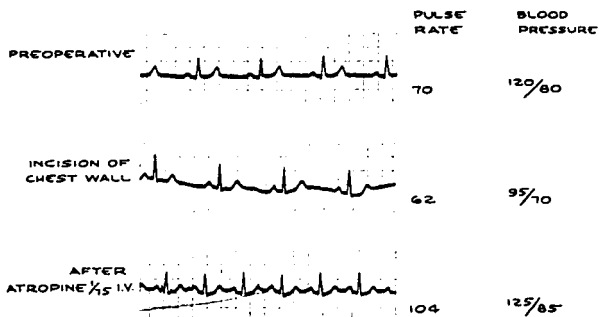


FIG. 11.

the drug undesirable for routine preoperative medication. Bantnine § (13), on the other hand, appeared to have certain advantages for it is presumed to block not only the vagus at the myoneural junction, but has some depressing action on the sympathetic synapses at the ganglions, resulting in a relatively slight increase in pulse rate rather than a severe tachycardia as occurred often from atropine. In most patients bantnine, 100 mg., was given one hour before surgery. This reflex was usually entirely blocked or modified with this dosage of bantnine. When the response was modified, the fall in blood pressure and pulse rate was less severe and less precipitous and occurred in a smaller percentage of the cases than in the controls (fig. 11). Since using bantnine routinely and digitalis when indicated, few vagovagal reflexes have occurred.

Electrocardiographic abnormalities developing postoperatively occurred in 6 of the 52 patients studied (table 4). These consisted of auricular fibrillation in 3, multiple ventricular premature contractions in 2 and nodal tachycardia in 1. Nodal tachycardia occurred in the first few hours postoperatively. The continuous postoperative treat-

TABLE 4

ELECTROCARDIOGRAMS RECORDED POSTOPERATIVELY

Auricular fibrillation	3
Multiple ventricular premature contractions	2
Nodal tachycardia	1
	—
Total	6

§ Bantnine (β -diethylaminoethyl xanthene-9-carboxylate methobromide), G. D. Searle & Co.

ment with appropriate agents during the immediate postoperative period was often the keynote of a successful outcome of surgery.

COMMENT

The present studies indicate the value of the preoperative, operative and postoperative electrocardiogram. The mortality rate of patients anesthetized under electrocardiographic control was zero as compared with 6 per cent in the control group, in whom no electrocardiogram was taken. The lowered mortality was traceable to better therapy which resulted from a knowledge gained through the electrocardiogram which could not be obtained from the pulse rate, blood pressure and appearance of the patient. The general rules which were followed are outlined: In the presence of clinical signs of congestive heart failure, rales in the chest and shortness of breath, digitoxin, 1.2 mg., was given twelve hours before operation. Because a large heart is often a failing one, digitalization was instigated in patients with signs of ventricular strain in the electrocardiogram or radiologic or clinical evidence of cardiac enlargement. Digitalization was usually employed in patients with tuberculosis, particularly those who had been treated with prolonged periods of bed rest, and also in the older age group. Signs of digitalis intoxication occurred in only 4 per cent of 25 patients. Electrocardiographic findings of multiple premature ventricular contractions were readily controlled with pronestyl. It is of considerable interest that the vasovagal reflex occurred less frequently in the digitalized group (16 per cent of 25 subjects) than in the control group (40 per cent). This is contrary to the concept generally held. The difference in results possibly may be explained by differences in response of the anesthetized patient as compared with that of the conscious subject. Digitalis was used with caution in the presence of a heart block of any type, particularly an auriculoventricular block, but if necessary was used in patients with this abnormality if congestive cardiac failure was present.

Coronary insufficiency when evident in the preoperative electrocardiogram or when present clinically as revealed by angina pectoris was treated with administration of aminophylline orally or by suppository.

The vasovagal attack was anticipated by giving banthine, 100 mg., orally before operation in most instances. This dose of banthine resulted in only a moderate increase in cardiac rate and was effective in reducing the severity and frequency of the vasovagal attack. This dosage of the drug produced incomplete blocking of the vagus one to one and a half hours after its administration as shown by the increase in cardiac rate and blood pressure when atropine was subsequently administered. The combination of banthine and digitalis was highly desirable as the vagotonic effect of the digitalis which is un-

desirable in these patients was counteracted by banthine. Other studies have shown that banthine is an efficient agent for treating digitalis intoxication. As little as 5 mg. of this drug given intravenously is sufficient to correct a sino-auricular block or first or second degree heart block resulting from overdigitalization.

The supraventricular arrhythmias including auricular fibrillation or flutter, auricular tachycardia, ectopic beats or nodal tachycardia were treated preoperatively with quinidine, 6 grains. A dose of 3 grains of quinidine was insufficient to protect against cardiac arrhythmias or to produce prolongation of the Q-T intervals. A dose of 6 grains, however, produced definite prolongation of this interval and was effective in inhibiting supraventricular arrhythmias in most cases. Quinidine sulphate was selected for preoperative medication as it was thought that pronestyl could be used intravenously during the surgical procedure with a greater degree of safety. The response of the supraventricular arrhythmias to pronestyl was generally satisfactory. This likewise is contrary to the general concept that pronestyl is relatively unsatisfactory in the treatment of these arrhythmias. This difference is probably owing to certain effects of the anesthetic on the anesthetized patient. This is in keeping with the experience with procaine which is more effective in controlling arrhythmias in the anesthetized patient than in the conscious subject.

The ventricular arrhythmias including ventricular ectopic beats, ventricular tachycardia or fibrillation were treated prophylactically with quinidine as described and pronestyl during operation if necessary.

These studies seem to indicate that the anesthetist is dealing with a highly specialized branch of cardiology which requires special knowledge and skill. This difference seems to revolve about the fact that most of the cardiac reflexes in the anesthetized patient are altered to various degrees, depending on the depth and type of anesthesia which results in responses to therapy that differ considerably from responses ordinarily obtained in the conscious patient. For example, neosynephrine given intravenously in small doses to the unconscious patient has a definite hypertensive effect on the blood pressure without seriously altering cardiac rhythm. In the conscious patient a nodal rhythm is produced in the majority of patients (14). Pronestyl is probably more effective in auricular rhythms in the anesthetized than in the unanesthetized patient. Thus the anesthesiologist is not necessarily guided by conventional treatment which is based on studies of the unanesthetized patient with cardiovascular disease.

SUMMARY

Special problems in altered cardiac physiology encountered in intrathoracic surgery have been presented.

The electrocardiographic studies before, during and after operation

have been presented in the clinical setting showing their value as an aid in discovering otherwise undetectable and many times serious cardiac arrhythmias.

These electrocardiographic studies have provided a means of checking on the efficacy of therapy given either prophylactically or therapeutically for cardiac abnormalities.

Tracings illustrating various arrhythmias encountered, and in some instances the responses to treatment, are presented.

The value of prophylactic preoperative administration of banthine and digitalis in selected cases is emphasized.

It has been emphasized that the rules pertaining to conventional cardiac treatment in the conscious patient do not necessarily apply to the anesthetized patient during chest surgery.

REFERENCES

1. Jones, J. C., and Jones, T. E.: Personal communication to the Authors.
2. Graham, E. A., and Singer, J. J.: Successful Removal of Entire Lung for Carcinoma of Bronchus, *J.A.M.A.* **101**: 1371-1374 (Oct. 28) 1933.
3. Burstein, C. L.; LoPinto, F. J., and Newman, W.: Electrocardiographic Studies During Endotracheal Intubation and Effects During Usual Routine Technics, *Anesthesiology* **11**: 224-237 (March) 1950.
4. Taylor, I. B.: Cyclopropane Anesthesia: With a Report of the Results in 41,690 Administrations, *Anesthesiology* **2**: 641-653 (Nov.) 1941.
5. Levine, S. A.: *Clinical Heart Disease*, ed. 3, Philadelphia, W. B. Saunders Company, 1945, p. 355.
6. Friedberg, C. K.: *Diseases of the Heart*, Philadelphia, W. B. Saunders Company, 1950, p. 285.
7. Mark, L. C.; Berlin, I.; Kayden, H. J.; Roventine, E. A.; Steele, J. M., and Brodie, B. B.: The Action of Procaine Amide (N-(2-diethylamino ethyl) p-aminobenzamide) on Ventricular Arrhythmias, *J. Pharmacol. & Exper. Therap.* **98**: 21 (Jan.) 1950 (Abstract of Paper).
8. Beck, C. S.: Cardiac Arrest During Anesthesia and Surgery, *J.A.M.A.* **141**: 1230-1232 (Dec. 24) 1949.
9. Stroud, W. D.: *Diagnosis and Treatment of Cardiovascular Disease*, vol. 1, ed. 3, Philadelphia, F. A. Davis Company, 1945, p. 890.
10. Gold, H.: *Quinidine in Disorders of the Heart*, New York, Paul B. Hoeber, Inc., 1950.
11. Reid, L. C., and Bruce, D. E.: Irritation of Respiratory Tract and its Reflex Effect Upon Heart, Surg., Gynec., & Obst. **70**: 157-162 (Feb.) 1940.
12. Lewis, Thomas: *Diseases of the Heart*, New York, The Macmillan Company, 1937, p. 98.
13. Longini, F. H.; Grimson, K. S.; Chittum, J. R., and Metcalf, B. H.: Orally Effective Quaternary Amine, Banthine, Capable of Reducing Gastric Motility and Secretions, *Gastroenterology* **14**: 301-313 (Feb.) 1950.
14. Hecht, H.: Cardiac Irregularities Produced by Neosynephrin in Man, American Federation for Clinical Research, Western Section, January 1951.