

Any time during anesthesia or after its discontinuation, the efficiency of the spontaneous respiration can be estimated by the use of the nonbreathing valve. This is done in the following manner: the total gas flow from the machine is so adjusted that the bag keeps a constant average size at the end of expiration. If the total flow of gases from the machine when this is attained is 8 liters per minute, then the respiratory minute volume will be 8 liters. (A decrease in the size of the bag means that the respiratory minute volume is greater than 8 liters, and an increase in the size means that it is smaller.)

The nonbreathing valve here described has now been in general use for about 3 years, for children as well as for adults,

including thoracic anesthesia. Furthermore, it has been used successfully for artificial respiration in patients with respiratory paralysis, and for this purpose frequently has been in continuous use for several days. (The valve, which is made of plastic [perspex®], can be cleaned mechanically by flushing the channels with soap and water. Furthermore, it tolerates most chemicals, including solutions of formaldehyde, ether, and alcohol. As the material deteriorates if exposed to chloroform or heat, these should not be used as aids for cleaning.)

HENNING RUBEN, M.D.,
Department of Anesthesiology,
The Finsen Institute,
Copenhagen, Denmark

AN ELECTRONIC PULSE DETECTOR

For many years, we have felt the need for continuous observation of the pulse rate. Present day methods of anesthesia, with all its complexities and manipulations, often precludes palpation of the

pulse during periods of greatest danger. The performance of intrathoracic, intracardiac, and other major surgical procedures requires that the anesthesiologist perform many functions at the same time.

These include controlled respiration, recording of blood pressure, keeping of adequate records, attention to fluids and blood, use of pressure transfusions, and so forth. These manifold duties often occupy both hands of the anesthesiologist and often carry him or her away from the patient. The acceptance of the new surgical procedures and the willingness to perform major surgical operations on patients who previously were rejected has increased the demands upon the anesthesiologist. This has increased the occurrence of cardiac arrest on the operating table. In the presence of this complication, speed in the institution of proper treatment is the major factor which will reduce the mortality. It is obvious that treatment is not instituted until the diagnosis is made, and, if detected at the earliest possible moment, opportunity for successful restitution of cardiac function is greatly enhanced.

It is for the above reasons that we

sought for a method of continuous pulse observation that would free the anesthesiologist's hand but still keep him informed of moment-to-moment pulse action. The apparatus must be simple, inexpensive, and small. It must be sufficiently accurate to afford a continuous method of pulse observation, it must entail no special skill or knowledge to use or keep in working order. It must be easily put to use and require no special preparation on the part of the patient or the anesthesiologist. We believe the item described below meets the above requirements:

The Palpatron (fig. 1) is an electronic instrument designed to provide a synthetic sense of touch and to convert this stimulus to a visual signal. The sensitive element, or transducer, placed in firm contact with the pulsating artery, is responsive to very slight changes in pressure, as is the doctor's finger.

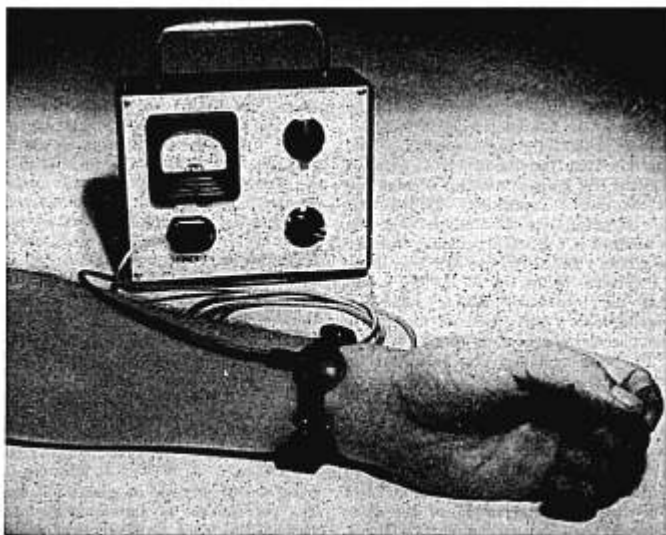


FIG. 1.

The pulsating blood in artery causes an electric signal to be sent from the sensing element to the instrument, where it is amplified a sufficient amount to produce a visible signal in the form of a fluctuation of the meter needle synchronous with the beating of the heart.

The instrument was designed for the sole purpose of indicating the presence or the absence of a pulse beat, and, because of this, avoided the costly complications necessary to a quantitative measurement. However, the instrument will measure relative quantities as a weakening of the pulse will show a corresponding decrease in needle swing.

The instrument is small and light and easily transportable. The instrument operates on a 6 volt battery accessible through a small door in the side of the case for easy replacement. According to Thomas, instruments which operate on a 6 to 8 volt battery do not constitute a hazard in the operating room. The sensitive element is on a 7 foot cord and is plugged into the face of the instrument. A small plastic pouch is provided for carrying the pick-up and the cord and a strap for attaching the pick-up to the patient. A leather case is provided to store the entire unit.

Only two control knobs are necessary to operate the instrument—one a switch for turning it on and off, with a third position marked "test" for checking the state of charge of the battery. When the knob is turned to the "test" position, the meter should read at a higher value than the position marked "test." The second, or lower, control knob is designed solely to regulate the sensitivity of the instrument. The sensitivity increases when this knob is turned in a clockwise direction.

Since acquiring the apparatus, we have used it on our cardiac and pulmonary cases and the pick-up has been applied on the radial artery. In one case of cardiac arrest that occurred, it proved of definite value in the following manner: with each manual compression of the heart, a definite needle deflection was easily visible. This was taken to be evidence that cardiac massage was providing adequate circulation. At this time, the radial pulse

was not palpable. Adequacy of circulation was proved in this patient by the fact that, even though cardiac arrest lasted for thirty-two minutes, the patient exhibited no signs of cerebral damage upon recovery and thirty minutes after reaching the recovery room the patient was completely rational and oriented.

We have also used this apparatus to test the adequacy of a femoral artery graft. In this case, the dorsalis pedis pulsation was not palpable, but the electronic pulse indicator showed definite needle deflection synchronous with the heart rate and later events proved that the arterial graft was patent and functioning properly. In this connection, it has been shown to be much more sensitive than the palpating finger in attempting to evaluate the dorsalis pedis and the posterior tibial artery for peripheral vascular disease.

The above apparatus has been used by us in the operating room and functions as desired. It can be applied on the radial or the brachial artery, the dorsalis pedis or the posterior popliteal, or strapped around the head to fit over the temporal artery. If placed over the radial artery or over the brachial artery below the blood pressure cuff, it will also enable the anesthesiologist to read the blood pressure as there will be no needle deflection above the systolic level. It also can serve a useful purpose in the recovery room for postoperative observation and in the sickroom. In the latter instance, the patient need not be awakened to obtain the pulse rate and cessation of the pulse will be immediately evident.

It is felt that the above instrument is of definite value to any anesthetist in the operating room, in the care of the postoperative patient, and for patients in the sickroom.

The aforementioned apparatus was developed and produced by Gillmors', Inc., of Hicksville, Long Island, New York.

PHILLIP S. MARCUS, M.D., Director,
Department of Anesthesiology,
Boston City Hospital,
Boston, Massachusetts

A RUBBER CATHETER HOOK FOR ETHER INSUFFLATION

A simple light weight rubber catheter hook for ether insufflation is presented. It is particularly useful in an infant who comes to surgery for repair of a harelip. If the catheter is supported as it leads away from the patient's mouth, the anatomy of the operative field will not be distorted.

Catheter (A) shows a No. 18 Foley catheter with the 5 cc. bag cut off (1). For means of demonstration, a wire is shown protruding from the tube for distention of the bag (2). In order to insert this wire with ease, a little liquid soap is squirted inside the tube with a syringe, the catheter bent and cut off to the desired length.

Catheter (B) is of the same type and is ready for use. A No. 10 French nasal catheter has been attached by 2 small rubber bands, which were cut from the large end of the tube for distention of the

Foley bag. A piece of No. 20 silver surgical wire (3) has been doubled, tightly twisted (4) and inserted. An ordinary paper clip may be used but the silver wire is more malleable. The wire need be only long enough to fix the desired curvature and to maintain an adequate lumen.

A No. 12 Foley catheter, the smallest available, can be used. If one does not have access to a Foley catheter, he can use the same wire and attach 1 or 2 No. 8 to No. 12 French nasal catheters to the outside of the curved wire by means of rubber bands or fine surgical wire. Only 1 catheter is required if an ether-oxygen mixture is used. For those insufflating an ether-air mixture, oxygen can be added through the additional smaller catheter.

RUSSELL D. SHELDEN, M.D.,
701 East 63rd St.,
Kansas City 10, Missouri

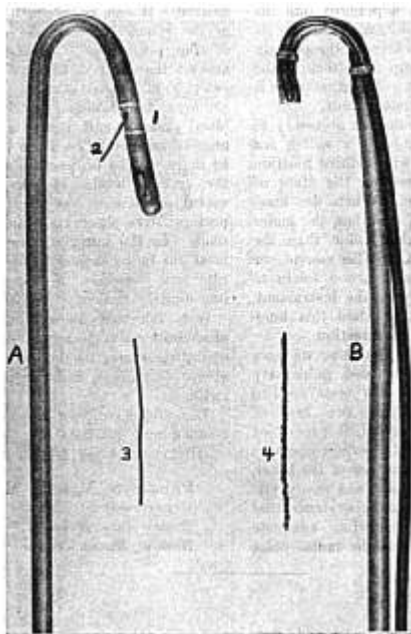


FIG. 1.

CORRESPONDENCE

Letter to the Editor:

Spinal analgesia, employing a hypobaric lucaine* solution, has been recommended recently as the anesthetic method of choice for translumbar aortography (1, 2). The reasons listed for selecting this anesthetic technique were that it was more effective than local infiltration, less hazardous than intravenous anesthesia, and more certain than epidural analgesia.

It is our intention in this letter to cite an objection to the use of spinal analgesia for aortography in the light of the serious complications resulting from this diagnostic procedure in three patients. It is not our intention to discuss the merits of, nor all the dangers associated with, the technique of translumbar aortography.

Case 1. T. E., a 59 year old white male, was admitted to the hospital on February 8, 1954, for the investigation of low back pain and intermittent claudication in both legs.

His history revealed that, in 1951, a spinal fusion extending from the third lumbar to the first sacral vertebrae was performed for spondylolisthesis. Physical examination presented evidence of a marked ischemia of the left leg. To delineate the location and the nature of the pathologic changes, an aortogram was done on February 25, 1954. The patient was induced with pentothal[†]-curare mixture (pentothal 25 mg. and *d*-tubocurarine 0.75 mg. per milliliter of solution) (2) and intubated with a cuffed endotracheal tube. Anesthesia was maintained by additional increments of pentothal-curare mixture and a flow rate of 1,000 ml. each of nitrous oxide and oxygen per minute. After the establishment of anesthesia, the patient was turned to the prone position. A 16 gauge needle was introduced into the abdominal aorta, using the translumbar approach, and 40 ml. of a 70 per cent solution of urokon[†] sodium was injected. Recovery from anesthesia was uneventful and at no time during the entire procedure was there any incident of hypoxia.

Upon regaining consciousness, the patient was found to be anesthetic and areflexic be-

* Lucaine, Maltbie Chemical Co., brand B-(2-piperidyl)-ethyl ortho-amino-benzoate hydrochloride.

† Urokon, Mallinckrodt Chemical Works, St. Louis, Missouri, brand of sodium acetate.

low the levels of the seventh thoracic segment on the right side and the eighth thoracic segment on the left. X-ray studies failed to reveal any evidence of injury to the spinal column. The aortogram showed a marked narrowing below the origin of the renal arteries with good filling of the intercostal and with no filling of the iliac arteries. On February 27, 1954, an analysis of the spinal fluid showed increased protein content and a cell count of 200, consisting mostly of neutrophils. A diagnosis of transverse myelitis was made. The etiology was believed to be on a basis of a thrombosis of the anterior spinal artery. The condition of the patient has remained essentially unchanged during the 6 months intervening between the incident and the time of this writing. It is now apparent that the paraplegic state of the patient is permanent.

Case 2. M. L., a 44 year old white female, was admitted to the hospital February 29, 1952, for an evaluation of liver function. In the course of this investigation, a translumbar aortogram was requested. The anesthetic management of this patient was essentially the same as in the first case, although there was some question of an hypoxic incident during the period of maintenance.

The aortic puncture was accomplished with considerable difficulty after several unsuccessful attempts. Immediately following the injection of dye (70 per cent urokon), the patient had 2 successive, generalized convulsions. The results of the aortogram were inconclusive because of poor visualization of the arteries and extravasation of much of the contrast medium into the tissues surrounding the aorta. Upon recovery from anesthesia, the patient complained of weakness of the left leg. Neurologic examination revealed that the patient exhibited a left hemiparesis (with sensation and coordination intact), a positive toe sign, and urinary bladder retention. At the time, it was thought that the symptoms suggested a diffuse cerebral arteritis secondary to the dye. The weakness improved and the patient was discharged, walking well, on November 6, 1952. On January 6, 1953, she was considered no longer a neurologic problem but has been plagued subsequently with pain in the lumbar region, the buttocks, and the back of the left leg. A neurological consultation on February 5, 1953, concluded: "Neuropathy involving the distribution of the left sciatic nerve, etiology undetermined, possible injury to rootlets during aortogram or possible re-

action to injection of dye into tissues adjacent to nerve with subsequent scarring. Electroencephalogram normal."

Case 3. C. S., a 26 year old white female, came to the hospital on April 2, 1954, for investigation of the kidneys by translumbar aortography. The anesthetic management of the patient was the same as in the foregoing cases. Aortic puncture was performed with much difficulty, and, at one point, spinal fluid appeared at the hub of the needle. After the aortic puncture was accomplished, 70 per cent urokon was injected and the procedure was completed without further event. On awakening from the anesthesia, the patient complained of severe pain in the right lower extremity. Light touch over the medial surface of the right leg exaggerated the pain while stimulation of the lateral surface produced only discomfort. On the following morning, the pain was less severe; stimulation invoked a lesser response; appreciation of light touch was reduced over the entire right lower extremity; reflexes were intact, and there was no weakness. The impression of the neurological consultant was: "extravasation of dye in the abdomen with irritation of the nerve rootlets extending from the first lumbar to the second sacral segments." On April 5, 1954, the patient still complained of some residual pain, but was able to ambulate with the aid of a walker. Several days later she was free of symptoms.

A review of recent literature revealed few reports of serious complications attributable to translumbar aortography. Melnick *et al.* (3) reported more than 3,000 cases without a death that could be ascribed to the injection procedure. Melick (4) stated that all reported deaths prior to 1952 had been the result of the necrotizing effect of sodium iodide on the intestine when the dye inadvertently had been injected into the superior mesenteric artery. With the advent of 70 per cent urokon, necrosis is no longer considered a danger.

Hemiplegia can develop following cerebral angiography by carotid artery injection and several cases have occurred after aortography procedures in which a catheter in the thoracic aorta was employed (5). In the latter instances, the tip of the catheter, presumably, was lying in, or in close proximity to, a carotid artery and concentrated dye gained entry to the cerebral circulation. However, the

possibility of serious neurological sequelae to translumbar aortography has not been stressed. Antoni (6) described one case of paraplegia and paresis of the bladder and the rectum developing in a 68 year old man who had, as did case 1, generalized atherosclerosis. This patient died three months later and necropsy revealed no trace of a traumatic insult, but there was destruction of the entire parenchymatous substance of the spinal cord below the level of the first lumbar segment. This process was ascribed to compression of the aorta by a pillow during the aortography with resultant ischemia of the cord. Boyarsky (7) reported one case of paraplegia following translumbar aortography. This patient made a complete recovery within two months.

We present these case reports, in part, because of the paucity of reported complications in the literature, but herein we are concerned primarily with the recent interest in the use of spinal analgesia for this diagnostic procedure.

Let us suppose that spinal analgesia had been employed in case 1. It would have been difficult for the anesthesiologist to deny a direct responsibility for the tragic result. The potential neurological damage subsequent to dura-arachnoid puncture and intrathecal injection of drugs is well known to both clinician and legal counsel. Paraplegia or any of the diversified features of the cauda equina syndrome often have been attributable to errors in the technique of spinal analgesia. These include the use of a high concentration of the anesthetic solution and the contamination of the injected mixture with cleansing detergents or antiseptics. Complete exoneration of the spinal technique would be virtually impossible to establish. It appears most probable that, despite the observance of meticulous spinal technique, an anesthesiologist could be held responsible for the complications described in case 1.

There are those who will contend that spinal analgesia eliminates the element of vasospasm in the arteries innervated by the cord segments involved in the block. This sympathetic blockade aids in the prevention of thrombosis of the anterior spinal artery. Since the extent to which

vasoospasm is a factor in these cases is uncertain, this protective action of sympathetic paralysis must, at present, be considered only as a possible advantage rather than as an indication for the use of spinal analgesia.

Case 2 is of particular interest because of the development of central nervous system damage following the injection of dye into the abdominal aorta. Heretofore, this complication was considered to be a danger only following the injection of the carotid arteries or the thoracic aorta. The role played by hypoxia in the development of the convulsions is uncertain and well could be considered a contributing factor. Nevertheless, the onset of the seizures immediately followed the injection of the dye and one may assume that a direct relationship existed between these two events. The persistence of back pain with sciatica presents a different problem. This syndrome probably is a result of the extravasation of dye around the nerve roots. Had spinal analgesia been employed in this case, it would be difficult to exclude it as a causative factor.

The excruciating pain in case 3, although of short duration, was very distressing. Though the exact mechanism by which it was produced remains unsettled, it is certain that some part of the aortography technique was responsible. As in the other cases described above, such an assertion could not be made if spinal analgesia had been employed.

In the light of these considerations, spinal analgesia for translumbar aortography is not the procedure of choice. The

degree of responsibility for neurological sequelae is similar to that which accompanies its use in cases of pernicious anemia and spinal cord pathology. Because of the medicolegal considerations, the procedure of translumbar aortography should be considered a contraindication to the use of spinal analgesia.

REFERENCES

1. Feldman, E., Greene, B. A., and Chinn, H. Y. H.: Spinal Analgesia for Translumbar Aortography, *Anesthesiology* 15: 66 (Jan.) 1954.
2. Flint, L. D.: Technique for Translumbar Aortography, *Lahey Clin. Bull.* 8: 244 (July) 1954.
3. Melick, W. F., and Vitt, A. E.: Present Status of Aortography, *J. Urol.* 60: 321 (Aug.) 1948.
4. Melick, W. F.; Byrne, J. E., and Boler, T. D.: Experimental and Clinical Investigation of Various Media Used in Translumbar Aortography, *J. Urol.* 67: 1019 (June) 1952.
5. Peirce, E. C.: Temporary Hemiplegia from Cerebral Injection of Diodrast During Catheter Aortography, *Circulation* 7: 385 (March) 1953.
6. Antoni, N., and Lindgren, E.: Steno's Experiment in Man as Complication in Lumbar Aortography, *Acta chir. Scandinav.* 98: 230, 1949.
7. Boyarsky, S.: Personal Communication to the Authors. Case Report to be Published in *J.A.M.A.*

DONALD S. P. WEATHERHEAD, M.D.,
FREDERICK H. VAN BERGEN, M.D.,
Department of Anesthesiology,
University of Minnesota,
Minneapolis 14, Minnesota

To the Editor:

In the March, 1955 issue of *ANESTHESIOLOGY*, Dr. J. F. B. Zweighaft described a mobile seat and table arrangement on pages 288-289. A few of his statements require comment.

Dr. Zweighaft used iron casters because of "the feeling of security (from static sparks)." Yet the equipment was constructed of wood, a non-conductor, and the tile floor described and pictured is also non-conductive. Inserting a piece of metal

between two non-conductors will not increase the safety one iota. In fact, ferrous metals may strike mechanical sparks from tile floors and for this reason are not advised for use on ceramic or masonry floors. Conductive rubber tired casters should be used and the equipment should be constructed of metal in order to avoid static accumulation. In addition, drag chains are notoriously unreliable after a few months because oxides coat the links preventing conduction. Here too, a drag