

## A TRANSIENT ATTACK OF VENTRICULAR FIBRILLATION DURING RIGHT HEART CATHETERIZATION

TORSTEN GORDH, M.D., HÅKAN LINDERHOLM, M.D.

GUNNAR STRÖM, M.D.

CARDIAC standstill and ventricular fibrillation are known to be rare complications to cardiac catheterization (1) and to surgical procedures, including anesthesia. These conditions are usually regarded as irreversible (2) and lead to immediate death unless special intervention is made in the form of cardiac massage or cardiac electrical stimulation (3). In the literature, however, several instances of transient ventricular fibrillation have been described, some occurring in patients with total atrioventricular block (4-7). In the present case, ventricular fibrillation occurred in a man without signs of heart disease during right heart catheterization under anesthesia. There was a reversal to normal rhythm in a few minutes with conservative treatment.

### CASE REPORT

A 39 year old man was admitted to the surgical clinic at Karolinska sjukhuset for operation on an acromioclavicular luxation caused by an accident. Anamnestically there were no signs of heart disease and the patient was in a good general condition. Physical examination of heart and electrocardiographic studies at rest and during the hypoxia test showed nothing abnormal. The arterial blood pressure at rest was 105 mm. of mercury systolic and 70 mm. diastolic.

The patient consented to measurement of his cardiac output and blood pressure in the pulmonary artery during intermittent positive-pressure breathing under general anesthesia (8). He was given preanesthetic medication of 1.5 cg. of morphine and 0.6 mg. of scopolamine. A No. 9 heart catheter was introduced into a cubital vein in the left arm, and without difficulty the tip was placed in the pulmonary artery. Narkotal<sup>®</sup>-pethidine-Celocurin anesthesia was induced, intratracheal intubation was performed and intermittent positive-pressure breathing with air was started. In eighty-five minutes the patient received, in small repeated doses, 14 milliliters 5 per cent Narkotal \* (isopropyl-bromallyl-N-methyl-malonylecarbamide sodium), 0.2 Gm. of pethidine (ICI) (ethyl-1-methyl-4-phenylpiperidine-4-carboxyl-8-hydrochloride) and 8 milliliters of 1 per cent Celocurin (Vitrum)-(succinylcholine-iodide) plus an intravenous drip from a solution containing 1 Gm. Celocurin in 500 milliliters of 5 per cent glucose. The patient was thereby kept in a relatively superficial stage of anesthesia (Stage III:1, see reference 9) and was sufficiently curarized for spontaneous breathing to be abolished.

The authors are in the Departments of Anesthesiology and Clinical Physiology of the Karolinska sjukhuset in Stockholm. The article was accepted for publication March 21, 1955.

\* Astra Pharmaceutical Products, Inc., Södertälje, Sweden.

For the first thirty minutes the patient was kept in the horizontal position, then nineteen minutes in a tilted (10 degree) head-low position, then for five minutes in a tilted (6 degree) head-high position, and finally was returned to the horizontal position. During these procedures the ventilation was relatively high (9 to 10 liters per minute), with a respiratory frequency of 14 per minute, oxygen uptake 190-200 milliliters per minute, pulse frequency, 60 to 70, cardiac output 4 to 5 liters per minute, arterial blood pressure 84 to 101 mm. of mercury systolic and 53 to 62 mm. diastolic, and arterial oxygen saturation 95 to 97 per cent. Ten minutes after the return to horizontal position, the catheter was slowly withdrawn from the pulmonary artery under continuous registration of the electrocardiogram, arterial blood pressure and tracheal pressure (fig. 1), and with supervision of the catheter pressure curve.

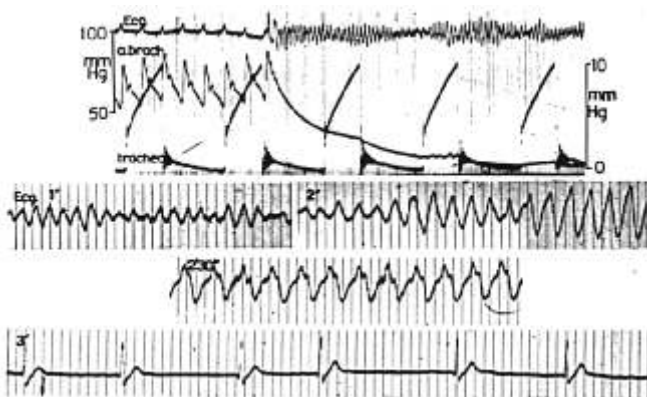


FIG. 1. Electrocardiogram, arterial blood pressure, and tracheal pressure during an attack of ventricular fibrillation. The time after the start of the attack is indicated on the electrocardiogram. The electrocardiogram was a bipolar thoracic lead, nearly identical in appearance with lead  $CR_4$ . Figure marking: 0.1 second in curve at onset of attack, 0.1 and 0.02 second in later curves.

At the moment when the catheter tip was judged to pass from the pulmonary artery into the right ventricle (due to movement artefacts the catheter pressure curve was difficult to assess with certainty) an attack of ventricular fibrillation started (fig. 1), producing an immediate fall in the arterial blood pressure to 15 to 20 mm. of mercury. When the condition was recognized in the electrocardiogram, within a few seconds, the catheter was withdrawn from the right heart. After some twenty to thirty seconds the clinical picture of circulatory standstill became apparent, with blanching of the skin, widening pupils, and in spite of the Celocurin administration, a few respiratory gasps. Within a minute's time pure oxygen was substituted for air in the positive-pressure ventilation, now performed manually. No other treatment was undertaken. The ventricular fibrillation continued unchanged for about two minutes, then a

slower rhythm with less distorted ventricular complexes began to appear, and after two and a half minutes regular ventricular tachycardia supervened (fig. 1). After three minutes an irregular supraventricular rhythm started, and the blood pressure rose to about 150 mm. of mercury systolic for a few minutes, and then returned to the level of the period before the attack of ventricular fibrillation. After another few minutes the electrocardiogram became quite normal and the patient was taken to a deeper level of anesthesia than before the attack. After some time of supervision the originally planned operation was performed without any complications, the arterial blood pressure remaining at about 90–100 mm. of mercury systolic. No sequelae from the attack could be found in examinations after the operation, and several electrocardiograms during the following days were normal. The patient was kept under observation for fifteen days in the hospital.

#### DISCUSSION

It seems probable that the attack of ventricular fibrillation was started by mechanical trauma, occurring when the catheter tip was withdrawn from the pulmonary artery through the right ventricle. This is a rare complication to heart catheterization (1), although the withdrawal of the catheter through the right ventricle is usually regarded as a moment of increased risk, as indicated by the frequent occurrence of ventricular extrasystoles. This opinion is further substantiated by the present case and the one described by Biörck and Krook (10), even if the risk seems to be less than during the introduction of the catheter through the right ventricle. The latter procedure has caused complications in several reported cases (1, 11, 12).

In our case some contributing cause was probably present, producing increased cardiac excitability. There were no signs of heart disease in the examinations before and after the attack. Therefore a pathological change in the heart as a cause of the attack is not probable. One factor may have been the relatively superficial stage of anesthesia, and another, possibly, the relatively low arterial blood pressure. Arterial anoxemia was, however, not present (3).

During the attack, the electrocardiogram showed at first ventricular action potentials of variable amplitude and appearance, with a repetition rate of approximately 400 per second. The electrocardiographic picture and the decrease of arterial blood pressure to a very low value with absence of pulse waves, were the reasons to classify the attack as ventricular fibrillation (2, 13).

The reason why the attack subsided is obscure. It may have done so spontaneously; or the increased ventilation with pure oxygen may have played a part. Unfortunately, the prognosis of a ventricular fibrillation can hardly be judged from the electrocardiogram. Usually, different stages of development of ventricular fibrillation can be observed: an undulatory stage, convulsive incoördination, tremulous incoördination, ending in atonic fibrillation (2). In the present case, such a development did not occur; the electrocardiographic picture

during the first two minutes of the attack should probably best be compared with the stage of convulsive incoördination. If an attack of fibrillation suddenly changes to regular ventricular tachycardia, as in the present case, there is probably more hope than otherwise that the attack will subside. Such a change is best discovered in the electrocardiogram and, for that reason, there seems to be some value in observing the electrocardiogram during an attack of fibrillation, on the condition that registration does not interfere with the ordinary procedures for cardiac resuscitation (3, 14).

#### SUMMARY

Ventricular fibrillation appeared in an apparently healthy man during right heart catheterization, performed preoperatively under barbiturate-curare anesthesia and intermittent positive-pressure breathing. The attack was treated with pure oxygen artificial breathing and subsided after about two minutes. No sequelae were apparent.

#### REFERENCES

1. Cournaud, A., Bing, R. J., Dexter, L., Dotter, C., Katz, L. N., Warren, J. V., and Wood, E.: Report of Committee on Cardiac Catheterization and Angiocardiography of American Heart Association, *Circulation* 7: 769 (May) 1953.
2. Wiggers, C. J.: Mechanism and Nature of Ventricular Fibrillation, *Am. Heart J.* 20: 399 (Oct.) 1940.
3. Hosler, R. M.: *A Manual on Cardiac Resuscitation*. Springfield, Ill., Charles C Thomas, 1954.
4. Parkinson, J., Papp, C., and Evans, W.: Electrocardiogram of Stokes-Adams Attack, *Brit. Heart J.* 3: 171 (July) 1941.
5. Schwartz, S. P.: Transient Ventricular Fibrillation; Study of Fibrillary Process and Its Development in Man, *J. Mt. Sinai Hosp.* 8: 1005 (Jan.-Feb.) 1942.
6. Gresham, G. A.: Case of Ventricular Fibrillation, *Brit. Heart J.* 14: 527 (Oct.) 1952.
7. Robertson, E. S., and Mathews, E. C.: Paroxysmal Ventricular Fibrillation Producing Adams-Stokes Syndrome; Report of Case with Review of Literature, *A.M.A. Arch. Int. Med.* 80: 320 (Sept.) 1952.
8. Bernfus, B., Gordh, T., Linderholm, H., Ström, G., and Werneman, H.: On Effect of Head-Low Position during Intermittent Positive-Pressure Ventilation, *Acta med. Scandinav.* 152: 31 (Aug.) 1955.
9. Gordh, T.: Postural Circulatory and Respiratory Changes during Ether and Intravenous Anesthesia; Experimental Analysis of Significance of Postural Changes during Anesthesia with Special Regard to Value of Head-down Posture in Resuscitation, *Acta chir. Scandinav.* (suppl. 102) 82: 1, 1945.
10. Blörek, G., and Krook, H.: Myocardial Injury at Cardiac Catheterization; Report of Case, *Acta Cardiol.* 6: 101, 1951.
11. McMichael, J., and Mounsey, J. P. D.: Complication Following Coronary Sinus and Cardiac Vein Catheterization in Man, *Brit. Heart J.* 13: 397 (July) 1951.
12. Goodwin, J. F.: Fatality Following Cardiac Catheterization Injury, *Brit. Heart J.* 15: 330 (July) 1953.
13. Schaefer, Hans: *Das Elektrokardiogramm: Theorie und Klinik*. Berlin, Springer-Verlag, 1951, p. 418.
14. Wiggers, C. J.: Physiological Basis for Cardiac Resuscitation from Ventricular Fibrillation—Method for Serial Defibrillation, *Am. Heart J.* 20: 413 (Oct.) 1940.