

## THE ETIOLOGY AND TREATMENT OF LARYNGEAL SPASM

BERNARD RAYMOND FINK, M.D.

LARYNGEAL obstruction arising during anesthesia has commonly been regarded as due to partial or complete spasm of the intrinsic muscles of the larynx (1). This view is derived from the prevailing theory (2) that the larynx is a sphincteric mechanism comprising three levels or layers: the vocal cords, the false cords and the aryepiglottic folds. The successive contraction of these layers is held to produce three degrees of laryngeal spasm, according to whether the vocal cords alone, or both the vocal and false cords, or all three layers are involved.

Recent studies (3, 4) have brought forward evidence that closure of the human larynx is not that of a simple sphincter but involves a dual mechanism consisting of a shutter and a ball valve. The shutter

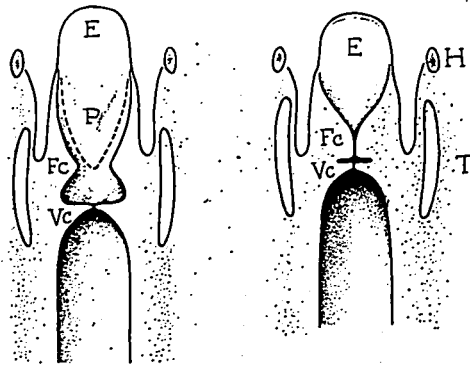


Fig. 1. Sectional view of larynx from behind (drawn from laminagrams). (E) epiglottis, (FC) false cords, (H) hyoid bone, (P) paraglottis, (T) thyroid cartilage, (VC) vocal cords. Left: phonation. Right: Valsalva maneuver. During vocalization the vocal cords (VC) are adducted and form a shutter tending to obstruct expiration, the false cords (FC) and paraglottis (P) remain separated. During laryngeal closure the false cords make contact with the paraglottis and also with the vocal cords. Both the vestibule and the ventricles are thereby obliterated. Note the decreased distance between the cornua of the hyoid and thyroid during closure.

This article was received from the Department of Anesthesiology, Columbia University, College of Physicians and Surgeons and the Anesthesiology Service, The Presbyterian Hospital, New York 32, New York, and was accepted for publication April 6, 1956. The paper was read before the annual meeting of the American Society of Anesthesiologists, Inc., Boston, Massachusetts, October 31, 1955. This investigation was supported in part by the Squibb Institute for Medical Research and the Wrightsman Fund for Research in Anesthesiology.

is formed by the vocal cords and is normally closed by action of the adductor muscles of the cords. The ball valve is constituted by the false cords and preepiglottic body (figs. 1 and 2) and is probably controlled by extrinsic laryngeal muscles. It was shown, by means of roentgenograms, that when the thyroid cartilage and hyoid bone are drawn toward each other, as occurs during swallowing, coughing or straining, the vestibular and vocal folds come together in the midline. At the

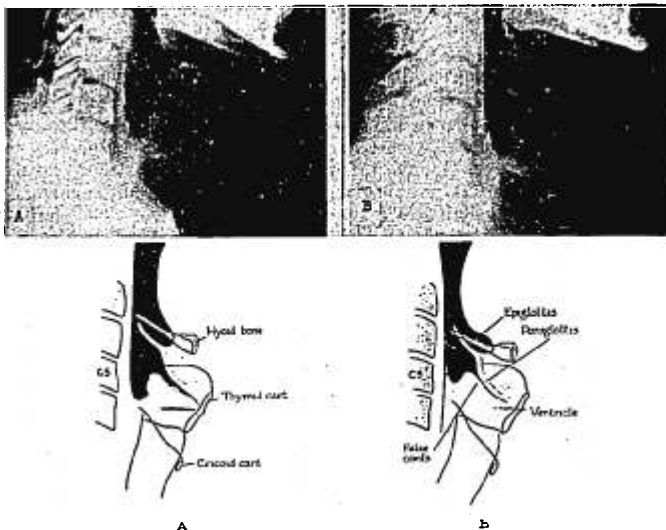


FIG. 2. Lateral roentgenograms of a normal larynx and diagrammatic guides. A. Open at end of quiet expiration. B. Closed during Valsalva maneuver. When the larynx closes the thyro-hyoid distance is decreased, the paraglottis (intralaryngeal portion of the epiglottic cartilage) becomes rounded and makes contact with the upper surface of the false cords. The false cords touch the vocal cords and obliterate the ventricle. Upward movement of the larynx relative to the hyoid bone appears to make the laryngeal soft tissues fold up and press against the under surface of the preepiglottic body.

same time the preepiglottic body, extending from the hyoid to the notch of the thyroid cartilage, becomes rounded and presses against the upper surface of the false cords in the manner of a ball valve (figs. 2 and 3). As a result the vestibule and ventricles are obliterated and the entire larynx is firmly closed. This movement is accompanied by a burst of electrical activity in the thyrohyoid, sternohyoid and sternothyroid muscles (fig. 4). The conclusion was drawn that the combined action of these muscles controls the position of the cricoid and thyroid

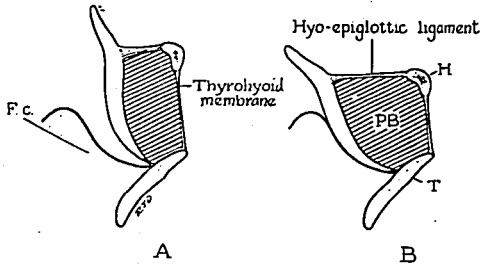


FIG. 3. Sagittal section to illustrate the action of the laryngeal ball valve, A. open, B. closed. During laryngeal closure the preepiglottic body (PB) is squeezed between the hyoid bone (H) and thyroid cartilage (T). The paraglottis (P) buckles and is forced against the upper surface of the false cords (F.C.).

cartilages in relation to the hyoid bone, and thereby regulates the degree of separation of the soft tissues in between.

The shutter and ball valve concept helps to clarify several previously rather ill defined situations arising during general anesthesia.

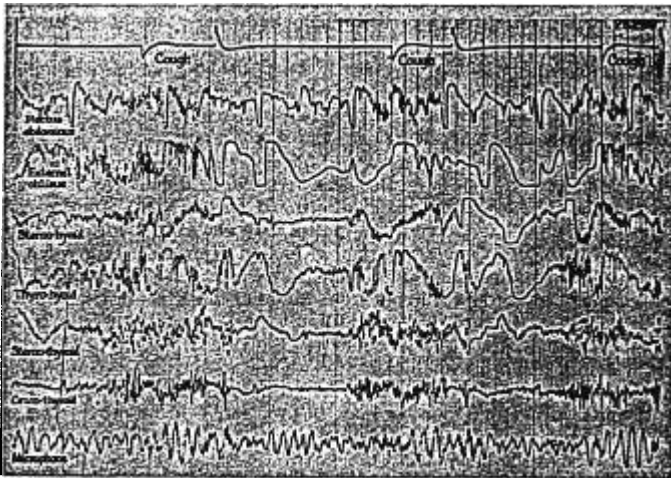


FIG. 4. Electromyograms of laryngeal and abdominal muscles during coughing. Concentric needle electrode leads. Duration 5 seconds. Top tracing: signal of onset and end of cough, made by subject. Closure of the larynx at the onset of a cough is accompanied by sudden increase of electrical activity in the extrinsic laryngeal muscles. When the larynx reopens noise is registered by the microphone (bottom tracing) and there is an abrupt decrease in extrinsic muscle activity.

## OBSTRUCTION DUE TO CLOSURE OF THE GLOTTIC SHUTTER

Approximation of the vocal cords can occur independently of closure of the ball valve (fig. 1) and may take place either on expiration or inspiration. In either case obstruction of the airway is incomplete because air pressure on the vocal cords throws them into vibration. The resulting stridor has a definite pitch, a feature pathognomonic of partial obstruction at the glottis. The source of origin of the sound is readily confirmed by inspection with a laryngoscope.

*Expiratory Stridor.*—When glottic stridor occurs during expiration the mechanism is essentially similar to that of singing. The adducted vocal cords offer a certain resistance to the escape of air, ranging in the spoken voice from 25 to 60 mm. of mercury (5). Measurements of this pressure under conditions of anesthesia are not available but it is evident that an appreciable obstruction is present during expiratory glottic stridor and demands an increased expiratory effort on the part of the patient.

Expiratory stridor usually arises in response to somatic sensory stimulation during surgery and is in effect a vocal protest against too little anesthesia. The vigorous respiration that accompanies it is further evidence of light anesthesia. The stridor can be stopped by discontinuing the stimulus or by inducing a deeper plane of anesthesia.

*Inspiratory Stridor.*—The glottic shutter may also close during inspiration, although not necessarily as a result of active adduction. It is to be noted that the glottis forms a constriction analogous to that of a venturi tube. Bernoulli's theorem states that when fluid flows steadily through a narrowing passage, the pressure varies inversely with the velocity of flow. Since the velocity is greatest where the passage is narrowest, it follows that gas pressure in the airway is lowest at the glottis, and during inspiration must be less than atmospheric. Thus passage of air through the glottis may generate a force tending to draw the vocal cords together. During expiration this force is opposed by the increased "positive" airway pressure produced by expulsion of gas from the lungs. On the other hand inspiration creates a "negative" pressure that is additive to the Bernoulli effect. In an unanesthetized person the tendency to inspiratory closure of the glottis is counteracted by abduction of the vocal cords. However, during general anesthesia there is a progressive loss of skeletal muscle tone, although respiratory muscles may remain active after other muscles have become relaxed, particularly during ether anesthesia. In these circumstances the laryngeal muscles are weakened while ventilation is still effective. Vocal cord abduction is reduced while gas flow through the glottis continues unabated. Consequently the Bernoulli effect is more pronounced, the cords come together with each inspiration and a musical stridor develops, characteristically limited to the inspiratory phase of respiration.

Increased inspiratory efforts do not overcome this form of obstruction but rather aggravate it, probably because the concave upper surface of the vocal folds promotes firmer apposition of the cords when the pressure in the trachea is lowered (fig. 5). This is reminiscent of the glottis of lower primates where the vocal folds are frankly cusp-like (fig. 6) in adaptation to the need for closing the larynx and fixing the chest wall when the arms are engaged in climbing (2). In such animals the adducted vocal cords form a bicuspid valve barring the ingress of air and indirectly reducing movement of the rib cage. Clinically the Bernoulli effect is likely to be most marked when the cords are close together at the start of inspiration and experience confirms that inspiratory stridor occurs characteristically in children and small adults,

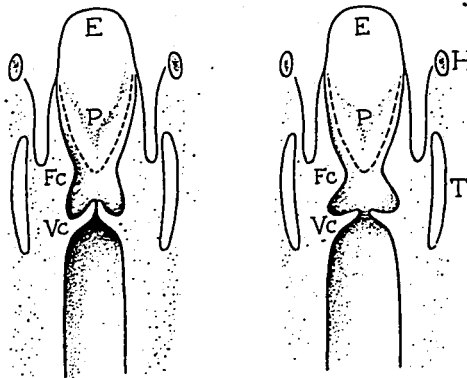


FIG. 5. Human larynx during inspiration (diagrammatic). Right: normal subject. Left: deep anesthesia or bilateral recurrent laryngeal paralysis. When abductor tone is lost the Bernoulli effect approximates the vocal cords during inspiration. Stronger inspiration merely aggravates the obstruction. Note the concave upper surface of the vocal cords.

whose glottis is relatively small. Complete obstruction of cusp valve type requires vigorous inspiration and is accordingly most frequently encountered during the middle planes of ether anesthesia, when glottic abductor tone is reduced but respiration is strong and even augmented.

Inspiratory stridor can be overcome by any maneuver which keeps the cords separated during inspiration. For example, positive pressure applied before the onset of inspiration prevents the development of negative pressure and neutralizes the Bernoulli effect. Alternatively, inspiratory stridor can be abolished by lightening the plane of anesthesia until sufficient abductor tone has been restored. This method is particularly useful in open drop techniques. Completely controlled respiration also abolishes the stridor but is usually unnecessary.

The combination of reduced abductor tone and strong respiratory activity can also occur in the unanesthetized patient, and leads to the same sequence of inspiratory stridor and complete obstruction as during general anesthesia. This happens in cases of bilateral recurrent laryngeal nerve injury, where the abductor mechanism is paralyzed and not available to oppose the glottic Bernoulli effect. In such cases the obstruction is partly aerodynamic in origin and is actually aggravated by the flow of gas; increased inspiratory efforts are therefore self-defeating. Permanent tracheostomy or a reconstruction of the glottis is necessary to relieve the condition.

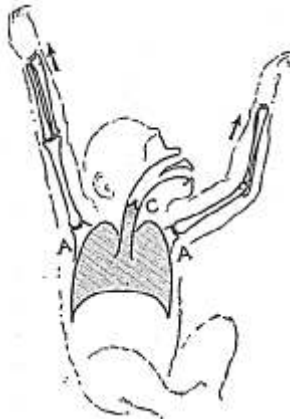


FIG. 6. Diagram to illustrate the cusp valve function of the concave vocal cords in lower primates. When the thorax is suspended from the arms (AA) the vocal cusps (C) prevent expansion of the chest, stabilizing the thoracic origin of the climbing muscles.

#### OBSTRUCTION DUE TO CLOSURE OF THE LARYNX

The preceding types of airway obstruction arise in the glottic shutter and are due to malfunction of the intrinsic muscles of the larynx. Contrasted with this group is the obstruction caused by activity of the laryngeal ball valve, where the main culprits are extrinsic muscles. Ball valve closure of the larynx can be readily observed during general anesthesia if a Macintosh laryngoscope is introduced and the laryngeal mucosa stimulated by a blunt probe. Adduction of the vocal cords occurs, swiftly followed by that of the false cords. The larynx becomes foreshortened and the false cords disappear from view by making contact with the bulging paraglottis (intra-laryngeal portion of the epiglottic cartilage). Finally the mucosa

of the aditus is inverted (3), resulting in the puckered appearance typical of so-called complete laryngeal spasm. Photofluorography and motion pictures have demonstrated that a similar sequence occurs during swallowing, coughing and straining (3).

Ball valve closure of the larynx may constitute a serious emergency. Such a spasm cannot be broken by bag pressure through a mask. Forced inflation of the pharynx merely distends the piriform fossas on either side of the larynx and presses the aryepiglottic folds more firmly against each other (fig. 7). A more effective maneuver is to force the chin forward by strong pressure behind the angles of the jaw. The forward movement is transmitted through the geniohyoid muscles to the hyoid bone, hyoepiglottic ligament and paraglottis. The latter

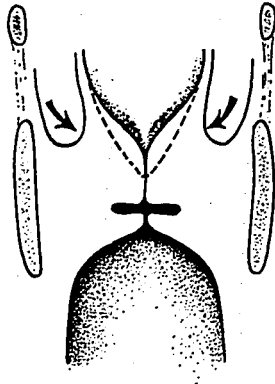


Fig. 7. Effect of bag pressure on the closed larynx. Attempted inflation of the lungs distends the piriform fossas (indicated by the arrows) and reinforces the closure.

is pulled away from the false cords and the laryngeal passage is reopened. This maneuver succeeds in infants and children, but often adult jaw muscles prove stronger than the anesthesiologist's hands and necessitate resort to other methods of breaking the reflex.

Ball valve closure of the larynx appears to be a reflex response to stimulation of visceral nerve endings in the pelvis, abdomen, thorax or larynx itself. The simplest way to abolish the reflex is to stop the stimulus. This can be done prophylactically by topical or local anesthesia, or in emergency by asking the surgeon to interrupt his manipulations. Any irritant such as mucus, blood or an excessively long artificial airway must be removed from the larynx. Deepening the plane of anesthesia will prevent recurrence of the spasm. This is easily achieved with intravenous agents but is rather more difficult with inhalation

methods because the agent itself may irritate the larynx and stimulate a reflex closure. Muscle relaxants paralyze the reflex effectively. If a relaxant is used, equipment to maintain ventilation and remove re-gurgitated material must be instantly available.

#### NOTE ON NOMENCLATURE

It would appear from the foregoing account that several distinct mechanisms have in the past been included under the term "laryngeal spasm" or "laryngospasm." For the sake of clarity the term "laryngeal spasm," with its connotation of danger, is perhaps best reserved for prolonged closure of the larynx which, as already shown, involves the ball valve mechanism. Forms of laryngeal obstruction arising at the glottis are intermittent, involve only the glottic shutter, and are preferably referred to as stridor.

#### THE RELATION OF COUGHING TO LARYNGEAL SPASM

It is noteworthy that the onset of severe laryngeal spasm is frequently preceded by a bout of coughing. The cough is paroxysmal and involves intermittent expiratory efforts accompanied by a series of ball valve closures of the larynx. When laryngeal spasm sets in the expiratory effort becomes prolonged and closure of the larynx and contraction of the abdominal wall become continuous. It would therefore appear that laryngeal spasm is part of a general expiratory effort or spasm and may be simply an extreme form of cough.

When an endotracheal tube is in the larynx closure of the ball valve is prevented and coughing is manifested as "bucking." Bucking is usually intermittent but, like coughing, may also develop into a continuous expiratory spasm. Here the laryngeal component of the spasm is neutralized by the endotracheal tube, making the concomitant abdominal and thoracic wall rigidity easily detected; the rigidity is often so marked that inflation of the lungs becomes virtually impossible. Wheezing may be heard, indicating that the bronchial passages are narrowed. A causal relation between this wheezing and spasm of the abdominal and chest walls is apparent from the fact that both are abolished by the administration of a relaxant.

#### SUMMARY

Reflex closure of the glottis, passive closure of the glottis and reflex closure of the larynx are three distinct mechanisms, each liable to obstruct respiration during general anesthesia.

Reflex closure of the glottis is due to a shutter-like adduction of the vocal cords, occurs during light anesthesia, and is a response to somatic sensory stimulation. It gives rise to a musical stridor repeated with each expiration and may be regarded as an example of unconscious phonation.



Passive closure of the glottis, occurring in relatively deep anaesthesia, may be initiated by the inspiratory flow of gas when the glottic Bernoulli effect is unopposed by abduction of the vocal cords. Further inspiratory effort may suck the vocal cords together so strongly that complete obstruction results. This probably represents a reversion to the cusp valve functioning of the vocal folds present in lower primates.

Reflex closure of the larynx is due to a ball valve mechanism consisting of the preepiglottic body and false cords, operated mainly by extrinsic muscles, notably the thyrohyoid. It may be regarded as a protective reflex response to visceral sensory stimulation, and is part of a general expiratory spasm which itself represents an extreme form of cough.

The mechanism of each type of obstruction is discussed and appropriate remedies are suggested.

REFERENCES

1. Burstein, C. L.: *Fundamental Considerations in Anesthesia*. New York, The Macmillan Company, 1949, p. 29.
2. Negus, V. E.: *The Mechanism of the Larynx*. St. Louis, C. V. Mosby Company, 1931.
3. Fink, B. R.: *Mechanism of Closure of Human Larynx*, *Tr. Am. Acad. Ophth.* 60: 117 (Jan.-Feb.) 1956.
4. Fink, B. R., Busek, M., and Epanchin, V.: *Mechanism of Opening of Human Larynx*, *Laryngoscope*, In press.
5. Curry, R.: *The Mechanism of the Human Voice*. New York, Longmans, Green & Co., 1940, p. 77.

(Continued from page 548)

<i>Course No.</i>	<i>Title</i>	<i>Instructor</i>
M13-T51	"Etiology, Pathogenesis and Treatment of Shock".....	Donald E. Hale, M.D.
M58	"Practical Concepts in Pain Management".....	Frederick P. Haugen, M.D.
M17-T17	"Physics as Applied to Anesthesia".....	Mr. Wayne W. Hay
M45-T45	"Caudal-Transacral Anesthesia".....	Robert A. Hingson, M.D.
M37-T37	"Anesthesia in Caesarean Section".....	J. Jay Jacoby, M.D.
M48-T36	"Anesthesia for Thoracic Surgery".....	John E. Keet, Capt., MC
M11-T111	"Anesthetic Management for Intracardiac Surgery, Complications and Treatment".....	Kenneth Keown, M.D.
M39-T39	"An Abstract of the History of Surgical Anesthesia".....	Thomas E. Keys
M33-T33	"Medico-Legal Aspects".....	Mr. John Lansdale, Jr.
M18-T18	"Spinal Anesthesia".....	Lloyd E. Larrick, M.D.
M46-T46	"Anesthesia for Patients with Cardiac Lesions".....	Philip A. Lief, M.D.
M412-T412	"Induced Hypotension during Anesthesia".....	David M. Little, Jr., M.D.
M34-T34	"Geriatric Anesthesia".....	Paul H. Lorhan, M.D.
M28	"A Comparison of Intravenous Anesthesia".....	John S. Lundy, M.D.
T28	"Roentgenograms in Diagnostic and Therapeutic Nerve Blocks".....	John S. Lundy, M.D.
M510-T47	"Pharmacology of Barbiturates".....	Lester C. Mark, M.D.
M24	"Causes and Treatment of Sudden Cardiac Collapse".....	Stevens J. Martin, Ph.D., M.D.
M47-T24	"Pharmacology of Local Anesthetic Agents".....	Hugh S. Matthewson, M.D.
M25	"Cervical Plexus Block".....	Daniel C. Moore, M.D.

(Continued on page 590)