

# BRADYCARDIA FOLLOWING INTRAVENOUS ADMINISTRATION OF SUCCINYLBCHOLINE CHLORIDE TO INFANTS AND CHILDREN

M. DIGBY LEIGH, M.D., DOUGLAS D. MCCOY, M.D., M. KATHLEEN BELTON, M.D.  
GEORGE B. LEWIS, JR., M.D.

FOLLOWING the intravenous administration of succinylcholine chloride from ampuls of 2 per cent solution, bradycardia has been heard through the precordial stethoscope innumerable times in infants and young children. Occasionally it has been of such magnitude that transient circulatory depression ensued. At times cyanosis has been observed during the bradycardia, even with simultaneous ventilation of the lungs with high concentration of oxygen.

Investigation and recording of this phenomenon was carried out by lead II electrocardiographic tracings on a series of 23 patients in the age group of one day to seven years. The 4 cases described are representative of the series.

## EFFECT OF ANESTHETIC AGENT

Succinylcholine chloride was administered intravenously during thiopental, cyclopropane, ether, and Lorfan-Nisentil-nitrous oxide anesthesia, with continuous ventilation of the lungs with oxygen. Three of these cases were monitored prior to intubation and surgery. The fourth case monitored was an intubated and artificially ventilated patient who was given intermittent succinylcholine chloride for muscle relaxation.

*Case 1.*—A 3-year-old white boy of 24 pounds received secobarbital, 30 mg. rectally, and scopolamine, 0.133 mg. intramuscularly, two hours before induction with thiopental.

Figure 1 (a) and (b) show sinus tachycardia. Tracing (c) shows some slowing with sinus rhythm in the first two cycles. In the third cycle, the P wave is delayed (sinus delay), finally breaking through with a PR interval of 0.08 or less. (The preceding sinus beats have a PR interval of 0.12.) The QRS associated with the short PR is probably nodal, and represents a nodal escape. The next two beats are slow sinus, and the last repeats the sinus delay, late P wave, short PR and nodal escape. However, in this last cycle, the P wave changes contour, suggesting ectopic atrial innervation, possibly in relation to the escape.

In tracing (d) the first QRS is probably nodal (no preceding P). The second is probably also nodal (or aberrant A-V conduction) with short PR. The remainder are sinus beats. (PR about 0.11.)

Received from the Los Angeles Childrens Hospital and the University of Southern California School of Medicine, Los Angeles, California, and accepted for publication May 7, 1957.

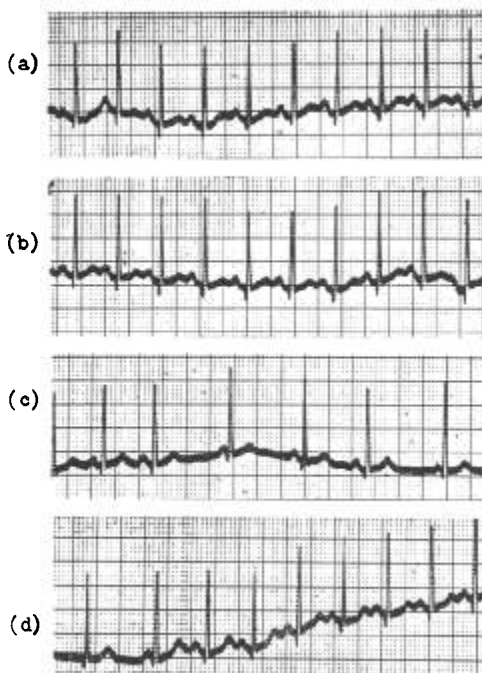


FIG. 1. Case 1. (a) Preinduction tracing—heart rate 160 beats per minute. (b) Thiopental 40 mg. intravenously—heart rate 160. (c) Thirty seconds after succinylcholine 7 mg. intravenously—heart rate 100. (d) One minute after atropine 0.06 mg. intravenously—heart rate 160.

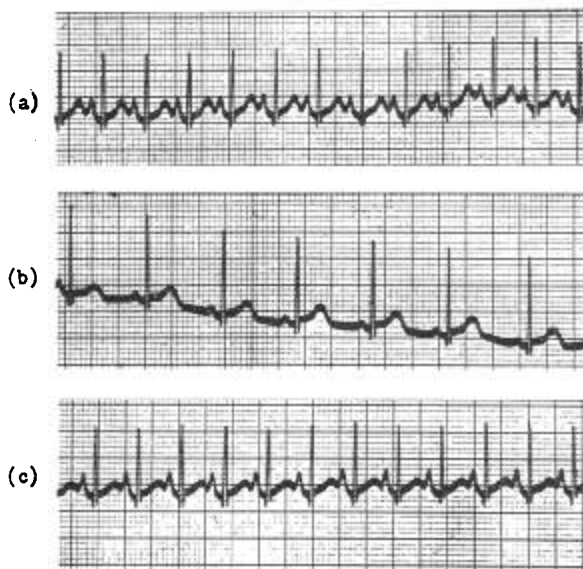


FIG. 2. Case 2. (a) Anesthesia in progress—heart rate 180 beats per minute. (b) Following succinylcholine 4 mg. intravenously—heart rate 100. (c) Response following atropine 0.06 mg. intravenously,—heart rate 180.

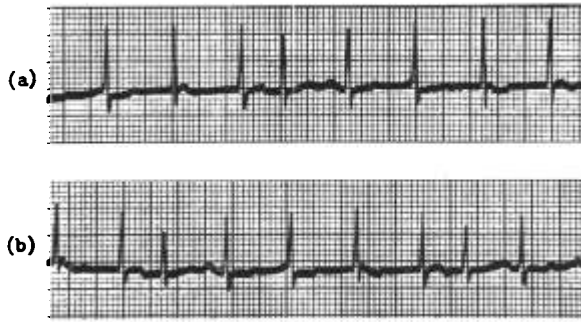


FIG. 3. Case 3. (a) During ether-oxygen induction—heart rate 140 beats per minute. (b) Thirty seconds after succinylcholine, 9 mg. intravenously,—heart rate 140.

*Case 2.*—A 2-month-old white boy of 9 pounds 11 ounces received scopolamine 0.06 mg. one hour before induction with cyclopropane oxygen anesthesia.

As shown in figure 2 (b), sinus rhythm is preserved with the bradycardia produced by succinylcholine. Note, however, the reduced P wave voltage during the bradycardia.

*Case 3.*—A 4-year-old white boy weighing 35 pounds received scopolamine, 0.133 mg. intramuscularly, one and one-quarter hours before induction with ether-oxygen anesthesia, and was not intubated prior to the monitoring.

The cardiac rate did not change in this example. The reason for “no change” may be that the control tracing (fig. 3a) shows an initial disturbance in sinus rhythm which is difficult to define from this single lead. If the rhythm is not sinus at the start, cholinergic effects might not be so readily demonstrable, at least until they were strong enough to effect the lower centers of impulse formation. On the other hand, ethyl ether probably prevents cholinergic effects of succinylcholine chloride.

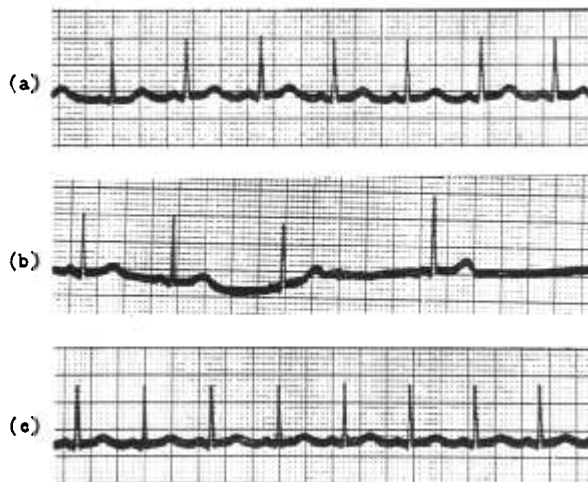

FIG. 4. Case 4. (a) Endotracheal anesthesia in progress 30 minutes—heart rate 120 beats per minute. (b) Following succinylcholine, 10 mg. intravenously, during endotracheal anesthesia and artificial pulmonary ventilation with oxygen—heart rate 50. (c) Following response to atropine 0.06 mg. intravenously—heart rate 120.

*Case 4.*—A 3-year-old Negro boy weighing 31 pounds received secobarbital suppository 30 mg. one and one-half hours before induction, and scopolamine 0.133 mg. subcutaneously one hour before induction with Lorfan-Nisentil-N<sub>2</sub>O-O<sub>2</sub> anesthesia. This boy was intubated prior to the monitoring; endotracheal anesthesia had been in progress 30 minutes and the cardiac rate was 120 (fig. 4). Following the administration of succinylcholine (10 mg. intravenously) with artificial pulmonary ventilation with oxygen, the heart slowed to a rate of 50; after atropine 0.06 mg. was given intravenously the heart rate increased to 120. This would seem to illustrate the same disturbed sinus mechanism with nodal escape abolished by atropine.

## DISCUSSION

The almost complete absence from the literature of descriptions of bradycardia in association with the intravenous administration of succinylcholine chloride (1) may be accounted for in several ways. One reason may be that the heart of the adult is not usually monitored through a precordial stethoscope, and, therefore, if bradycardia did occur, it might pass undetected. Secondly, in some instances, a high concentration of anticholinergic drugs, such as atropine or scopolamine, may have been present in the body, preventing the bradycardia when succinylcholine was administered. Thirdly, ethyl ether, which is often used in pediatric anesthesiology, would probably prevent the cholinergic effects of succinylcholine. In many instances, if bradycardia was observed, it was quite likely to be attributed to hypoxia from the respiratory depressant or apnea, since laboratory results on animals and humans reported that succinylcholine produced a tachycardia from ganglionic blockade (2).

We have attempted to disprove the hypoxic theory by the employment of succinylcholine intermittently during a sustained period of adequate pulmonary ventilation with oxygen. Also, the theory that traction of a viscera by the surgeon may account for the slowing seems to be excluded, since the bradycardia was observed *before* operation. Bradycardia could be due to intubation during light anesthesia from a vago-vagal reflex, especially since we recognize that this reflex tends to be even more marked if the patient is hypoxic. However, intubation as a cause seems to be eliminated by the fact that the bradycardia occurred either prior to intubation or when the endotracheal tube had been in place for over half an hour.

However, a possible explanation for the slowing of the heart in these cases is that in infants and young children who have a low true cholinesterase activity, acetylcholine derived from succinylcholine accumulates and causes bradycardia (nodal rhythm).<sup>\*</sup> This cholinergic response might suggest a danger in association with the use of the drug, especially if some hypoxia happens to be present. If the sinus

<sup>\*</sup> This explanation was given by Dr. Francis F. Foldes in a personal communication to the authors.

mechanism is disturbed by cholinergic responses in the presence of hypoxia, cardiac arrest may be a theoretical sequel if the lower centers including the node are unable to respond. If this should happen atropine might cure it.

#### SUMMARY

Bradycardia (nodal rhythm) following intravenous administration of succinylcholine chloride has been observed in infants and young children. Monitored examples of this bradycardia are shown electrocardiographically. Correction of this bradycardia with small dosages of atropine given intravenously is suggested.

#### REFERENCES

1. Johnstone, M.: Relaxants and Human Cardio-vascular System, *Anaesthesia* **10**: 122 (April) 1955.
2. Purpura, D. P., and Grundfest, H.: Blockade of Cardiac Synapses by Succinylcholine, *Science* **124**: 319 (Aug. 17) 1956.