

the radial and musculocutaneous nerves leave the neurovascular sheath within 4 centimeters distal to the tendon.

I, too, have performed the block successfully upon patients from the age of 2 to 10. Such a simple block as this could be used for all patients whether good or bad risks.

(3) In reading the literature before writing my brief paper, I discovered the technique described by Accardo and Adriani. I differ with them in that, whereas they indicate that one should seek paresthesia in each nerve they inject, I simply place the solution in the fat tissue on either side of the artery whence it infiltrates the nerves. I cannot believe that methods which seek to impale the nerves upon a needle, injections within a nerve bundle or injection of huge amounts of solution are without danger to delicate nerve tissue.

(4) I agree that the small purist doses that I used in this first series of 10 cases would prove inadequate in many attempted blocks. One is apt to measure too conservatively at first in order to prove a theoretical point. I now use 7 to 8 ml. on each side of the artery, making 14 to 16 ml. total for adults and perhaps 3 or 4 ml. on each side in children.

It appears to me that the diameter of this fat filled neurovascular space varies little in the skinny and in the muscular adult. I, therefore, use essentially the same amount in each. The obese individual receives 2 to 3 ml. extra in order to give what I trust is an adequate amount to diffuse through the extra fat.

(5) A patient with sufficient premedication will accept the hemostatic blood pressure cuff at 280 mm. of mercury without any anesthetic block. This is tantamount to anesthesia in pressure. However, in order that we are not forced to rely upon pressure anesthesia, which still gives rise to pain at the proximal edge of the blood pressure cuff, we find it expedient to block the: upper lateral cutaneous nerve (the deep block is distal to the circumflex axillary nerve which gives origin to this sensory nerve), posterior cutaneous nerve, intercostobrachial nerve, medial cutaneous nerve, and supraclavicular (cervical plexus nerves have a variable distribution).

The additional 6 to 10 ml. of solution added to the 14 to 16 ml. placed about the artery total about 20 to 26 ml. I always use 1:200,000 solution of epinephrine and trust that the chemical brake upon absorption plus the pressure of the blood pressure cuff will obviate systemic toxic reactions.

(6) Well premedicated semiconscious patients may squirm after the first hour or so and even activate the prime movers of the humerus. This activity is reduced greatly by placing a small pillow beneath their backs, reassuring conversation, and augmentation of the preoperative medication.

(7) One should not use an unfamiliar block on the "bad risk" patient. To do so simply adds to the bad risk.

I would advocate the use of this block of the great nerves of the upper arm in all cases of surgical procedures below the elbow. I find the block more simple to perform than the sympathetic block for the upper extremity and, therefore, have used this method for daily interruption of sympathetic nerves to the severely injured hand.

I thank Dr. Eather for the fruits of his greater experience and for this opportunity to discuss more points about a technique and site of anesthesia which I believe will be used more and more. I would go a step further, however, in predicting that this simple technique, when it has been further developed upon numerous cases, will completely supplant the supraclavicular brachial block.

PRESTON J. BURNHAM, M.D.
Salt Lake City, Utah

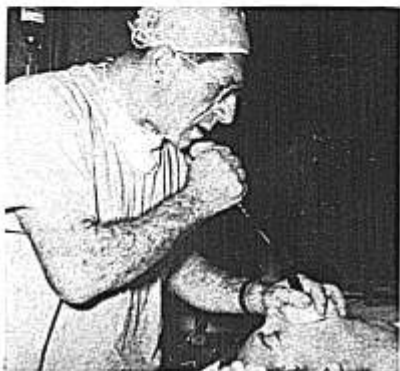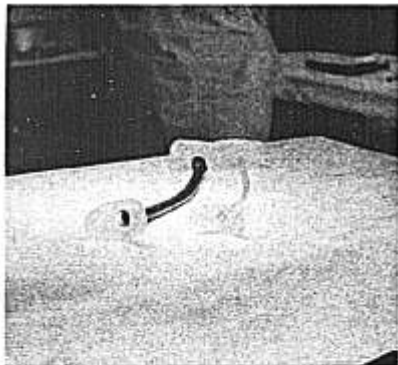
Mouth-to-Mouth Resuscitation

To the Editor.—After reading about Dr. Peter Safar's method of mouth-to-mouth resuscitation in the November-December 1957 Issue of ANESTHESIOLOGY [page 904] I wish to make the following comment.

It is sometimes quite difficult to insert an airway in an unconscious patient, especially if one is not trained in such procedure. Since most efforts at mouth-to-mouth resuscitation will occur in patients who are not completely relaxed, we have devised a method which will enable anyone to adequately inflate the lungs of the unconscious patient with or without an airway. The apparatus consists of a tube about 12 inches

long. At both ends there are elliptical shaped concave mouth pieces. There are three sizes of mouth pieces—adult, child and infant. The operator places it over the patient's mouth, takes a deep breath, applies gentle pressure to get a good fit over the mouth and expel his breath as forceful as is necessary to raise the chest. The same procedure is followed as Dr. Safar has described to maintain a clear airway. (See illustrations.)

ROBERT A. BERMAN, M.D.
Far Rockaway, New York



To the Editor.—May I comment on the tube with two oral masks which Dr. Robert Berman recommends [see previous letter] for mouth-to-mouth breathing.

Before recommending any instrument or method for emergency artificial respiration I would suggest evaluating it in the hands of laymen who perform on unconscious and paralyzed subjects. With some methods trained anesthesiologists produced good ventilation while laymen failed.