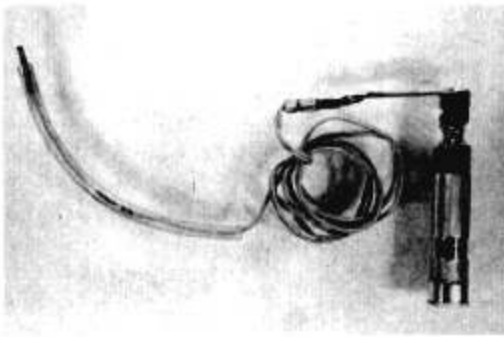


Device For Blind Nasal Intubation

Drs. Hideo Yamamura, Toru Yamamoto, and Morito Kamiyama of the Department of Anesthesia, University of Tokyo School of Medicine, recognizes that difficulties are frequently encountered in blind nasal intubation performed in patients with trismus and similar disorders. Repeated maneuvers in these instances, particularly in unanesthetized patients, are painful and not always successful.



Simple instrument consisting of electric bulb on end of vinyl-covered line connected to laryngoscope handle.

They have devised a simple instrument which has been used in 30 cases with only one failure. It consists of a small electric bulb (which is used for a children's laryngoscope) on the end of a thin vinyl-covered line with a metal connector to the ordinary laryngoscope handle (as illustrated).

Before intubation, a mark is made with adhesive tape on the line where the bulb just peers out of the tip of the tube. After the lubricated tube is inserted into the well-sprayed pharynx, the line is placed into the tube up to the mark.

The position of the tip of the tube can be seen from outside on the throat as an illumination. When the light is bright in the median line of the throat, the tip is on the anterior pharynx, and only a further push will complete the intubation. When the light is indiscernible, the tip is usually in the esophagus.

The drawbacks of the method are: (1) it requires a dark room; (2) some difficulty might be found in the patient with a thick throat, and (3) the bulb may feel hot to the patient after prolonged use (their patients have not complained of this discomfort).

CORRESPONDENCE

"Pretracheal" Nerve Tract

To the Editor.—Anesthesiologists will find interesting reading in the studies of Drobnik, concerning the cervical sympathetic nerve tracts (Drobnik, T.: *Topographisch-anatomische Studien ueber den Hals sympathicus*, Arch. Anat. u. Entwicklungs., pp. 339–367, 1887) and referred to in *Piersol's Human Anatomy* (ed. 9, by G. C. Huber, Lippincott, 1930, p. 1360) as "pre-tracheal nerve."

This nerve tract is concerned with the structure and function of the "esophagopharynx" (Evans, T. H.: *Esophagopharynx*, Special Area in *Human Pharynx, Laryngoscope* 54: 148 (March) 1944; Abstract, *Anat. Rec.* 127: 412 (Feb.) 1957).

THOMAS HORACE EVANS, M.D.
(*Professor Emeritus of Anatomy*)
Freeport, Long Island