

CASE REPORTS

Precordial Click

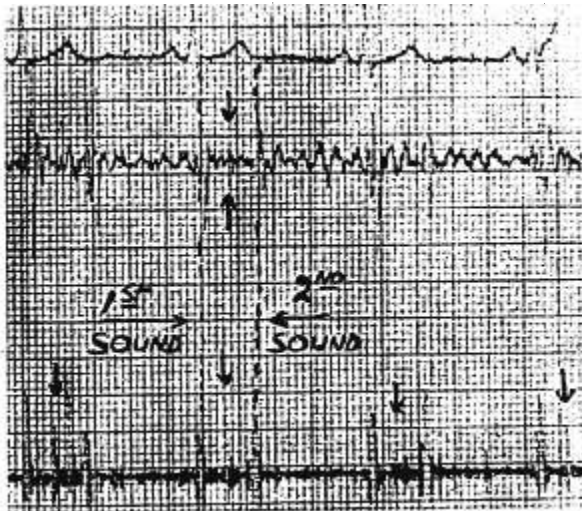
Captain Rudolph H. DeJong of the U. S. Army Hospital in Munich, Germany, believes the following case report, describing the course of events in a patient with pneumothorax following brachial plexus block, might be of interest to other anesthesiologists, since it demonstrates the occurrence of a clearcut physical sign (precordial click) of pneumothorax before clinical or radiographical confirmation was possible. Hamman's sign, a precordial, intrasystolic, clicking, metallic third heart sound, is usually interpreted clinically as presumptive evidence of mediastinal emphysema. Less well known is the fact that it has also been elicited in pneumothorax, without associated presence of pneumo-mediastinum.

A 19 year old soldier was admitted to the hospital with a diagnosis of dislocation of the left elbow. His physical examination was normal except for an obviously dislocated left elbow, rather marked obesity and a combative

inebriation. The chest showed freely expanding lungs bilaterally, the heart was not enlarged and no murmurs, rales or other unusual sounds were auscultated.

Since the patient had a full stomach and was quite obese, a left supraclavicular brachial plexus block was performed with a 22-gauge safety hub needle. No premedication was given. A closed reduction was performed with ease and the patient returned to the ward in good condition. The patient did not complain of any chest pain, did not cough, and auscultation, percussion and inspection did not reveal any apparent pneumothorax at that time.

About four hours after the block the patient woke up complaining of moderate substernal discomfort. The night nurse at that time noted "a funny, clicking noise coming from the patient's chest." The night physician diagnosed "mediastinal emphysema" on the basis of Hamman's sign (clicking chest sound syn-



Logarithmic tracing of precordial phono-cardiogram showing a clearly defined, medium-pitched extra sound midway between the first and second heart sounds.

chronous with heart beat) and prescribed a mild analgesic plus careful observation. A chest roentgenogram at that time showed normal chest without any evidence of free air in the thorax or mediastinum. Not until the following day (32 hours postblock) did a chest roentgenogram taken in deep expiration show a small (approximately 10 per cent) pneumothorax. At that time a definite lag, hyperresonance and decreased breath sounds of the left hemithorax were observed. A very clear, clean, metallic clicking sound, like tumbling coins, which was synchronous with the pulse, could be heard by the unaided ear at the bedside. The patient was no longer uncomfortable. There was no dyspnea, no cyanosis and

no subcutaneous emphysema. The trachea was in midline and the cardiac area of dullness was not displaced. The neck veins were flat. Blood pressure and pulse were stable. Respiration was never faster than twenty per minute. The electro-cardiogram was normal. A precordial phono-cardiogram showed a clearly defined, medium-pitched extra sound midway between the first and second heart sounds, best demonstrated in the logarithmic ("aural presence") filter tracing, as illustrated (Figure 1). Two days post-block the clicking sound could only be elicited occasionally by moving the patient into different positions (best was sitting up, leaning slightly to the left).

Fluphenazine

Dr. Olga Schweizer of the Memorial Center in New York City reports that although the symptoms resulting from extrapyramidal stimulation produced by the phenothiazine derivatives have been described in the neurological and psychiatric literature, very little attention has been paid to these untoward effects by the anesthesiologist. A recent experience indicates that the use of these drugs should be coupled with a better understanding of the side effects which ensue from a relatively small dose.

An intramuscular injection of 5 mg. of fluphenazine was administered to a young healthy nurse who complained of moderate nausea, with some relief of her symptoms. Approximately 20 hours later, while at work in the recovery room, she noted difficulty in reading the blood pressures she was recording. Marked anxiety, inability to lower her eyes, generalized tremors, unilateral spasm of the neck muscles and muscular contracture verging on opisthotonus developed during the course of the next hour. Aside from these symptoms and signs the physical examination was normal. Although a considerable period of time had elapsed since the original medication, the consulting neurologist on the basis of previous experience diagnosed the condition as a pheno-

thiazine reaction. Repeated doses of intravenous amobarbital were administered during the course of the next twenty-four hours to relieve the symptoms which recurred whenever the sedation wore off.

Darling noted the frequent occurrence of extrapyramidal symptoms similar to those experienced by this patient following the use of fluphenazine. The absence of untoward neurological side effects in a recent Memorial Center series of 1,400 patients treated with one dose of a phenothiazine derivative upon arrival in the recovery room may be due to the fact that the patients were still under the influence of the anesthetic agent at the time the drug was administered.

Although the extrapyramidal effects of the phenothiazine derivatives are usually manifested after repeated dosage, the present case and several others not as well documented which have come to our attention indicate that untoward effects may follow minimal dosage. It would seem wise, therefore, in the light of these findings, to re-evaluate the indiscriminate use of these drugs for conditions such as preoperative sedation and postoperative nausea and vomiting.

Downloaded from http://ajph.gapub.org/ by guest on 11 June 2021