

## A METHOD OF MONITORING MUSCULAR RELAXATION BY THE INTEGRATED ABDOMINAL ELECTROMYOGRAM

B. RAYMOND FINK, B.Sc., M.B.

THE dosage of myoneural blocking drugs used to relax the abdominal wall muscles during general anesthesia is generally based on clinical judgment. Although results are usually adjudged satisfactory, even the best judgment sometimes errs and a practicable method of relating the dose more critically to physiological requirements is desirable. Thesleft<sup>1</sup> and Hanquet<sup>2</sup> administered succinylcholine by continuous intravenous drip and used the disappearance of the finger flexion response to ulnar nerve stimulation as an index of adequate myoneural blockade. Foldes<sup>3</sup> utilized the onset of apnea as the sign of succinylcholine overdose. Both end points have the disadvantage of referring to muscles other than those of the abdominal wall for which the myoneural blocking concentration may be quite different.<sup>4</sup> Furthermore, determination of the presence of apnea involves a risk of hypoventilation, and apnea due to neuromuscular block is not immediately distinguishable from that of hyperventilation or other causes.

Bendixen and co-workers<sup>5</sup> demonstrated residual weakness due to neuromuscular block by measuring the "inspiratory force," the negative pressure developed against an occluded airway. A method of correlating this force with the integrated diaphragmatic electromyogram has been described<sup>6</sup> but a relation to operating conditions has not been defined.

Ideally, an index of abdominal relaxation would be based on the mechanical tension of the anterior abdominal wall muscles. Direct measurement of this tension is impractical, but an indirect estimate should be obtainable from a related function, namely the electrical activity of the muscles. This arises from the fact that during contraction of a skeletal muscle

the electrical activity is proportional to the mechanical tension, if the muscle does not shorten<sup>7, 8</sup> or shortens at constant speed.<sup>9</sup> Even with uncontrolled shortening the deviation from linearity may be inconsiderable.<sup>10</sup>

A rough guide to the degree of activity in a contracting muscle is given by the amplitude of a conventional ink electromyogram (EMG). This was used as such by Poulsen and Hougs<sup>11</sup> and by Churchill-Davidson and Richardson<sup>12</sup> in studies of myoneural block in unanesthetized man. However, the EMG tracing is too irregular for rapid evaluation and bears no precisely determined relation to the activity. Electronic integration of the EMG overcomes this objection. The integrated or total activity per unit time is obtained. When measured in successive intervals, the effect of varying physiological conditions can be observed.

Few clinical studies have as yet been made with the aid of integrated electromyography.<sup>13, 14</sup> This paper describes a technique for measuring the electrical activity of the parietal musculature during abdominal operations and reports on the use of this technique to regulate the administration of a muscle relaxant, succinylcholine chloride (Anectine).

### METHODS

For the purpose of the present study, an instrument was designed in which the filtered, amplified and rectified action potentials were integrated in a circuit of very long decay time, thus insuring a close approximation to true integration. The time constant of the integrator could be set at 0.3 or 3 seconds, and the decay time was fixed at 200 times the time constant. By switching to the longer time constant, the slope of the integral trace was reduced by a factor of 10, without changing the gain of the amplifiers. This was useful in observing very intense activity when the integral would otherwise rapidly have gone off screen. Details of the circuit are being published elsewhere.<sup>15</sup> A block diagram of the

Presented at the Annual Meeting of the American Society of Anesthesiologists, Inc., Miami Beach, Florida, October 8, 1959, and accepted for publication November 19, 1959. Dr. Fink is in the Department of Anesthesiology, College of Physicians and Surgeons, Columbia University, New York, N. Y.

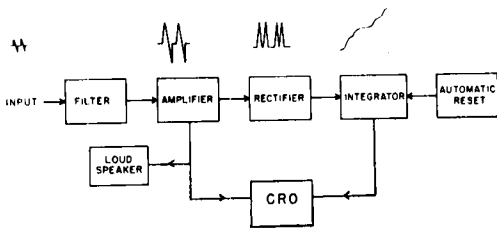


Fig. 1. Block diagram of recording apparatus.

apparatus is given in figure 1. The integrated voltage was displayed continuously on a cathode ray oscilloscope, the electrical activity during any period being given by the increase of the integral during that period. The trace was returned to base line at fixed intervals; the rise of the trace in each interval constituted the measure of muscular tension (fig. 2).

The action potentials were picked up through two unipolar insulated needle electrodes one and a half inches long inserted between the iliac crest and rib-margin, and led to the recorder (Electronics for Medicine multichannel cathode ray oscilloscope) through a shielded, grounded cable. The needles were advanced obliquely through the skin and subcutaneous fat until they felt to pierce the deep fascia and penetrate the muscle. EMG activity was immediately visible on the screen, confirmed by a characteristic continuous 'rat-atat' heard in the loud speaker. The exact depth of the electrodes in the muscle mass was not critical; the distance between the needles

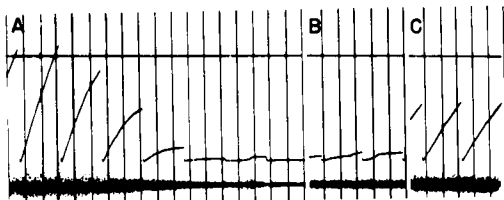


FIG. 2. Effect of succinylcholine on abdominal muscle activity during a laparotomy. Ventilation controlled manually. Lower trace: EMG of oblique-transverse muscle group; middle trace: integrated EMG; upper trace: reference level of activity. When the integral reached the reference level, 50 mg. of succinylcholine were injected intravenously. The record begins at A, 30 seconds later, and shows a rapid decline of activity as the relaxant became effective. Level of noise during complete paralysis is negligible. B, 6 minutes later, shows commencing recovery. C, one minute later than B, shows further increase of activity. Time markings 1 second.

was about 3 mm. The small distance between the electrodes tended to reduce interference from the electrocardiogram, and the latter was in practice eliminated entirely by the use of a 100–2,500 c.p.s. band pass filter incorporated in the amplifier. The patient was grounded through a 25 gauge hypodermic needle inserted subcutaneously. The needles were taped to the skin and protected from external pressure by a shallow plastic dish strapped to the abdomen. Somewhat surprisingly, surgical manipulations produced little or no spurious activity in the electromyogram. This was evident from the electrical "silence" during periods of total myoneural block. Electrocautery did not interfere with recording except when actually in use in the wound. The oscilloscope traces returned to normal as soon as cauterization was interrupted.

The subjects were 33 patients undergoing a variety of abdominal operations (table 1) and were otherwise unselected except that excessively obese patients were excluded from the study because the electrodes were too short to reach the muscle layer.

#### PROCEDURE

Sleep was induced with intravenous thio-pental in 2.5 per cent solution. Orotracheal intubation was performed after a period of inhalation of oxygen and the intravenous injection of 60 to 100 mg. of succinylcholine. Anesthesia was maintained with a mixture of nitrous oxide (4 liters per minute) and oxygen (2 liters per minute), supplemented by thio-pental in doses of 50–100 mg. or of meperidine in doses of 10–20 mg. The indication for injection of the supplemental drugs was the occurrence of skeletal or visceral responses other than activity of the abdominal muscles, referable to excessively light anesthesia, such as rising blood pressure, limb movement, facial grimaces, bucking (1 patient) and hiccough (6 patients). The latter was evanescent and unrelated to the respiratory rhythm, occurring once in five of the patients and twice in the sixth patient, each episode lasting less than 30 seconds. In the first two cases hiccough was treated by additional succinylcholine. Subsequently, because of the relative difficulty of paralyzing the diaphragm with succinylcho-

TABLE 1  
SYNOPSIS OF RESULTS IN 33 ABDOMINAL OPERATIONS WITH EMG MONITORING OF RELAXATION

Operation	Sex	Age	Weight (pounds)	Thiopental (mg.)	Meprobamate (mg.)	Succinylcholine (mg.)	Duration of Anesthesia (hours)	Duration of Operation (hours)	Remarks on Immediate Postanesthesia Respiration
1. Splenectomy; Colectomy	M	61	156	500	—	D 1,500	4.5	4	Normal.
2. Vagotomy; R & L Sympathectomy	F	38	124	500	—	D 2,000	4.3	3.8	No tug.
3. Exploratory laparotomy; Gastrostomy	F	53	92	300	—	D 1,200	1.5	1	No tug.
4. Gastrectomy; Vagotomy; Appendectomy	M	52	130	750	—	D 2,900	3.5	3.0	
5. Cholecystectomy	F	60	147	300	—	D 660	0.9	0.9	
6. Aortic aneurysm; Art. embolectomy	M	68	160	1,600	—	D 4,460	9.25	7.25	Full SR in 2 minutes. No tug.
7. Colotomy (polyp)	M	64	225	225	—	D 980	1.7	1.3	No lag.
8. Umbilical herniorrhaphy	M	23	350	350	—	D 240	0.75	0.6	
9. Gastrectomy; Vagotomy	M	46	1,050	1,050	—	1,240	3.8	3.6	Normal immediately on ending CR.
10. Enterectomy	M	27	1,360	875	—	1,360	6	5.7	Ventilator.
11. Radical hysterect.	F	38	121	225	175	910	5	4.7	15 minutes delay (meprobamate).
12. Cholecystectomy; CD exploration	F	47	158	175	—	400	2.5	2.0	No delay.
13. Endometrial cystectomy	F	36	134	175	25	440	2.5	2.0	Opens eyes to order.
14. Cholecystectomy	M	56	178	500	—	800	2.5	2.3	Awake; normal respiration.
15. Cholecystectomy	F	39	148	500	100	1,200	3.5	3.25	No tug; full spontaneous respiration.
16. Hysterectomy	F	56	350	350	50	720	1.75	1.4	Awake; full respiration.
17. Cholecystectomy; Closure colostomy	M	46	275	350	—	840	2	1.7	Breathing well.
18. Prostatectomy, suprapubic	M	60	158	180	—	200	0.8	0.5	Deep respiration after Tensilon 5 mg.; opens eyes.
19. Prostatectomy, suprapubic	M	83	103	180	—	100	0.75	0.4	
20. Ventral Herniorrhaphy	M	51	244	900	—	2,900	3	1.75	
21. Exploratory laparotomy (w/ stomach)	M	60	162	250	—	450	1.25	1.0	
22. Colectomy; Colectomy	F	41	825	250	—	530	4.2	3.8	Strong. Normal in 30 seconds.
23. Colon resection	F	80	165	700	140	550	4.5	4.25	Normal SR in 30 seconds.
24. Salpingo-oophorect.	F	52	150	450	—	725	2.75	2.5	Normal SR in 15 seconds. Complains of cold.
25. Esophageal stricture	F	76	114	1,900	55	2,650	11.25	10.75	Full SR-oropharyngeal airway.
26. Inguinal herniorrhaphy	M	46	125	400	—	350	1.5	1.0	Ventilator; Tensilon 5 mg. + 5 mg.
27. Hysterectomy	F	59	140	650	20	1,150	4.25	3.75	Ventilator; full SR opening eyes.
28. Subtot. gastrectomy; Vagotomy	M	54	106	300	70	650	4.5	4.0	Ventilator; immediate SR; speaking in 2 minutes.
29. Colectomy; Splenectomy	M	74	180	600	500	850	9.25	8.5	Postoperative apnea; SR on deflating cuff.
30. Excision of aortic aneurysm (abdom.)	M	54	106	300	90	350	2.25	1.5	Ventilator. Chronic asthma. Tensilon 10 mg.
31. Exploratory lapar.	F	82	128	725	380	1,200	8.5	8.0	Ventilator; full SR in 30 seconds. Conversing 2 minutes later.
32. Excision of aortic aneurysm (abdom.)	M	63	140	500	130	770	4	3.5	
33. Total colectomy	M	21	140	500	—	—	—	—	

D—Intravenous drip of succinylcholine. CR—Controlled respiration. SR—Spontaneous respiration.

line,<sup>1</sup> hicough was treated with a central depressant, either thiopental (50 mg.) or meperidine (20 mg.).

Respiration was manually controlled in all but six patients in whom a mechanical ventilator was used. In 4 of these 6 patients the occipito-frontal electroencephalogram was also monitored. Electroencephalographic level 1 or 2 was maintained throughout.

The electrical activity of the abdominal muscles before tracheal intubation was taken as the reference level in the first 8 patients, and an intravenous drip of 0.4 per cent succinylcholine regulated so as to maintain activity below this level. In some of the later cases the abdomen was deliberately allowed to tighten and the level of troublesome muscle activity determined after the skin incision was made. This level was approximately ten times higher than the resting level. Increments of 50 mg. of succinylcholine were injected whenever the activity subsequently approached the higher level. It was soon found that the reference level was much the same in all pa-

tients, and the preliminary test of tension dispensed with.

RESULTS

Satisfactory electromyographic recording was obtained in all patients immediately with the first insertion of the electrodes. Although the electrodes were not placed in a precise location within the transverso-oblique muscle mass, activity was always present. It is therefore likely that the activity was generalized throughout the muscles. There was surprisingly little variation in activity from patient to patient and the same amplifier gain and integrator time constant were, in fact, used in most of the cases.

Electromyographic activity increased when the skin incision was made and there was a further increase when the muscle layer was entered. During division of the muscles 50 mg. increments of succinylcholine were required every 5 to 10 minutes, and this dosage continued during the initial intraperitoneal exploration. The injections were timed ex-

TABLE 2  
HOURLY REQUIREMENT OF SUCCYNYLCHOLINE (mg.)

Case Number	Hour of Anesthesia										
	1	2	3	4	5	6	7	8	9	10	11
9	580	360	320	120							
10*	340	240	180	240	300	120					
11	310	280	160	160	100						
12	200	120	100								
13	240	200									
14	420	360	240								
15	420	540	240								
16	420	300									
21	340	220									
22	280	150	100	0							
23	360	150	100								
24	500	250									
25	200	450	350	250	300	150	200	200	100	100	200
28*	350	250	400	300							
29 <sup>†</sup>	350	150	50	100							
30 <sup>†</sup>	200	50	100	50	100	0	50	200	100		
31	300	100									
32 <sup>†</sup>	350	275	150	50	200	100	50	0	200	100	200
33 <sup>†</sup>	370	250	100	50							
Average	360	250	190	150	200	90	100	130	130	100	200
S.D.	83	118	107	90	126						

\* Group "C."

<sup>†</sup> Electroencephalogram monitored.

clusively by reference to the electrical activity seen on the oscilloscope screen (fig. 2). After a period of complete paralysis the EMG activity gradually recovered over a period of several minutes; the recovery of muscle tone detected in the oscilloscope often continued for one minute or more before any change in the resistance to inflation was appreciated in the breathing bag.

The activity tended to decrease as the operation proceeded (table 2). The intervals between succinylcholine injections grew longer and the period of paralysis produced by each 50 mg. injection gradually increased (fig. 3). Temporary increases in EMG activity occurred during traction on structures within a mesentery, and transient bursts were often observed during dissection at the visceral border of a mesentery, decreasing after division of the mesentery. The episodic activity was superimposed on a steady, slowly changing background activity (fig. 2, section B) and was of no significance as far as relaxation was con-

cerned, although this was not realized in the early cases. Its nature is discussed in a later section. Cutting and clamping of the viscera proper was without effect on the electromyogram.

A list of the operations together with summarized results is presented in table 1. For the purpose of analysis the studies have been arranged in three groups (table 3). In group A, comprising 9 patients, succinylcholine was administered continuously by intravenous drip. The dose of succinylcholine averaged 9.8 mg./minute. In groups B and C, succinylcholine was injected in divided doses of 50 mg. Group B consists of 18 patients in whom respiration was controlled manually. In these patients the dosage of succinylcholine averaged 4.7 mg./minute. Group C includes 6 patients whose respiration was maintained by a mechanical ventilator. In Group C the succinylcholine requirement averaged 2.5 mg./minute. Nitrous oxide-oxygen anesthesia was supplemented with thiopental, and in 13 pa-

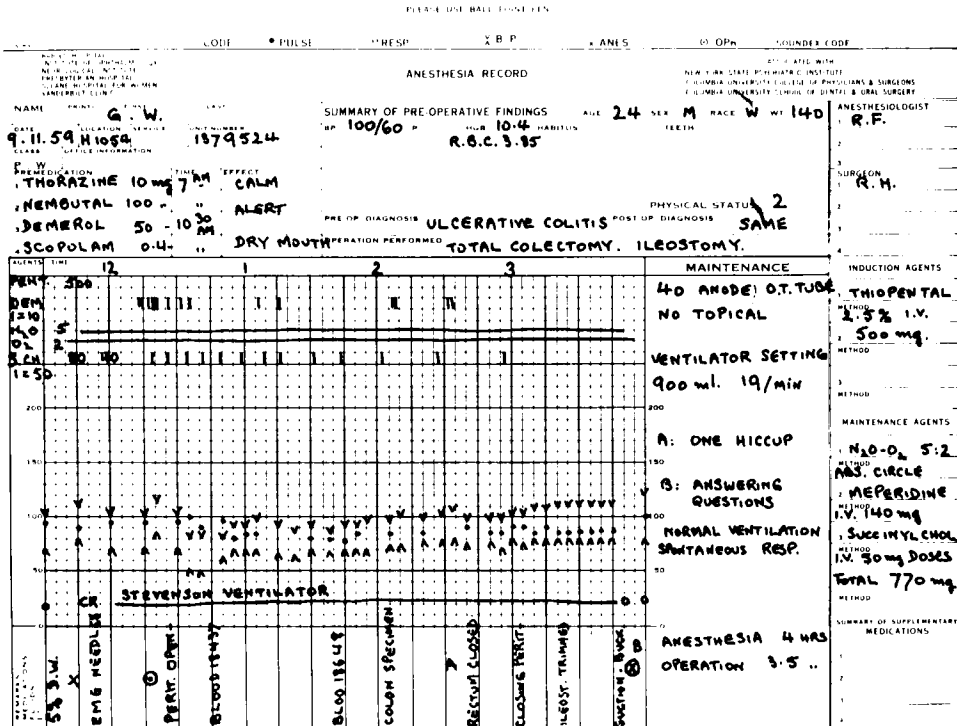


FIG. 3. Anesthesia record (case 33) showing typical time course of drug administration. Each bar in the upper row represents 10 mg. of meperidine. Each bar in the second row represents 50 mg. of succinylcholine.

TABLE 3  
AVERAGE DRUG CONSUMPTION, ACCORDING TO PATIENT GROUP

	Weight (pounds)	Thiopental (mg.)	Meperidine (mg.)	Succinylcholine (mg.)	Duration Anes. (hours)	Succinylcholine (mg., hr.)
Group A*	151	600	0	1,870	3.2	580
Group B	146	510	80	780	3.0	260
Group C	132	610	220	1,000	6.8	150

\* Group A—Succinylcholine drip. Cases 1 to 8, 20. Group B—Succinylcholine 50 mg. increments, manual controlled ventilation. Cases 9, 11, 12, 13, 14, 15, 16, 17, 18, 19, 21, 22, 23, 24, 25, 26, 27, 31. Group C—Succinylcholine 50 mg. increments, mechanical ventilation. Cases 10, 28, 29, 30, 32, 33.

tients also with meperidine. The average supplement of thiopental per patient was 600 mg.; of meperidine, when used, 130 mg. Electroencephalographic monitoring of four patients whose respiration was mechanically controlled showed that EEG level 1 or 2 was maintained throughout.

At the end of the operations recovery of spontaneous ventilation occurred promptly except in 1 case, in whom apnea persisted for 10 minutes, ending when the endotracheal cuff was deflated. Depression of ventilation was present in 3 patients, 1 in group A and 2 in group C. The amounts of succinylcholine used in these patients was 2,900 mg., 1,150 mg., and 1,200 mg. at hourly rates of 960 mg., 270 mg., and 140 mg. respectively. In each case, respiratory volume was restored to normal by the intravenous injection of 10 mg. of edrophonium.

Recovery of consciousness, determined by the patient's response to commands such as "open your eyes," usually occurred with a few minutes of discontinuing the nitrous oxide. In none was it delayed more than 10 minutes.

From the point of view of the surgeon, the results were generally satisfactory. Comment about inadequate relaxation was made on two occasions, after a sudden change in the site of the manipulations. Apart from the three instances of delayed recovery of respiration, there were no postoperative complications attributed to anesthetic technique.

#### DISCUSSION

One object of this study was to investigate the practicability of integrated electromyography as a clinical technique. Setting up the apparatus was simple, consisting essentially of

connecting the recorder to the power supply and the patient to the recorder. The EMG was obtained without difficulty immediately on inserting the electrodes. It was identified by characteristic volleys in the loud speaker, corresponding to the series of spikes on the oscilloscope screen. The EMG was easily distinguished from spurious activity, such as three phase, 60 cycle hum and slow movement artifacts. The former was eliminated by grounding, the latter by filters incorporated in the amplifier. The loudspeaker was turned off during electrocauterization. There was generally a remarkable freedom from noise and complications.

In sum, with the technique described, the integrated electromyogram of the abdominal muscles was obtained with the same facility as an electrocardiogram or electroencephalogram.

It was next to be established whether the technique could be used as a criterion of abdominal muscle relaxation. The tension of the abdominal wall depends mainly on active muscle contraction. Passive stretch ordinarily contributes very little, since stretching a resting muscle fiber causes no rise in tension until the length exceeds 125 per cent of the resting length.<sup>16</sup> Hence the remarkable flaccidity of the paralyzed abdomen. If the abdominal wall becomes tense, active contraction of the abdominal muscles must be present and action potentials should be recordable. A direct relation between electrical activity and tension is known to exist when contraction is isometric or when shortening occurs at constant speed.<sup>8, 9</sup> How far such conditions prevail in the abdomen is uncertain, but Bergstrom<sup>10</sup> has shown that even in uncontrolled shortening the integrated electrical activity increases continuously

with the strength (mechanical impulse) of the movement. The present evidence indicates that the electrical activity of the abdominal wall muscles does increase steadily with the mechanical tension regardless of the degree of myoneural block. The relation, though not necessarily linear, was sufficiently regular to validate the use of the electrical activity as an index of abdominal muscle tension. This opinion is supported by observations made during mechanical ventilation at constant alveolar  $\text{CO}_2$  tension.<sup>17</sup> The electrical activity of the diaphragm varied in the same direction as the degree of myoneural block determined by finger twitch tension. There was a parallel variation in the abdominal activity.

The conclusion seems warranted that the integrated electromyogram is a valid and consistent guide to the mechanical tension of the abdominal wall muscles.

The remarkable differences in succinylcholine dosage between the three groups in table 3 require explanation. In group A, where the relaxant was administered by continuous intravenous drip, the reference level of activity was set very low. With later experience, in groups B and C, a higher reference level was found satisfactory, correspondingly reducing the frequency of succinylcholine injections.

The lowest requirement for succinylcholine occurred in group C, where respiration was controlled with a mechanical ventilator. Hyperventilation, was probably present in all the patients in this group. Hyperventilation is known to increase the effective depth of anesthesia<sup>18</sup> and to reduce the requirement for relaxant.<sup>19</sup> The usefulness of the integrated EMG is that it enables the clinician to assess the requirement without guesswork.

There was a distinct tendency to decreased requirement for succinylcholine as each operation proceeded (table 2). This contrasts with Thesleff's statement that the requirement is constant when judged by finger flexor paralysis<sup>1</sup> and with Poulson and Houghs' demonstration of tachyphylaxis to succinylcholine in man.<sup>20</sup> In Thesleff's and in Poulson's work, the extent of myoneural block was tested by the response to a constant stimulus. However, during operations the stimulus to the abdominal muscles is not constant but varies with the intensity of surgical stimulation, and also

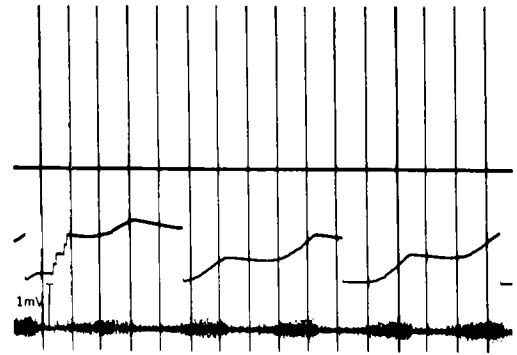


FIG. 4. Abdominal muscle activity during spontaneous respiration. Time lines, 1 second. Activity decreases rhythmically with each inspiration. Compare absence of rhythmic decrease during controlled respiration in figure 2.

with the anesthetic level. In group C, where there was an approximately steady EEG level of anesthesia, the requirement for succinylcholine leveled off after four hours. This may have represented an equilibrium between the rates of detoxication and administration, but if so a slower recovery from paralysis than observed would have been expected. An alternative explanation is that the effect of surgical stimulation diminished with the hours, possibly due to fatigue in neural circuits.

During spontaneous respirations there occurred a well marked expiratory phasic increase in abdominal muscle activity, both before and after induction of anesthesia (fig. 4). Campbell,<sup>21</sup> using less sensitive recording methods, observed a similar rhythm in volunteers when ventilation exceeded 40 liters per minute. The phasic expiratory increase in abdominal muscle activity observed during anesthesia probably originated in the expiratory center since it disappeared with controlled hyperventilation, leaving a lesser steady tonic activity, mediated perhaps by the brain-stem reticular system.<sup>22</sup> The reduced requirement for relaxant and the seeming increase in depth of anesthesia with controlled respiration are partly accounted for by the absence of the expiratory increment of abdominal muscle activity ordinarily present in spontaneous respiration.

At low levels of activity the EMG often reveals small changes entirely unappreciated by the surgeon or the anesthesiologist (fig. 2, B). These fluctuations were not significant as

far as the need for succinylcholine was concerned. Irregular ones were probably artifacts, but others consisted of brief repetitive discharges typical of motor unit activity. The latter type coincided with surgical dissection of the posterior parietal peritoneum and mesentery and may represent spinal reflex activity.

Although the series is small, the results with EMG control of relaxation have been sufficiently clear-cut to warrant a tentative appraisal of its scope. The integrated EMG is probably a more accurate guide to abdominal muscle tone than the feel of the breathing bag, but constitutes a rather superfluous refinement under these circumstances. However, when a mechanical ventilator is substituted and there is no bag to feel, the abdominal EMG assumes a useful role in guiding the management of abdominal relaxation.

#### SUMMARY

Integrated electromyography of the abdominal wall muscles is a clinical technique for monitoring the relaxation of the abdomen at operations. Thirty-three patients are presented in whom the EMG was used to direct the administration of succinylcholine. Maintenance of relaxation was satisfactory. The technique is most useful when respiration is controlled with a mechanical ventilator.

This study was supported by Grant RG4717 from the National Institutes of Health, United States Public Health Service.

#### REFERENCES

1. Thesleff, S.: Investigation of muscle-relaxing action of succinyl-choline-iodide in man, *Acta physiol. scandinav.* **25**: 348, 1952.
2. Hanquet, M.: Étude du blocage de la transmission neuromusculaire chez l'homme, *Acta Anesthesiol. Belg.* **5**: 103, 1954.
3. Foldes, F. F.: *Muscle Relaxants in Anesthesiology*, Springfield, Illinois, Charles C Thomas, Publisher, 1957.
4. Unna, K. R., and Pelikan, E. W.: Evaluation of curarizing drugs in man, *Ann. New York Acad. Sc.* **54**: 480, 1951.
5. Bendixen, H. H., Surtees, A. D., Oyama, T., and Bunker, J. P.: Postoperative disturbances in ventilation following use of muscle relaxants, *ANESTHESIOLOGY* **20**: 121, 1959.
6. Fink, B. R., Ngai, S. H., and Holaday, D. A.: Effect of air flow resistance on ventilation and respiratory muscle activity, *J. A. M. A.* **168**: 2245, 1958.
7. Inman, V. T., Ralston, H. J., Saunders, C. M., Feinstein, B., and Wright, E. W., Jr.: Relation of human electromyogram to muscular tension, *Electroencephol. & Clin. Neurophysiol.* **4**: 187, 1952.
8. Lippold, O. C. J.: Relation between integrated action potentials in human muscle and its isometric tension, *J. Physiol.* **117**: 492, 1952.
9. Bigland, B., and Lippold, O. C. J.: Relation between force, velocity and integrated electrical activity in human muscles, *J. Physiol.* **123**: 214, 1954.
10. Bergström, R. M.: Über den Zusammenhang der von voluntärer muskellaktion erbrachten bewegungsgrösse und der elektrischen aktivität des muskels, *Acta physiol. scandinav.* **44**: 184, 1958.
11. Poulson, H., and Hougs, W.: Succinylcholine, *Lancet* **2**: 199, 1952.
12. Churchill-Davidson, H. C., and Richardson, A. T.: Neuromuscular transmission in myasthenia gravis, *J. Physiol.* **122**: 252, 1953.
13. Breinin, G. M.: Quantitation of extraocular muscle innervation, *A. M. A. Arch. Ophthalmol.* **57**: 644, 1957.
14. Fink, B. R., Hanks, E. C., Holaday, D. A., and Ngai, S. H.: Monitoring of ventilation by integrated diaphragmatic electromyogram: determination of CO<sub>2</sub> threshold in anesthetized man, *J. A. M. A.*, in press.
15. Fink, B. R., and Scheiner, M.: Computation of muscle activity from integrated electromyogram, *I. R. E. Trans. Med. Electronics*, **6**: 119, 1959.
16. Ramsey, R. W., and Street, S. F.: Isometric length-tension diagram of isolated skeletal muscle fibers of frog, *J. Cell. & Comp. Physiol.* **15**: 11, 1940.
17. Ngai, S. H., Hanks, E. C., Fink, B. R., Holaday, D. A., and Papper, E. M.: Quantitative study of action of imbratil and its modification in man, *ANESTHESIOLOGY* **20**: 653, 1959.
18. Geddes, I. C., and Gray, T. C.: Hyperventilation for maintenance of anesthesia, *Lancet* **2**: 4, 1959.
19. Dundee, J. W.: Influence of controlled respiration on dosage of thiopentone and *d*-tubocurarine chloride required for abdominal surgery, *Brit. M. J.* **2**: 893, 1952.
20. Poulson, H., and Hougs, W.: Effect of some curarizing drugs in unanesthetized man, *Acta anaesth. scandinav.* **2**: 107, 1958.
21. Campbell, E. J.: *The Respiratory Muscles and the Mechanics of Breathing*, Chicago, Year Book Publishers, 1958, p. 28.
22. Ward, A. A., Jr.: Chapter in Reticular Formation of the Brain, Symposium, Boston, Little, Brown & Co., 1958, p. 264.