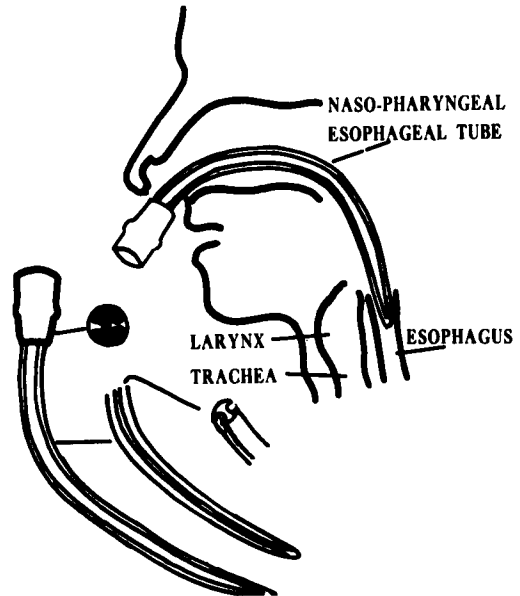


### New Design for Nasopharyngeal Airway

Dr. Robert A. Berman of Far Rockaway, New York, has designed a new type nasopharyngeal airway which he expects will overcome some of the difficulties of the ordinary type.

As shown in the accompanying figure, the airway is a tube with two channels and an adapter to fit into one side of the nose. Experience shows that it will enter the esophagus. With the end in the upper esophagus, an adequate airway is established and the lungs can be inflated without air entering the stomach. The airway is designed more as an obturator than as a breathing channel and serves only to keep the tongue away from the posterior pharyngeal wall.

The airway has been used not only during and after anesthesia but also to facilitate expired-air resuscitation.



### CASE REPORT

#### Fire with Nonflammable Anesthetic Agents

Dr. Frank W. Summers of the Los Angeles County Hospital submits the following interesting case report.

A 41 year old woman was undergoing craniotomy for removal of an intracranial neoplasm. Endotracheal anesthesia with nitrous oxide 6 liters, oxygen 2 liters and intermittent doses of meperidine were used throughout the entire procedure.

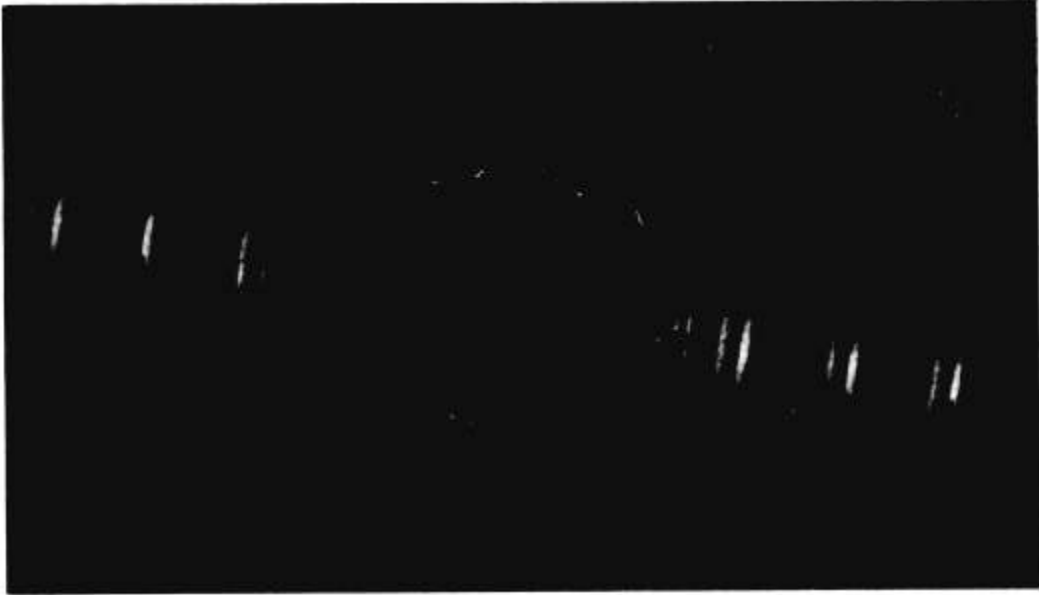Satisfactory and uneventful anesthesia had continued for approximately 2½ hours when there was an urgent call that a fire and explosion had occurred in the neurosurgical operating room. The smell of burning rubber was evident. The resident reported that a brilliant yellowish-white flame had burst forth under the surgical drapes. This was followed shortly by a muffled, dull explosion report. The anesthesia rebreathing tube was noted to be on fire and was quickly extinguished.

The patient's vital signs remained stable. It was impossible to terminate the surgery at the advanced stage that had been reached.

It was elected to continue anesthesia and surgery.

The cause of the fire and explosion was not immediately evident. A careful check of the anesthesia and equipment showed that no ether or other flammable volatile agents were present. Cyclopropane had been turned off at the cylinder yoke and there was no leak. Nitrous oxide-oxygen and meperidine were the only anesthetic agents used during the 2½ hour period. Wet towel intercoupling to conductive flooring was used for anesthesia machine, operating table and patient. No ether or alcohol had been used in surgical scrub preparation of the patient's skin, and the drapes were dry.

A more careful investigation revealed the following sequence of events. The tumor was bleeding profusely. The neurosurgeon requested a second high-frequency electrocautery probe to be used by his assistant. At intervals the assistant would place his cautery probe on top of the Raney instrument stand.



When the surgeon used electrocautery, the high frequency current was carried to the second probe and readily jumped through the two layers of sheet covering the instrument stand. The high frequency current arced from the Raney stand to the best electrical pathway to ground—the conductive breathing tube. The breathing tube made only slight contact at one point with the instrument stand, or was separated by a fraction of an inch of air space.

Further investigation revealed that the Raney stand was an old one recently pressed into service. The legs were painted and non-conductive and the casters were nonconductive. It did not bear the usual weekly color tape denoting conductivity safety check by the hospital's electrical department.

The fire caused black carbonaceous smoke to accumulate in the breathing tube. The mixture of smoke with nitrous oxide and oxygen caused the weak explosive report that followed the fire. Most of the explosive force exited through the hole burned in the tubing. Examination of the rebreathing tube revealed the inside of the tube coated with black soot throughout its length and a hole approximately 3 by 4 cm. with sticky burned rubber at the edges.

Endotracheal suction of the patient brought forth particles of black soot from the tracheo-bronchial tree. Postoperatively there was no clinical or roentgenographic evidence of damage to the lungs. The patient made an uneventful recovery.

---

## **CORRESPONDENCE**

### **Correction**

*To the Editor:* In my article, "Estimation of Blood loss in the Operating Room," Current Comment, March–April 1961 Issue, page 318, an error appeared. Beginning on line 18, second column, "However, these errors are just as likely to cancel each other." This statement

should be, "However, these values are just as likely to be in the same direction as to cancel each other."

ROBERT W. VIRTUE, M.D.  
*Professor of Anesthesiology  
University of Colorado Medical Center*