

# ELECTRONARCOSIS BY COMBINATION OF DIRECT AND ALTERNATING CURRENT

## 2. Effects on Dog Brain as shown by EEG and Microscopic Study

R. H. SMITH, M.D., Z. W. GRAMLING, M.D., G. W. SMITH, M.D., P. P. VOLPITTO, M.D.

PREVIOUSLY we reported the achievement of states of unconsciousness and total analgesia in dogs by the passage through the brain of a combination of direct and alternating currents.<sup>1</sup> Since that report was made, an additional 40 dogs have been subjected to electronarcosis. All but two of this group were successfully anesthetized. Convulsions occurred in the two animals in whom anesthesia was not obtained. One of these dogs convulsed secondary to an error in the application of the electrical current. The second animal convulsed each of the eight times in which electronarcosis was attempted. The remainder of the group, comprising 38 dogs, did not convulse nor did they show obvious hypoventilation, disabling cardiac arrhythmias, or behavioral changes during or following the application of the electrical current. In part of this group of dogs the present study was carried out to determine the effects of this method of electronarcosis on the dog's brain as evidenced by electroencephalographic (EEG) pattern and histologic sections.

### METHOD

Twenty-three unpremedicated mongrel dogs, varying in weight from 12 to 30 kg., were subjected to electronarcosis a total of forty times for periods of varying duration. The analysis of the periods is in table 1. Each dog, under local anesthesia with 1 per cent lidocaine, had shielded EEG (fig. 1) screw electrodes set in the outer table of its skull 1 cm. each side of the midline, halfway between the inion and the supra-orbital ridge. The electrodes were no. 4, 5/8-inch brass flathead screws set 1-1 1/2 turns into a drill hole in the outer skull table. Maximum sensitivity of the EEG machine

Accepted for publication July 18, 1961. The authors are in the Department of Anesthesiology, and the Division of Neurological Surgery, Medical College of Georgia, Augusta, Georgia.

without muscle activity interference was obtained by shielding the screws with plastic tubing. Only two EEG leads were used in this study because of the need for space on the dog's head for effective placement of the electronarcosis electrodes.

After the EEG electrodes were placed, an awake, baseline EEG recording was made, and the screw electrodes were removed. The dog was then subjected to electronarcosis for periods of time varying from one to six hours.

Our technique described elsewhere<sup>1</sup> of producing electronarcosis in the dog has been modified in some details. The electrode construction, location of the electrodes, amount of current employed, pattern of current application, and impulse duration have been altered.

The solid metal and metal-mesh electrodes recommended in the first report, in some cases produced local third-degree burns which were deep and serious. The burns were overlooked because the dogs were only observed for twelve hours. The burn problem was largely solved by using silver electrodes covered with cellulose sponge (fig. 2). The electrodes were saturated with a strong sodium chloride

TABLE 1

NUMBER OF TIMES AND LENGTH OF TIME ELECTRONARCOSIS WAS PRODUCED IN EACH DOG

6 hours once	2 dogs
4 hours once	2 dogs
2 hours once	2 dogs
1 hour once	5 dogs
1 hour twice	4 dogs
1 hour three times	3 dogs
1 hour twice, and 6 hours once	2 dogs
1 hour once, and 6 hours once	2 dogs
2 hours twice	1 dog

solution, and required that 0.5 ml. of the solution be injected into the sponge every fifteen minutes to maintain conduction efficiency.

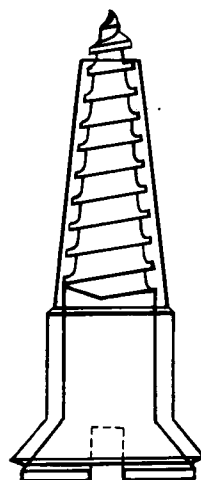
Electrode placement was found to be a critical factor in airway control. If the occipital electrode were placed caudad to the neck-muscle attachment to the inion, these muscles contracted under local electrical stimulation, shortening the neck and obstructing the airway. It was necessary at times to intubate the dog's trachea because of this problem of electrode placement. (It was easy to do this under electronarcosis and "bucking" on the tube did not occur.) However, when the occipital electrode was moved anteriorly, and placed on the vertex of the skull, leaving the nasal electrode in its usual place just below or between the eyes (fig. 3), the animal could not be anesthetized. An examination of figure 3 shows why this failure occurred; the current was not passing through the brain. ~~The current flow through the brain was~~ achieved by placing the "nasal" electrode in the roof of the dog's mouth. This rearrangement of electrodes permitted electronarcosis to be produced without any increase in current requirements over the method we previously employed, *i.e.*, with the electrodes placed behind the inion and on the nose.

Our first generator had a maximum output potential of 20 milliamperes D.C. and 20 milliamperes A.C., and it was found that some dogs could not be anesthetized with this output of current. The generators employed in this study have an output potential of 50 milliamperes D.C. and 50 milliamperes A.C. Most of the dogs we studied required 20 milliamperes D.C. and less than 30 milliamperes A.C., although one required 42 milliamperes A.C.

The pattern of current application was modified from the original pattern. Less excitement attended the current application if 20 milliamperes of direct current were applied quickly first and the alternating current was applied thereafter. 20 milliamperes of alternating current could be applied in six minutes if the input were delivered smoothly, without current surges.

A square wave of 2 milliseconds' duration was used in this study. This wave duration produced a smoother induction than the

FIG. 1. No. 4, 5/8-inch brass screw shielded with 14F and 10F plastic tubing.



one-millisecond wave which we described previously.

When the electronarcosis was ended, the screw electrodes were replaced and serial EEG tracings recorded until the tracing was clearly established as being comparable to the "awake" baseline record. The first tracing was obtained in from four to twenty minutes, depending on circumstances.

The dogs were observed for periods varying from twelve hours to two weeks after their last electronarcosis, and then sacrificed for brain examination. The brains were fixed in 10 per cent buffered formalin and routine hematoxylin-eosin stains were performed. Representative sections were taken through the cortex, basal ganglia, brain stem, pons, cerebellum and medulla.

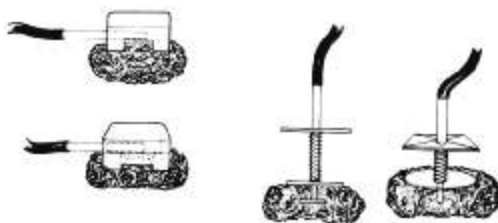


FIG. 2. Each type of electrode is a silver disc with a copper rod silver-soldered to it, and covered with a plastic rod silver-soldered to it, and covered with strong saline solution. The electrodes on the right are so constructed as to be held on the vertex of the skull by a hood. Those on the left are to be set into the roof of the mouth and tied in place with a thin cord.

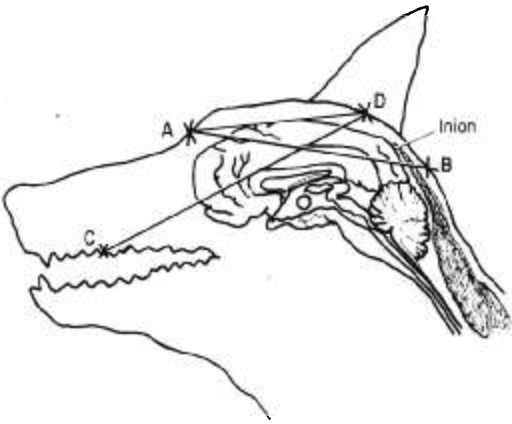


FIG. 3. Drawing from a sagittal section through a dog's head, showing the relationship between the current pathways and brain mass. The current paths, A-B and C-D, pass through sufficient brain mass for the production of electronarcosis. The current pathway A-D, extending from the vertex to the nose, fails in the production of electronarcosis; there is no brain mass between the electrodes.

### RESULTS

**Electroencephalogram.** Compared with the awake pattern, the immediate post-electronarcosis EEG showed a temporary but consistent change in amplitude and frequency. There was a decrease in amplitude which averaged 20 per cent. The frequency which normally averaged 28 waves per second increased to an average of 34 waves per second. These changes generally reverted to normal within a few minutes. In every instance the post-electronarcosis EEG pattern returned to normal within 30 minutes.

**Brain Histology.** Eight brains were selected at random for histo-pathological study. Dr. Hans Peters, the neuropathologist at the Medical College of Georgia, interpreted these sections as showing no neuronal change other than agonal swelling, without areas of hemorrhage or necrosis. One brain showed a meningitis secondary to injury and contamination of the meninges at the time of placing the screw electrodes in the skull. One section showed a small midbrain perivascular inflammatory reaction as evidenced by lymphocytic infiltration. However, this was believed not to be attributable to the passage of the electric current, but rather a reflection of a long-standing inflammatory process often seen in mongrel dog brains.

### DISCUSSION

The findings of normal, post-electronarcosis EEG patterns were not entirely expected, because these dogs showed a 1 degree centigrade rise in body temperature in the course of as little as one hour of electronarcosis. This hyperthermia was in the same range as the rise in temperature reported as a constant by Anan'ev.<sup>2</sup> However, despite the temperature rise, which we have assumed to be consequent to a temporary derangement of the heat regulating center, the EEG pattern in the post-electronarcosis periods of our animals did not show evidence of brain injury.

The fact that the rise in body temperature rarely exceeded 1 degree centigrade is of interest. In most instances the dog's temperature rise resulted in panting, which is a successful method of heat dissipation in the dog, provided air is moved over the tongue. (The dog's tongue contains a large A-V shunt, and the air movement cools the blood passing through this shunt.<sup>3</sup>) One of the dogs in this study developed severe hyperpyrexia (42.5 C. rectal temperature) which we attributed to heat retention. In this case the posterior electrode was behind the inion, and neck muscle retraction resulted from stimulation by the applied current. This neck shortening produced airway obstruction which was corrected by the use of a no. 40 endotracheal tube placed in the pharynx. The hyperpyrexia persisted until the animal was allowed to awaken from electronarcosis and the pharyngeal airway was removed. This maneuver apparently allowed the dog's panting-cooling mechanism to become effective because the rectal temperature fell from 42.5 C. to 40.5 C. in 35 minutes and to 39.8 C. in one hour.

We found that whenever an artificial airway was required, excessive body heat could be dissipated easily by pulling the dog's tongue forward with a ring forceps until the anterior one-half was exposed outside the mouth, and then subjecting the tongue to a constant trickle of cold tap water.

As stated we have failed to produce electronarcosis by our present methods in two dogs. One of these dogs, a pregnant female, was the victim of an error wherein a sudden surge of high amperage was applied, resulting in a

grand mal seizure. The other, a 20-kg. Dalmatian female, has been subjected to electronarcosis eight different times, and has convulsed every time. She has had applied frequencies of 60, 75, 100, and 125 cps., and wave durations of 1, 1.5, 2, 2.5 and 3 milliseconds. We have produced delay in pain perception, but not electronarcosis, in this animal. One other animal, a 12-kg. male, required three separate attempts before electronarcosis was produced. The first two attempts were abandoned because convulsions appeared imminent. However, this dog was successfully anesthetized on the third attempt by employing 35 milliamperes of direct current and 42 milliamperes of alternating current.

Efforts are being made to develop a method of taking EEG tracings during electronarcosis, but the wave input frequency being employed is so nearly the frequency of the EEG waves that separation has been found to be difficult. ~~This, plus the fact that EEG wave magnitude~~ is in order of microvolts while the input is in volts, has, to date, made EEG tracings impossible to record during this type of electronarcosis.

#### SUMMARY

Twenty-three dogs were subjected to electronarcosis a total of forty times for periods varying in length from one to six hours. When the awake, pre-electronarcosis EEG tracing was used for comparison, none of these dogs showed EEG evidence of brain injury. The microscopic examination of eight brains revealed no lesions which could be attributed to the passage of the electric current.

This work was supported in part by a grant from the Ohio Chemical & Surgical Company and by a grant from the Medical Research Foundation of Georgia.

#### REFERENCES

1. Smith, R. H., Goodwin, C., Fowler, E., Smith, G. W., and Volpitto, P. P.: Electronarcosis produced by combination of direct and alternating current. Preliminary study, *ANESTHESIOLOGY* 22: 163, 1961.
2. Anan'ev, M. G., Golubeva, I. W., Gurova, E. V., Kashevskaja, L. A., Levitskaia, L. A., and Khudyi, Yu.B.: Preliminary data on experimental surgical apparatus and instruments, *Eksp. Khir.* 4: 3, 1957; translated in *ANESTHESIOLOGY* 21: 215, 1960.
3. Miller, M. E.: Guide to the Dissection of the Dog, ed. 2. Ann Arbor, Michigan, Edwards Bros., Inc., p. 340.

**GASTRIC INTUBATION** The insertion of a tube into the gastrointestinal tract is often a valuable therapeutic measure. Complications may result, however, and these are classified anatomically: nasopharyngeal—pressure necrosis of the tip of the nose, nasal hemorrhage, rhinitis, conjunctivitis, sinusitis, pharyngitis, and symptoms related to the ear; laryngotracheal—laryngitis, laryngotracheitis; pulmonary—aspiration pneumonia and asphyxia, respiratory obstruction. Complications within the esophagus, stomach and bowel may result from laceration or perforation. The complications in the air passageways may be wrongly at-

tributed to endotracheal intubation. (*Hafner, C. D., Wylie, J. H., Jr., and Brush, B. E.: Complications of Gastrointestinal Intubation, A. M. A. Arch. Surg.* 83: 163 (July) 1961.)

**THIAZIDE DIURETICS** Intensive or prolonged administration of thiazide diuretics may produce hypokalemia. This sensitizes the myocardium to digitalis and may lead to a fatal cardiac arrhythmia in a digitalized patient. (*Ebner, H., and Burton, B. H.: Maternal Mortality from Hydrochlorothiazide-induced Digitalis Intoxication, Obstet. Gynec.* 17: 6 (June) 1961.)