

Experimental Study of Intrathecal Detergents

Robert A. Smith, M.D., and Eugene H. Conner, M.D.

CONTAMINATION of anesthetic agents by surface active compounds, such as detergents, has been implicated as a possible etiologic factor in the untoward neurologic complications occasionally observed following spinal anesthesia.^{1, 2}

This suggestion was first made by Winkelman¹ in 1952 in a report of 11 patients with varying degrees of neurologic deficit which developed following spinal anesthesia. He suggested that syringes washed in a mild detergent solution, inadequately rinsed in tap water before autoclaving, retained sufficient detergent to act as an irritant to the cellular elements of the neuraxis when used for the administration of the anesthetic agents.

Alpers and Paddison² suggested that such neural irritation might be the result of synergistic action between the spinal anesthetic agents and small quantities of retained detergent.

Courville, discussing contaminating detergents as a possible cause of meningeal involvement, stated "This aspect of the problem is in need of further critical evaluation by experimentation."³

There have been three reports of laboratory studies^{4, 5, 6} in which surface active agents have been directly injected into the subarachnoid space.

Hurst,⁴ using rhesus monkeys, removed 1 ml. of cerebrospinal fluid from the cisterna magna and injected 1 ml. of known concentrations of various detergents, antiseptics, phenol and horse serum. The strength of the

detergent solutions recommended for use in cleaning equipment or for chemical sterilization was not identified. He demonstrated that in sufficient concentration intracisternal injection of these substances produced one or combinations of three types of response: (1) superficial damage to nervous tissue exposed to the direct action of the chemicals; (2) cellular proliferation and fibrous thickening of the pia-arachnoid with adherence of the meninges, and (3) necrosis of the media, and often the adventitia of the meningeal arteries resulting in obstruction of their lumen and consequent restriction of the blood supply to the nervous tissues.

Denson *et al.*⁵ and Joseph and Denson⁶ demonstrated experimentally that spinal anesthesia (tetracaine-glucose) administered from syringes and needles contaminated with unknown quantities of detergent solutions consisting only of tribasic sodium phosphate (TSP) produced arachnoiditis in monkeys. Pathologic changes were observed only in those instances in which the strongest TSP solution (5 per cent) had been used as the contaminant. This concentration of TSP is probably stronger than would be obtainable with commercial detergent preparations if reasonable care were exercised in their use.

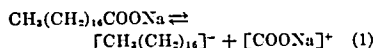
Chemistry

Biological activities of detergents have been briefly cited by Paddison and Alpers² but the chemical nature of this important group of compounds has not previously been given in conjunction with discussions of the possible role of detergents as etiologic agents in post-spinal anesthetic sequela. Morris⁷ presented a brief review of the chemistry of wetting agents, and the following comments have been prepared from this source.

WITH THE TECHNICAL ASSISTANCE OF DOROTHY P. ANDERSON. The article was received from the Department of Surgery, Section on Anesthesiology and Surgical Research Laboratory, University of Louisville School of Medicine, Louisville, Kentucky, and accepted for publication August 1, 1961. Dr. Smith's present address: Harbor General Hospital, Torrance, California.

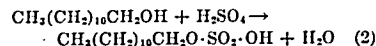
Detergents are fundamentally of three types: anionic, cationic and nonionic, grouped in this fashion in accordance with the sign of the charge on the major portion of the molecule.

Soaps are, in effect, anionic detergents for they are the strong alkali salts of fatty acids, which in solution ionize into two fractions. An example of such a soap is sodium stearate: $\text{CH}_3(\text{CH}_2)_{10}\text{COONa}$ which ionizes in solution:

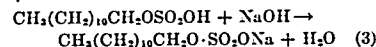


$[\text{CH}_3(\text{CH}_2)_{10}]$ is the hydrophobic, lipophilic, nonpolar and negatively charged portion and $[\text{COONa}]$ is the hydrophilic, lipophobic, polar and positively charged portion. Soaps act best in an alkaline media (pH 10.2). Below this they do not ionize and remain in an insoluble fatty acid form.

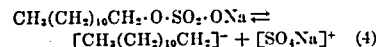
Anionic detergents, like the soaps, have one or more of the polar (hydrophilic) and nonpolar (hydrophobic) groups. Fatty alcohol sulfates are generic examples. Lauryl alcohol when treated with sulfuric acid forms lauryl sulfate:



This process is called sulfonation. The sulfonated alcohol is further treated with NaOH:



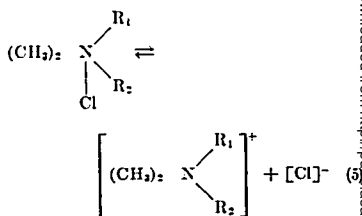
In an alkaline medium ionization occurs:



The $[\text{SO}_4\text{Na}]^+$, equation (4), is similar to the $[\text{COONa}]^+$, equation (1), except that the former is more hydrophilic. The remainder of the molecule of this representative anionic detergent $[\text{CH}_2(\text{CH}_2)_{10}\text{CH}_2]$ is similar to the hydrophobic group of soaps in equation (1). Sulfonates are stable at a lower pH (7.0) than soaps.

A second major chemical class is the cationic detergent or reverse soap. The quaternary ammonium derivatives are representative:

The quaternary ammonium derivatives are representative:



where R_1 and R_2 may be alkyl, or aryl groups of varying molecular weight. In this detergent the chlorine ion is the polar, hydrophilic, negatively charged portion of the molecule, and the remainder is the hydrophobic, positively charged part which produces the cationic effect at the oil-water interface. Cationic detergents can not form salts with heavy metals. In contrast to conventional soaps and anionic detergents, the cationic detergents work best at acid or neutral pH. This type of detergent has its most widespread application as cold sterilizing agents or antiseptic solutions. Benzalkonium chloride (*vide infra*) is a typical example of this class of compounds.

The third type of detergent is known as nonionic, *i.e.*, it has no charge on either the hydrophilic or the hydrophobic portion of the molecule.

Nearly all commercial detergent preparations are combinations of a number of chemical compounds: detergents, fatty alcohol sulfonates; sequestering agents, tri-sodium bi-sodium phosphates, sulfates or silicates; and "inert" fillers. Even the cationic detergents that are employed as antiseptics or cold sterilizing agents, such as the quaternary ammonium compounds, are mixtures of as many as a dozen different dimethyl, or diethyl, or alkyl ammonium salts in varying proportions.

Assessment of the biological effect of such mixtures is difficult, but since we wished to determine minimum concentrations and quantities of detergents commonly in hospital use that would be injurious to the spinal cord and its vestments, we made no effort to separate the components.

Methods

The animals used were full-grown, female mongrel dogs, weighing between 14 and 20 kg., adjudged clinically free of neurological deficits. All animals were anesthetized by the intravenous injection of pentobarbital (25-30 mg./kg. body weight). Surgical exposure of a midlumbar interlaminar space by removal of a portion of the spinous processes and lamina was performed under aseptic conditions. Under direct vision, subarachnoid injection with a 27 or 30 gauge needle was accomplished. Following aspiration and discard of 0.25 ml. of cerebrospinal fluid, 0.25 ml. of known concentrations of detergent solutions was injected from a 1.0 ml. tuberculin syringe. Each animal received only a single injection of one of three commercially available preparations. After placing a McKenzie silver clip as a marker in the muscle adjacent to the injection site, the wound was closed in layers.

All animals received intramuscular procaine crystalline penicillin G, 400,000 units, and dihydrostreptomycin sulfate, 0.5 Gm. prophylactically on the day of operation. Three animals developed collections of serum in their operative wounds. Following aspiration of the serum collections, these animals received, on successive days, two additional doses of the antibiotic combination. There were no gross wound infections.

Animals were isolated in separate runs until the skin sutures were removed and the wounds had completely healed. They were then kept in small groups in runs for periods up to one year following injection.

The detergents selected for intrathecal injection are those employed in hospitals for cleaning needles and syringes or for the preparation of the skin prior to the administration of spinal anesthesia.

Seven animals received concentrations of aqueous benzalkonium chloride (Zephiran*) ranging from 1:8 to 1:2,000. Dilution 1:8 is the stock solution from which the recommended and commonly employed 1:1,000 concentration is prepared. This is a cationic detergent.

* Zephiran (Winthrop Laboratories), benzalkonium chloride is a mixture of alkyl dimethylbenzyl ammonium chlorides. Alkyls of $C_{12}H_{25}$ to $C_{18}H_{37}$. pH 6.58 at 25° C., 1:1,000 solution.

Four animals received B-D Yale Cleaner,† an anionic detergent, in concentrations 4, 2, 1 and 0.5 times as strong as recommended by the manufacturer for cleaning purposes.

Three other animals received Alconox‡ in concentrations equivalent to 2, 1 and 0.5 times that recommended by the manufacturer for use in washing syringes and needles. This is also an anionic detergent.

Neither local anesthetics nor other chemical agents were injected in combination with the detergent solutions. Concentration and total quantity of the detergent mixtures introduced are shown in table 1.

Animals were sacrificed by administering an overdose of pentobarbital. Spinal cords, with dura intact, were removed from the level of the foramen magnum to the tip of the dural sac. Specimens were fixed in buffered 4 per cent formalin for one week. Representative tissue blocks were obtained from the region of the site of injection, the lumbar enlargement, the conus, the mid dorsal region and the cervical enlargement.

Sections from each tissue block were stained using hematoxylin and eosin,⁸ Luxol fast blue-PAS⁹ and Gomori trichrome.¹⁰

Histopathologic changes were graded as: (0), no change from normal; (±), equivocal; (1+), minimal, could be unrelated to experiment or may be seen as 'physiologic' change in older dogs; (2+), moderate; (3+), marked. Clinical findings graded as: (0), no change; (±), equivocal; (1+), minimal; (2+), moderate; (3+), severe.

Results

Results are summarized in table 1.

The most prevalent response was reaction of the mesodermal elements: fibrous tissue proliferation of dura alone (fig. 1) or of the pia-arachnoid with incarceration of the sub-arachnoid vessels (fig. 2). This was generally limited to the site of injection, in the dorsal or dorso-lateral regions (dogs: 1, 112, 504, 507, 512) except in one instance (7) in which

† B-D Yale Cleaner (Becton, Dickinson & Co.) is a mixture consisting of an alkylaryl sulfonate and fatty amide base plus alcohol, water and stabilizer. Neutral.

‡ Alconox (Alconox, Inc.) is a mixture of hydrocarbon sulfonates, fatty alcohol sulfates, and highly complex phosphates. pH 8.8-9.0.

her hind legs but could get up, wag her tail and was not incontinent of urine or feces. Seven days after procedure, the dog's hind legs were still stiff but she moved about without difficulty. There was some accumulation of serum in the wound and aspiration was performed twice. No wound infection developed. By the ninth postoperative day, gait was normal and neither motor nor sensory deficit

nor incoordination were detected. Clinical recovery was complete, and no recurrence of symptoms was manifest during the 11 months and 22 days that the animal was observed. Histological examination revealed collagenous proliferation and incomplete demyelination at the injection site with astrogliosis in the posterior columns (fig. 4). This reaction was not noted in sections above and below the in-

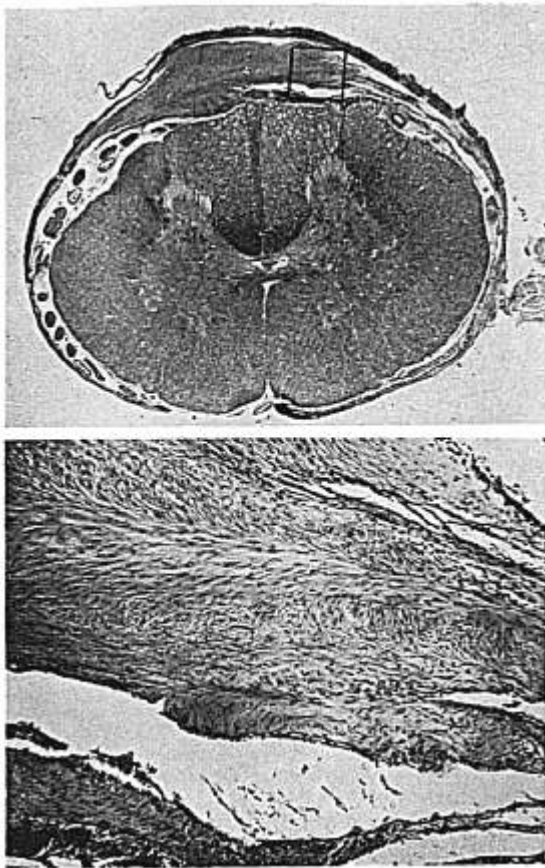


FIG. 1. *Above:* Lumbar cord (dog 112) 4 cm. caudad of injection site showing proliferation of dura and arachnoid (Luxol fast blue-PAS, from approximately $10\times$). *Below:* Enlarged section outlined above showing fibrous proliferation of leptomeninges (Luxol fast blue-PAS, from approximately $40\times$).

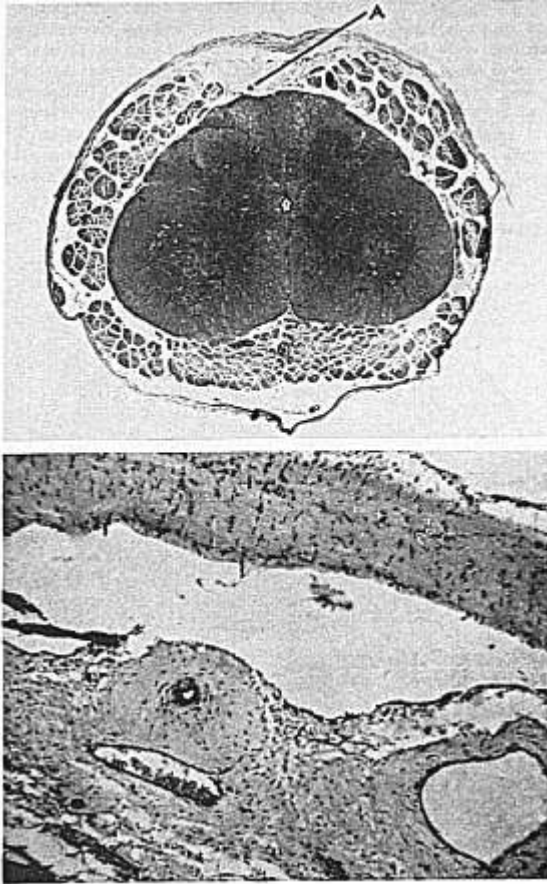


FIG. 2. Above: Distal lumbar cord (dog 110) at site of injection showing fibrotic plaque in subarachnoid space with incarceration of dorsal spinal vessels (trichrome from approximately 10 \times). Below: Section from region A above showing fibrous proliferation of pia-arachnoid trapping of vessels, and proliferation of media of dorsal spinal artery (H and E, from approximately 40 \times).

jection site indicating that the lesion was well localized. The block taken from the injection site was 1.5 cm. in length. This lesion in the posterior columns could account for loss of position sense evidenced by the inability to scratch with the hind legs for the first 9 days following injection.

A section of lumbar cord from a normal

control animal is shown for comparison (fig. 5).

Discussion

The concentrations of detergents that produced clinical or histopathological changes in dogs as herein reported were far in excess of the concentration or quantity of these

chemicals that would be likely to be present in chemically contaminated anesthesia equipment.

Pathological responses observed were manifest primarily in tissues of mesodermal origin; the meninges and blood vessels.

This proliferative meningeal response has been reported in previous laboratory studies, cited above, in which monkeys (rhesus and

Javanese Macaque) were used and by Davis *et al.*¹¹ following the use of various preparations of procaine in the dog. Similar pathological lesions have been reported in man in the few clinical cases of "arachnoiditis" that have been studied adequately at autopsy.^{1,2,12,16} According to McGrath,¹⁷ focal pachymeningitis seen in the dog is frequently the result of trauma. The remote lesions observed

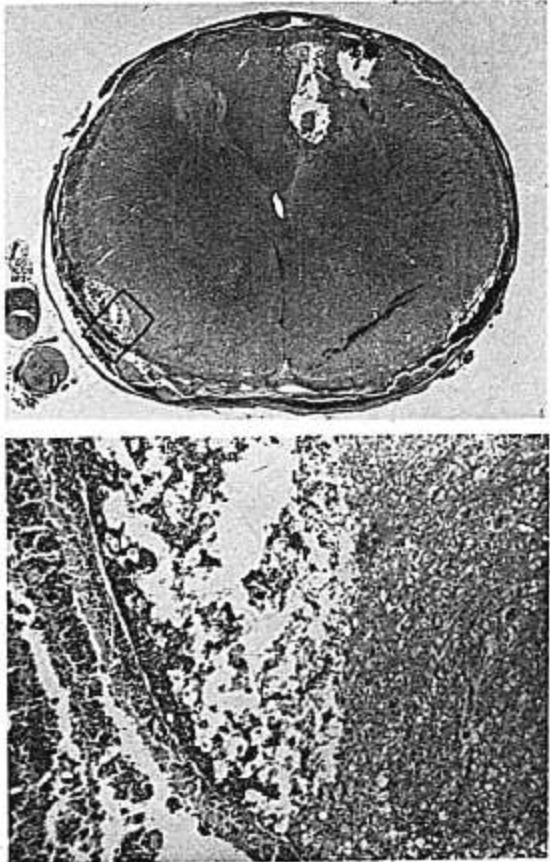


FIG. 3. Above: Lumbar cord (dog 500) at injection site showing three distinct areas of necrosis of cord substance (H and E, from approximately 10 \times). Below: Enlarged section as outlined above showing necrosis in white matter of cord, and menigitis (H and E, from approximately 40 \times).

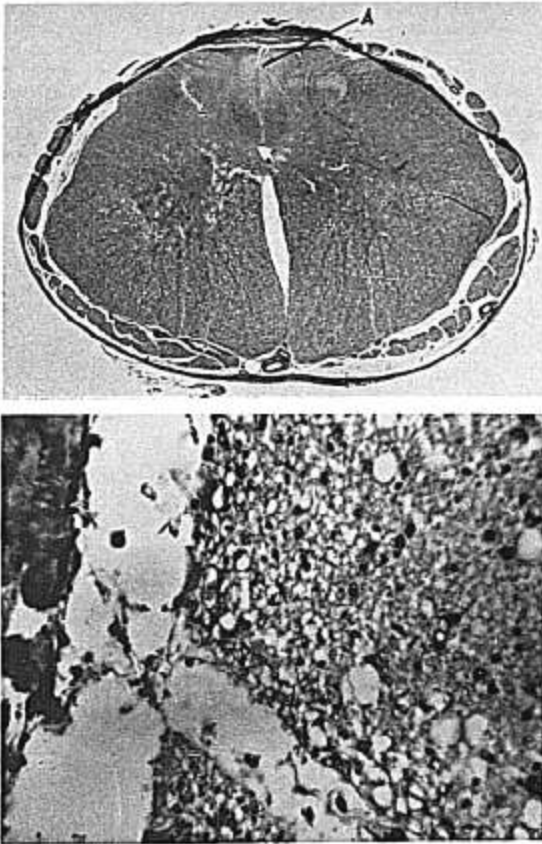


FIG. 4. Above: Lumbar cord (dog 31) at site of injection showing demyelination of posterior column (Luxol fast blue-PAS, from approximately $10\times$). Below: Enlargement from region A above showing demyelination and astroglia. The oval nuclei of astrocytes are visible in the demyelinated area of the field to the right of the capillaries (Luxol fast blue-PAS, from approximately $100\times$).

in dogs 110 and 10 could have been present prior to the study, since the histopathological lesions were minimal and no clinical deficit was detected.

Pathological changes in blood vessels were limited to arteries in the subarachnoid space. Alterations of the media with fibrous tissue proliferation and consequent narrowing of the vessel was observed. These changes were observed in animals that had received anionic

detergents. Similar lesions involving the small arteries have been reported in previous laboratory studies^{4,6} and one clinical case.¹²

As might be anticipated, there is a correlation between the concentration of the detergent solution injected, the neurological symptoms, and the histopathological findings. Generally, the more concentrated solution evoked a more severe tissue response.

There was, however, one exception. Animals

receiving the anionic detergent, B-D Yale Cleaner, showed minimal histopathological change in response to the most dilute solution injected, no response at double this concentration, and evidence of minimal histological change at a concentration four times the most dilute solution. Since only 3 animals received this detergent mixture, this limited experience precludes further interpretation.

Damage to the neural elements was observed in only 2 animals. Dog 500 in all probability had an intramedullary injection of the extremely concentrated solution of benzalkonium. This strength (1:8) will injure thickened dermis on direct contact and is ordinarily not used except in the pharmacy for the preparation of the 1:1,000 and 1:2,000 solutions which are used clinically. The other animal (31), showing a response in neural tissue, developed demyelination and astrogliosis of the posterior columns. This animal had received a solution of benzalkonium four times as concentrated as would be likely to be used clinically. None of the sections on any of the 13 animals (500, intramedullary injection, excepted) showed any evidence of involvement of the nerve roots.

Clinical manifestations of neurological deficit, when they occurred, were seen immediately following the injection of the chemical agent. Improvement was progressive in all 6 ani-

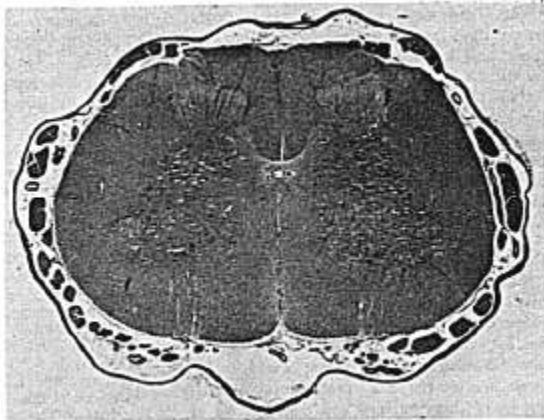
mals who manifested such deficit. Even dog 31, in whom damage to the posterior columns was demonstrated after nearly a year of observation, was completely normal clinically within nine days following the injection.

Neither a latent period of normal function followed by increasing neurologic deficit nor a progressive increase in the severity of neurologic symptoms following injection was observed in any of these animals, despite the fact that they were observed for upwards of one year, which in terms of the lifetime of man may be considered equivalent to 10-15 years. This is in sharp contrast to the usual clinical findings in the progressive neurologic disease developing following introduction of chemical irritants in primates or seen infrequently following spinal anesthesia in man.

We believe that these observations can be interpreted in view of the histopathological processes which may follow the intrathecal injection of chemical irritants. The observed response depends upon the concentration and total dose administered.

(1) If the irritant is administered in small total dose and in sufficiently low concentration, the principle response is shown by tissues of mesodermal origin. This is characterized by a proliferation of all layers of the meninges or simply the dura, and a medial necrosis of the arteries followed by fibrosis

FIG. 5. Lumbar cord section at level of a dorsal root in control dog, showing normal architecture of white and gray matter and leptomeninges of normal thickness (Luxol fast blue-PAS, from approximately 10 \times).



or hyalinization, and narrowing of the lumen of the vessel.

(2) A larger total dose or higher concentration may evoke a more severe proliferation of these vestments, either more widespread or locally (at site of injection) severe enough that eventual "strangulation" (pressure necrosis; marginal status spongiosus) of the cord structure results and neurological deficit occurs. Should the medial necrosis of the arteries and the fibrous tissue scarring be so extensive as to compromise the blood supply to the cord, cellular death of the least vigorous, most susceptible neural element would occur, and the area of damage invaded by astrocytes and other glia cells.

(3) If the irritant is introduced in sufficient strength to produce immediate cellular death to all elements, immediate extensive neurologic deficit is observed at the time of injection. As the chemical is diluted in cerebrospinal fluid, the cellular response of mesodermal and ectodermal elements varies according to the concentration of the irritant and will be apparent in the gradation of neurologic deficit up and down the neuraxis. A similar concept of the progress of this disorder has been presented by Courville.³

This suggested natural history of the response of the spinal cord and its vestments to local irritants does not include the possibility of previous sensitization to the agent or agents introduced. Etiologic factors of this nature have been suggested by numerous authors, and has been explored experimentally by Hurst.⁴

(4) The possibility of different classes of detergents producing greater or lesser effect on the cellular elements within the subarachnoid space could not be evaluated on the basis of this small series. This concept has been evaluated by Hurst⁴ in a somewhat larger series.

Summary

Anionic and cationic detergents, commonly used in hospital practice for the antiseptic preparation of the skin or for cleaning syringes, needles, and other equipment, when injected into the subarachnoid space at a mid lumbar interspace in the dog, produce proliferative lesions of the meninges and degenerative al-

terations in the media of arteries. Except in one instance, there was a positive dose-response relationship. The higher the concentration the greater the tissue response. Significant clinical and histopathologic alterations were observed to occur in response to concentrations far in excess of the concentrations of these agents that might be reasonably expected to be present by accidental contamination.

Damage to neural elements occurred only 2 of 14 animals, both of whom received benzalkonium chloride solutions (1:8 and 250 dilution), 125 times and four times the concentration recommended for use as a cold sterilizing agent or for skin antiseptics.

It is concluded that in the dog, detergent as chemical irritants, can evoke responses in tissues of both mesodermal and of ectodermal origin within the central neuraxis. In concentrations and doses that might reasonably be expected accidentally to gain access to the cerebrospinal fluid, the cellular response will be minimal, damage to the neural elements unlikely, and neurological deficit absent or undetected.

A preliminary report of this work was presented at the meeting of Kentucky Society of Anesthesiologists, Louisville, Kentucky, September 20, 1960. The investigation was supported by National Institutes of Health, Grant H-5349.

We are indebted to Helena E. Riggs, M.D., Chief, Laboratory of Neuropathology, Philadelphia General Hospital, for review of the pathological specimens.

References

1. Winkleman, N. W.: Neurologic symptoms following accidental intraspinal detergent injection. *Neurology* 2: 284, 1952.
2. Alpers, B. J., and Paddison, R. M.: Role of intrathecal detergents in pathogenesis of adhesive arachnoiditis. A. M. A. *Arch. Neurol. Psychiat.* 71: 87, 1954.
3. Courville, C. B.: Untoward effects of spinal anesthesia on spinal cord and its vestments. *Anesth. Analg.* 34: 313, 1955.
4. Hurst, E. W.: Adhesive arachnoiditis and vascular blockage caused by detergents and other chemical irritants: experimental study. *J. Path. Bact.* 70: 167, 1955.
5. Denson, J. S., Joseph, S. I., Koons, R. A., Murry, W. E., and Bissonnette, H. W.: Effects of detergents intrathecally. *ANESTHESIOLOGY* 18: 143, 1957.

6. Joseph, S. L., and Denson, J. S.: Spinal anesthesia, arachnoiditis, and paraplegia, *J. A. M. A.* 168: 1330, 1958.
7. Morris, G. E.: Chemistry of wetting agents, *J. Industr. Hyg. Toxicol.* 26: 175, 1944.
8. Manual of Histologic and Special Staining Techniques: Washington, D. C., Armed Forces Institute of Pathology, 1957, pp. 32-33.
9. Margolis, G., and Pickett, J. P.: New applications of Luxol fast blue myelin stain, *Lab. Invest.* 5: 459, 1958.
10. Comori, G.: Rapid one-step trichrome stain, *Amer. J. Clin. Path.* 20: 661, 1950.
11. Davis, L., Haven, H., Givens, J. H., and Emmett, J.: Effects of spinal anesthetics on spinal cord and its membranes, *J. A. M. A.* 97: 1781, 1931.
12. Russell, D.: (Pathological Report) Discussion on neurological sequelae of spinal anesthesia, *Proc. Roy. Soc. Med.* 30: 1025, 1937.
13. Kamman, G. R., and Baker, A. B.: Damage to spinal cord and meninges following spinal anesthesia—clinico-pathological study, *Minnesota Med.* 26: 786, 1943.
14. Woods, W. W., and Franklin, R. G.: Progressive adhesive arachnoiditis following spinal anesthesia, *Calif. Med.* 75: 196, 1951.
15. Bergner, R. P., Roseman, E., Johnson, H., and Smith, W. R.: Severe neurologic complications following spinal anesthesia: report of 6 cases, *ANESTHESIOLOGY* 12: 717, 1951.
16. Greenfield, J. G., Rickards, A. G., and Manning, C. B.: Pathology of paraplegia occurring as delayed sequelae of spinal anaesthesia, with special reference to vascular changes, *J. Path. Bact.* 69: 95, 1955.
17. McGrath, J. T.: Neurologic Examination of the Dog with Clinicopathologic Observations, ed. 2. Philadelphia, Lea & Febiger, 1960, p. 236.

SADDLE BLOCK ANESTHESIA Saddle block anesthesia for deliveries was given by alternating lidocaine and dibucaine in consecutive patients. Lidocaine had a more rapid onset of action and produced a greater incidence of adequate results. (Peterson, W. F.: *Lidocaine or Dibucaine for Saddle Block Anesthesia—An Analysis*, *Amer. J. Obstet. Gynec.* 81: 1249 (June) 1961.)

PARACERVICAL BLOCK This block is especially useful for relieving the pain of the first stage of labor and is recommended for cervical dystocia associated with left occipital posterior presentations. Paracervical block may be used when there is no progress in dilatation in the absence of cephalopelvic disproportion. The only side effect noted was transient fetal bradycardia. (Page, E. P., Kamm, M. L., and Chappell, C. C.: *Usefulness of Paracervical Block in Obstetrics*, *Amer. J. Obstet. Gynec.* 81: 1094 (June) 1961.)

FETAL RESPIRATIONS Obstetrical patients were sedated with alpha-prodine or meperidine in conjunction with levallorphan and were anesthetized with either halothane or chloroform. There was a definite increase in the incidence of apnea neonatorium in infants whose mothers received both analgesia and general anesthesia. The incidence of apnea neonatorium could be reduced by the use of conduction or local anesthesia and the use of levallorphan with the narcotics. (Taylor, C. R.: *Effect of Analgesia and Anesthesia on Initial Fetal Respirations*, *Amer. J. Obstet. Gynec.* 81: 1260 (June) 1961.)