

Halothane Anesthesia as a Possible Cause of Massive Hepatic Necrosis

Gerald L. Brody, M.D., and Robert B. Sweet, M.D.

HALOTHANE is becoming widely used for a great variety of surgical procedures; it has even been described by Johnstone¹ as "the universal anesthetic agent." Its low toxicity is recognized, and reports of adverse effects from its use are few. Nonetheless, as with all anesthetic agents, care must be employed in its use. Even with the greatest of precautions, complications are possible, even if rare. The following four cases, three of them fatal, implicate halothane as the causative agent in massive hepatic necrosis (acute yellow atrophy).

Case Reports

Case 1. This 70 year old woman presented with flatulence, fatty food intolerance, occasional bouts of nausea and vomiting, and right upper quadrant abdominal pain. Oral cholecystograms disclosed the presence of cholelithiasis. A 12 per cent Bromsulphalein retention was noted. In addition to chronic cholecystitis, a slight degree of arteriosclerotic heart disease and hypertension of 170/80 mm. of mercury were present. The patient was mildly diabetic and was admitted to the hospital for cholecystectomy. Immediately before the operation alkaline phosphatase level was 6.0 King-Armstrong units; total bilirubin, 0.3 mg./100 ml., one-minute direct of 0.1 mg./100 ml. The thymol turbidity level was 2.0 units. The levels of total proteins and albumin/globulin ratio were normal. Prothrombin time was 61 per cent. Cholecystectomy and an incidental biopsy of the liver were performed during halothane anesthesia.

The preanesthetic medication consisted of meperidine 75 mg. and atropine 0.4 mg. given intramuscularly 35 minutes prior to induction

of anesthesia with 200 mg. of 2 per cent thiamylal. Anesthesia was maintained with a combination of nitrous oxide, oxygen, and halothane. The system was an endotracheal semiclosed circle, carbon dioxide absorbing one, with a flow rate of 3 liters each of nitrous oxide and oxygen, and a concentration of halothane varying from 0.4 per cent to 0.8 per cent was administered through a "copper kettle" vaporizer. Six milligrams of *d*-tubocurarine were administered intravenously just prior to opening the peritoneal cavity. Assisted and controlled respirations were used throughout the operative procedure. During the induction of anesthesia the patient's blood pressure dropped from 150/80 to 110/60 mm. of mercury but returned to 140/80 mm. of mercury at the onset of the operative procedure and remained at approximately this level. The pulse rate remained between 72 and 80 beats per minute. At the conclusion of the operative procedure the patient was reacting and was returned to the recovery room in a satisfactory condition. The time of anesthesia was two hours and 50 minutes, and the anesthetic course was uneventful.

The gallbladder was the site of chronic inflammation; the liver histologically showed only minimal lipidic infiltrate (fig. 1). The patient received no blood during the operation. Her postoperative course was afebrile, uneventful, and she was discharged on the seventh postoperative day.

On the seventeenth postoperative day, the patient was readmitted in coma. She had been vomiting for five days, had been jaundiced for two days, and became comatose on the way to the hospital; on admission she responded only to pain. The abdomen was distended and there was guarding on the right side. Bowel sounds were not heard. The blood pressure was 140/70 mm. of mer-

From the Departments of Pathology and Anesthesiology, The University of Michigan, Ann Arbor, Michigan.

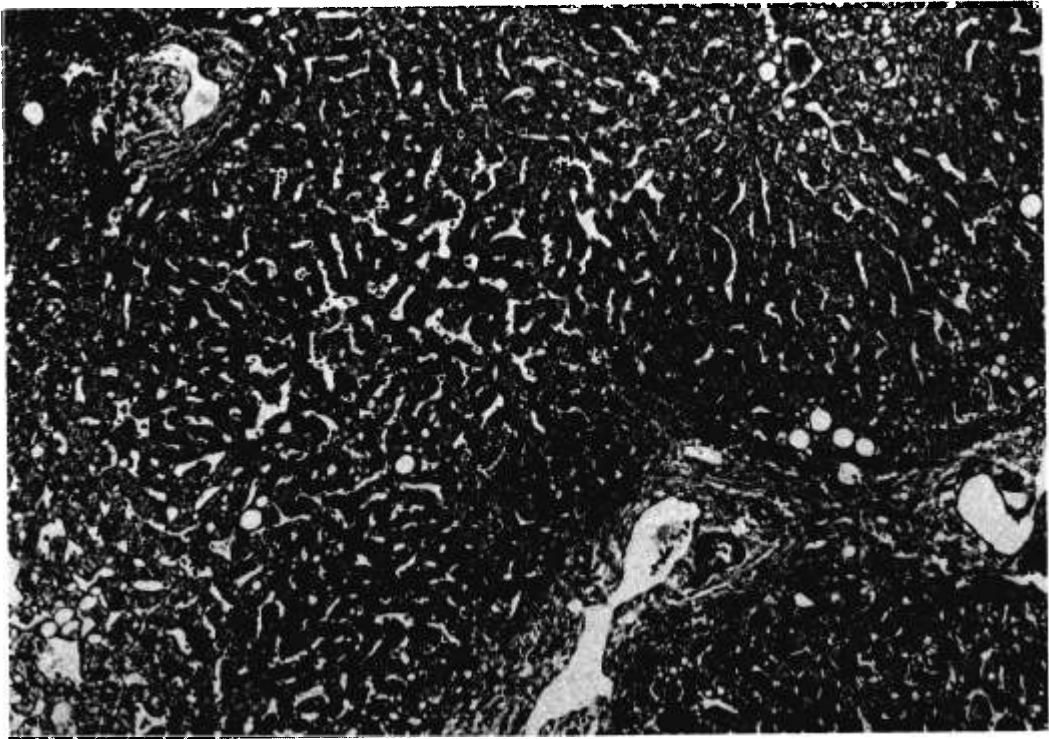


FIG. 1. *Case 1*: Liver biopsy at the time of cholecystectomy. Three hepatic triads and two central veins are shown; the latter are in the lower left and upper right hand corners. Slight degree of lipidic change is present; the amount of lipidic change is common and not significant. (Hematoxylin and eosin, from 90 \times .)

cury. The white blood cell count was 16,000/mm.³ and rose to 24,000 the next day. The alkaline phosphatase was 5.9 King-Armstrong units; the total bilirubin level, 11.8 mg./100 ml.—one-minute direct, 5.4 mg./100 ml.; and prothrombin time, less than 10 per cent. By the next day the bilirubin level had risen to 19 mg./100 ml.—one-minute direct, 9.4 mg./100 ml. The serum transaminase level was 1,100 units. Her condition deteriorated; she became hypotensive, required blood transfusions, and during the last two days of life she was oliguric. The patient expired on the twentieth postoperative day.

At necropsy the primary finding was massive hepatic necrosis. The liver weighed 600 g. and presented the typical gross appearance of acute yellow atrophy. Severe centrilobular and midzonal necrosis which had extended in many areas to involve entire hepatic lobules was present in the histologic sections. The

surviving hepatic cells at the periphery of the lobules were the site of vacuolar degeneration of the cytoplasm. Fresh hemorrhage was present in the centers of the lobules and there was abundant lipochrome pigment in reticulo-endothelial cells. The portal spaces contained leukocytes but there was no suggestion of ascending cholangitis. Hepatic endophlebitis was not seen (fig. 2). The hepatic artery was carefully dissected and was uninjured and patent throughout. In addition to the hepatic findings, there was evidence of multiple hemorrhages, including massive melena from an acute gastric ulcer.

Case 2. For 30 years this 74 year old woman had had attacks of right upper quadrant pain which had increased in frequency before hospital admission. With the attacks she had noted occasional light-colored stools and dark urine, but she denied jaundice. Between attacks she enjoyed a good appetite

and had not lost weight. Cholecystograms after bunamiodyl* disclosed gallstones. Liver function tests were normal. Cholecystectomy, common bile duct exploration, and an incidental biopsy of the liver were performed.

The preanesthetic medication consisted of pentobarbital 75 mg. and atropine 0.4 mg. administered intramuscularly one hour and 20 minutes prior to induction of anesthesia with 130 mg. of 2 per cent thiamylal intravenously. Anesthesia was maintained with a semiclosed circle, carbon dioxide absorbing, endotracheal system with nitrous oxide, oxygen, and halothane; the latter was in concentrations of 0.4 per cent to 1 per cent from a "copper kettle" vaporizer. The oxygen concentration, as determined by flow rates, varied from 33 per cent to 50 per cent with a total flow rate varying from 2 liters per minute to 8 liters per minute. During the operative procedure the

* In the form of Orablix, F. Fougere and Company, Incorporated, Hicksville, New York.

patient received 200 mg. of gallamine intravenously. Respirations were assisted or controlled. The patient's blood pressure remained relatively stable throughout the operative procedure, varying from a low of 110/60 to 150/90 mm. of mercury. The anesthetic time was three hours, and the patient's anesthetic course was believed to be satisfactory. She received no blood.

Cholelithiasis and chronic cholecystitis were found; the liver biopsy was normal (fig. 3). Postoperatively, she did very well for eight days. At this time a cholangiogram was obtained through the T-tube; no obstruction was seen. The day following the cholangiogram she began to have fever of 103° F. Coagulase positive *Staphylococcus* was isolated from the T-tube drainage, and it was believed that she had an ascending cholangitis. She was given appropriate antibiotics, but the fever continued unabated for seven days, after which time the temperature was relatively normal. However,

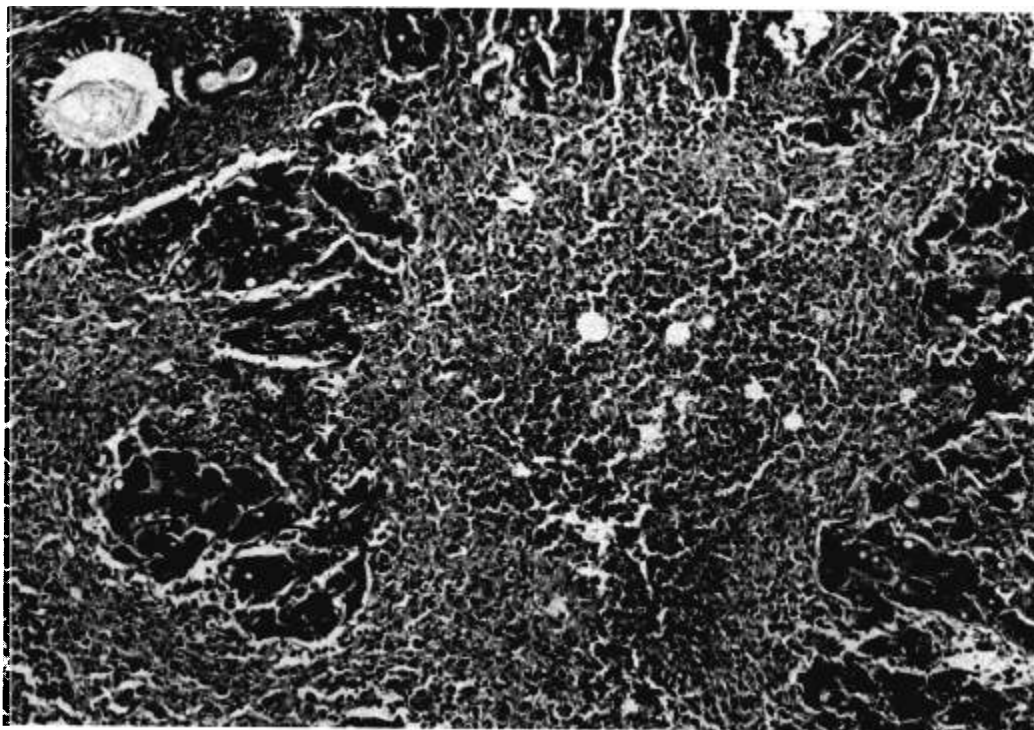


FIG. 2. Case 1: The liver at necropsy. Complete centrolobular and midzonal necrosis is present. Clumps of peripheral cells survive. The inflammatory infiltrate is minimal and there is lipidic change in the surviving cells. Otherwise the liver is indistinguishable from that of viral hepatitis. (Hematoxylin and eosin, from 90 ×.)




FIG. 3. *Case 2*: Liver biopsy at the time of cholecystectomy. The liver is normal. The vacuolated appearance of the hepatic cells is the result of glycogen content. (Hematoxylin and eosin, from 90 \times .)

in the week before death she had a fever of 101.8° F. Sixteen days before death the alkaline phosphatase level was 13.7 King-Armstrong units; total bilirubin, 32.4 mg./100 ml., one-minute direct, 14.8 mg./100 ml.; serum transaminase, 330 units; prothrombin time, 14 per cent; and cephalin flocculation, 4 plus at 48 hours. Bromsulphalein retention was 77 per cent. Two days before death alkaline phosphatase was 26 King-Armstrong units and the total bilirubin, 52 mg./100 ml. During this time her condition remained at first unchanged, but later she developed an asynchronous tremor and became comatose. The patient expired 43 days postoperatively.

At necropsy the liver weighed 780 g. and presented the usual gross appearance of massive necrosis; 2,700 ml. of cloudy, yellow ascitic fluid were present. No abscesses were found in the liver. The hepatic arteries, the portal vein, and the common bile duct were carefully examined and were found to be normal. A T-tube was in place in the common

bile duct. In many of the histologic sections no viable liver tissue could be identified; large areas of coagulation necrosis, containing many "ghost" cells, were present. In the areas where some hepatic parenchyma survived, necrosis was centrolobular and midzonal. The surviving cells were the site of lipidic change. Hepatic endophlebitis was not seen. There was slight regeneration of hepatic cells but no proliferation of bile ducts. Many bile plugs were present in distended intralobular canaliculi. The portal spaces contained only a few lymphocytes. There was no evidence of ascending cholangitis (fig. 4).

Case 3. This 63 year old man was admitted with a recurrent left retinal detachment; he had had a cataract removal four months previously and a retinal detachment imbricated one month previously; both of these procedures were carried out in another hospital. The first operation was performed with local anesthesia and was uneventful. The second operation was during thiopental, nitrous oxide,

oxygen and halothane anesthesia with a 0.2 per cent succinylcholine intravenous drip. The concentrations of halothane used at this time were not available, but the patient's vital signs showed no deviation from normal and he reacted at the conclusion of a two hour and 40 minute period of anesthesia. At the time of the admission to The University of Michigan Hospital he felt well except for the ophthalmic difficulties. Laboratory findings were normal except for evidence of mild diabetes. A second scleral imbrication with a silicone implant was carried out with endotracheal halothane, 3 liters each of nitrous oxide and oxygen per minute flow rate in a semiclosed circle filter carbon dioxide absorbing system following induction with 340 mg. of 2 per cent thiamylal intravenously. The halothane concentration varied from a high of 1.2 per cent to a low

of 0.8 per cent. Respirations were assisted throughout an uneventful operative procedure. The duration of anesthesia was two and one half hours. No blood was given. His postoperative course was uneventful and he was discharged on the seventh postoperative day.

He was readmitted seven weeks later with recurrent retinal detachment. His general health was excellent and laboratory findings were normal. A scleral imbrication with silicone sponge implantation was again performed. The anesthetic agents were endotracheal halothane, nitrous oxide, and oxygen in a semiclosed, carbon dioxide absorbing, circle filter system. Anesthesia was induced with 300 mg. of 2 per cent thiamylal, intravenously. The concentration of halothane, throughout the uneventful operative procedure, varied from 0.8 per cent to 1 per cent.

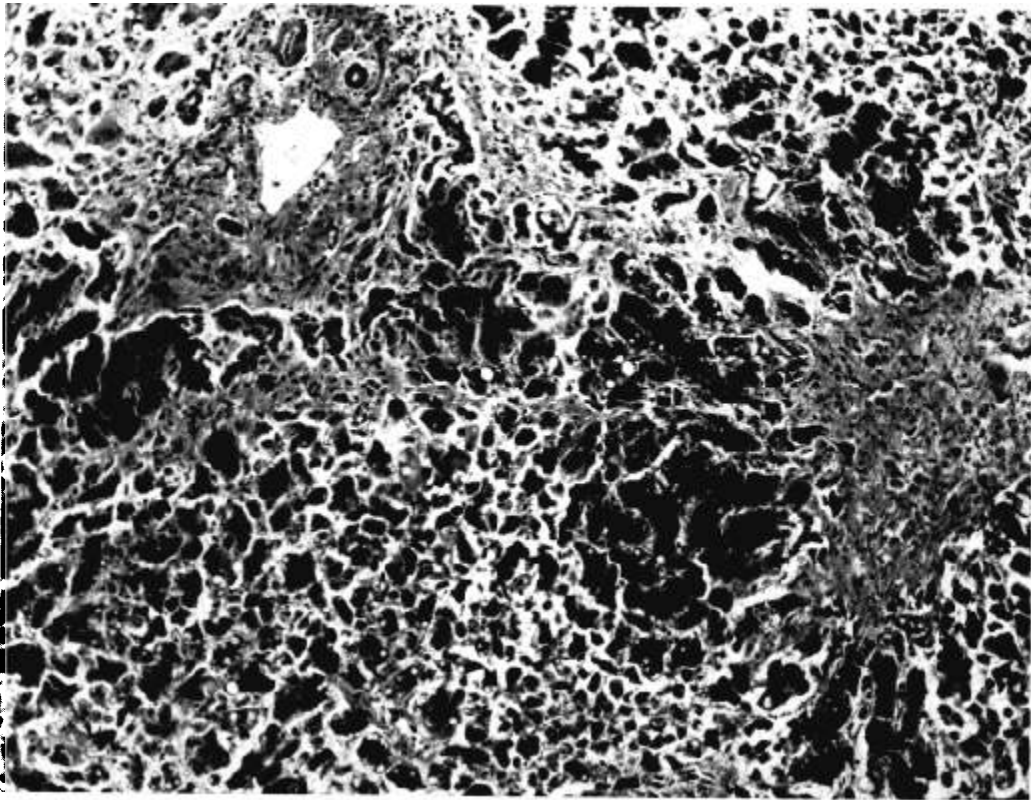


FIG. 4. *Case 2:* The liver at necropsy. In the lower left and extreme upper right hand corners there are necrotic hepatic parenchymal cells. The surviving cells are in the periphery of the lobules and are the site of lipidic change. No inflammatory cells are present. The fibrous area in the middle right hand portion of the photograph is collapsed stroma. This lesion is felt to be most consistent with toxic hepatitis. (Hematoxylin and eosin, from 90 \times .)

The anesthesia lasted for two hours and 45 minutes. The patient reacted at the conclusion of anesthesia and was returned to the recovery room in a satisfactory condition. No blood was given.

By the third postoperative day he was "depressed"—a state most unusual for this patient who was invariably cheerful. He was anorexic, lethargic, completely tired out, and frequently slept. He was discharged on the sixth postoperative day. Shortly thereafter nausea and jaundice became apparent. He expired ten days later of hepatic failure, 16 days after the last operative procedure.

A necropsy was performed at an outside hospital. The liver was reported to be "very small with some necrosis grossly." Specimens of liver and other tissues were sent to us. Histologically, early cirrhosis of postnecrotic type was present. Regenerative activity was prominent; condensation of the supporting connective tissue and proliferation of bile ducts were present. In addition, there were wide areas of recent necrosis. The portal spaces contained many lymphocytes and neutrophils. Bile stasis was evident in distended intralobular canaliculi.

Case 4. This 51 year old woman came to the hospital with a painful mass in the left breast which had been present for two months. She complained of intolerance to fatty foods and flatulence for many years. Physical examination was negative except for a mass in the left breast. An excision of the mass in the breast was performed during 2 per cent thiamylal, nitrous oxide, oxygen, and halothane anesthesia. The halothane was administered in a semiclosed circle filter, carbon dioxide absorbing system with a gas flow of 4 liters per minute of nitrous oxide plus 2 liters per minute of oxygen, and the concentration of halothane varied from 0.6 per cent to 1 per cent. The anesthetic course was uneventful, and the patient's vital signs remained stable throughout. She reacted at the conclusion of anesthesia and was returned to the recovery unit in satisfactory condition. The duration of anesthesia was one and one half hours.

The breast lesion proved to be a ruptured epidermal cyst. On the second postoperative day she developed right upper quadrant pain, nausea, vomiting, temperature 100.8° F., and

leukocytosis, 15,500/mm.³ A diagnosis of acute cholecystitis was made. An oral cholecystogram using bunamiodyl disclosed non-visualization of the gallbladder. Because the symptoms did not abate after 24 hours, a cholecystectomy and common bile duct exploration were carried out.

The anesthesia for this procedure consisted of semiclosed, endotracheal halothane, nitrous oxide, and oxygen in a system with a total gas flow of 6 liters per minute following induction using 400 mg. of 2 per cent thiamylal, intravenously. Oxygen was maintained at a concentration of at least 33 per cent, and the halothane concentration did not exceed 1 per cent at any time. Gallamine, 160 mg., was used for muscular relaxation during the operative procedure. During the course of anesthesia the blood pressure dropped from a normal of 134/90 mm. of mercury to 100/80 mm. of mercury on two occasions, but for the most part, it was maintained at approximately 120/90 mm. of mercury. At the conclusion of anesthesia the blood pressure was 118/84 mm. of mercury, pulse 100 per minute; the patient was returned to the recovery unit reacting and in a satisfactory condition. Anesthetic time was three and one half hours. No blood was given.

A large, distended, edematous gallbladder filled with small stones was found. The appearance of the liver was unremarkable; it was not biopsied. Liver function tests on the morning of the operative procedure were normal.

Immediately postoperatively the patient did well; temperature returned to normal as did white blood cell count. On the fifth postoperative day she developed urticaria and fever. She had received penicillin and this was promptly discontinued. The urticaria abated but the fever persisted, ranging from 102° F. to 104° F. Operative and postoperative cholangiograms were normal. By the eleventh postoperative day scleral icterus had appeared. The white cell count was 17,000/mm.³ Total bilirubin level was 3.8 mg./100 ml., one-minute direct, 2.0 mg./100 ml.; alkaline phosphatase, 16.0 King-Armstrong units, and serum transaminase, 1,160 units. By the twentieth postoperative day the bilirubin level had risen to 13.3 mg./100 ml., 7.0 mg./

100 ml. direct; alkaline phosphatase was 18 King-Armstrong units but transaminase had dropped to 618 units. The T-tube continued to drain clear yellow bile. The patient was lethargic, anorexic, and seriously ill. An exact diagnosis was not established, but coincidental acute viral hepatitis was considered. Neither obstructive jaundice nor hemolysis were considered to be a factor. Ascending cholangitis was considered but the liver was not tender. She gradually recovered and was discharged 35 days after operative procedure. Since that time she has been followed in the Out Patient Department and has improved; liver function tests have returned to normal.

Discussion

In 1958 Virtue and Payne² reported a postoperative death after halothane anesthesia that was virtually identical to the first two cases of this report. Their patient was a 39 year old woman who underwent cholecystectomy and exploration of the common bile duct with insertion of a T-tube. She died on the eleventh postoperative day with acute yellow atrophy of the liver and acute pancreatitis. The liver was the site of severe central, midzonal, and peripheral necrosis without abscesses; the hepatic vessels were intact. The authors commented that the clinical course was similar to that of delayed chloroform poisoning, except that the patient did not begin to have difficulty until the sixth postoperative day. Our patients' symptoms began on the twelfth, ninth, third, and fifth postoperative days respectively. Virtue and Payne stated that there was no proof that delayed halothane poisoning had occurred in their patient but that the circumstances warranted presentation of the information.

Burnap, Galla, and Vandam³ reported two patients in whom histologic examination of the liver was possible after halothane anesthesia. The first was a 48 year old man who died on the sixth postoperative day following aortic valvuloplasty; he had had severe aortic stenosis, heart failure, and hepatic dysfunction preoperatively, secondary to the heart failure. At the time of necropsy, marked centrilobular necrosis of the liver was present. This was consistent either with prolonged chronic passive congestion or with chloroform poisoning,

and in this case it was impossible to state the etiology of the necrosis. The second case was a 46 year old man who presented with postnecrotic cirrhosis ten weeks after a frontal sinusectomy performed under halothane anesthesia. There was no history of alcoholism, jaundice, exposure to hepatic toxins, or an illness resembling hepatitis. This case resembles the present case 3, also with postnecrotic cirrhosis.

Barton⁴ reported two cases of jaundice following halothane anesthesia. The first, a man with a retropubic prostatectomy, developed jaundice of such severity that three weeks after the first operative procedure an exploratory laparotomy was performed to exclude obstructive jaundice; no obstruction of the biliary tree was found; and three weeks following laparotomy jaundice subsided. The second case was that of an 11 year old child who had had halothane anesthesia for a fractured patella. Jaundice persisted after one week; further details were not given.

Dobkin⁵ pointed out that Barton did not give details of anesthetic technique, premedication, or postoperative drugs. He suggested that the possibilities of transfusion reaction, homologous serum jaundice, or coincidental infectious hepatitis should be checked.

At the time that the present cases were in the hospital, the attending physicians had difficulty in establishing diagnoses. Two of the patients, cases 1 and 2, had incidental liver biopsies at the time of cholecystectomy, and in both these were normal. Two of them had T-tubes (cases 2 and 4), through which normal operative and postoperative cholangiograms were obtained. Extrahepatic obstructive jaundice appeared to have been excluded although intrahepatic obstruction remained a possibility; ascending cholangitis was also considered in both cases; necropsy findings in case 2 unequivocally disproved these diagnoses. Severe hepatocellular damage was present; the clinical diagnosis of coincidental acute viral hepatitis was made in all four cases. None of the four patients had received blood transfusion during operative procedures.

These four cases offer no proof that halothane was the direct cause of the massive hepatic necrosis; however, the implications that such is the case are strong. The two pa-

tients with normal liver biopsies first had clinical symptoms of hepatic disease on the twelfth and ninth postoperative days and expired on the twentieth and forty-third postoperative days respectively. The duration of clinical liver disease, then, was eight and 34 days. The third patient became ill on the third postoperative day and expired after 13 days of illness. Durations of these illnesses are compatible with viral hepatitis. Luckó and Mallory⁶ described the acute fulminant form of hepatitis in 94 cases, under ten days' duration. Many of the patients were wounded soldiers who had received transfusions of blood and plasma, but many were "spontaneous" cases who had received no such treatment. Nevertheless, it is unusual that our three cases had short courses. The fact that the liver biopsies were normal at the time of the operative procedures does not preclude the possibility of hepatitis; the patients could have been in the incubation phase at that time. It does, however, prove that the patients did not have clinical hepatitis or other hepatocellular disease at that time.

The histologic differentiation between acute toxic hepatitis and acute viral hepatitis, especially in cases in which there is massive or submassive hepatic necrosis, can be very difficult and often impossible. Luckó⁷ and Popper and Franklin⁸ describe differences but these are subtle. The hepatic endophlebitis that occurs in viral hepatitis was not seen in the present cases nor was the extensive inflammatory infiltrate of that disease present. Indeed, in case 2 there were few inflammatory cells present. In case 3 significant numbers of neutrophils were present; their presence may suggest toxic hepatitis rather than viral hepatitis but this is not a specific finding. In cases 1 and 2 there was lipidic change in surviving cells, a point in favor of toxic hepatitis. Luckó and Popper emphasized that in acute viral hepatitis necrotic liver cells were not seen; that they quickly were lysed and disappeared. In toxic hepatitis, coagulation necrosis, fatty change, and evidence of slow cell death may be more apparent; these changes were seen in case 2 as there were broad areas of "ghost" cells and cells that had undergone coagulative necrosis. Changes in cases 1 and 3, however,

are indistinguishable from those seen in examples of viral hepatitis.

The most intriguing aspect of these cases is that three of the four patients were women on whom cholecystectomy and (in two) common bile duct exploration were performed. Virtue and Payne's case (*vide supra*) was similar. Liver function tests in all three were normal preoperatively although case 1 did have 12 per cent Bromsulphalein retention and prothrombin time of 61 per cent. What specific effect this type of operative procedure has, we are unable to say at this time. Two patients received bunamiodyl which has been reported by Bolt, Dillon and Pollard⁹ to produce transient elevation of serum bilirubin; the effect is said to be temporary and to be gone by two days after the ingestion of the dye. As these patients first became ill on the ninth and fifth postoperative days it seems unlikely that the drug was a significant cause of the hepatocellular damage although it is possible. Case 3 had only an ophthalmic surgical procedure and received no hepatotoxic drugs. Two of the patients (cases 3 and 4) had more than one period of anesthesia with halothane. Case 3 had three halothane anesthetics in a period of four months; case 4 had two anesthetics in four days. What effect the repeated anesthetics had upon the liver, we cannot say.

The anesthetic course in each instance in the four patients presented would appear to be quite unremarkable and there is no suggestion that the patients suffered hypoxia or hypercapnea at any time. The vital signs throughout the course of the operative procedures remained remarkably stable in all instances and the patients' anesthetic records would appear to be typical of thousands of others in which anesthesia was conducted with this agent.

Summary

Four case histories are presented, three of them fatal in which the patients developed massive hepatic necrosis (acute yellow atrophy) following surgical procedures under halothane anesthesia. Liver biopsies from two of these patients were normal at the time of the operative procedure. The possible causative

factors involved are discussed and evaluated. We believe it to be significant that three of the four patients presented had surgical procedures on the biliary tract.

References

1. Johnstone, M.: Halothane-oxygen: a universal anaesthetic, *Brit. J. Anaesth.* **33**: 29, 1961.
2. Virtue, R. W., and Payne, K. W.: Postoperative death after Fluothane (case report) *ANESTHESIOLOGY* **19**: 562, 1958.
3. Burnap, T. K., Galla, S. J., and Vandam, L. D.: Anesthetic, circulatory, and respiratory effects of Fluothane, *ANESTHESIOLOGY* **19**: 307, 1958.
4. Barton, J. D. M.: Letter to the Editor, *Lancet* **1**: 1097, 1959.
5. Dobkin, A. B.: Letter to the Editor, *Lancet* **1**: 1248, 1959.
6. Lucké, B., and Mallory, T. B.: The fulminant form of epidemic hepatitis, *Amer. J. Path.* **22**: 867, 1946.
7. Lucké, B.: The pathology of fatal epidemic hepatitis, *Amer. J. Path.* **20**: 471, 1944.
8. Popper, H., and Franklin, M.: Viral versus toxic hepatic necrosis, *Arch. Path.* **46**: 338, 1948.
9. Bolt, R. J., Dillon, R. S., and Pollard, H. M.: Interference with bilirubin excretion by a gall bladder dye (bunamiodyl), *New Engl. J. Med.* **265**: 1043, 1961.

EEG AND PCO₂ Twelve subjects had electroencephalogram studies concurrent with arterial P_{CO₂} and pH determinations. The effects of voluntary hyperventilation and megimide administration were determined. Three minutes of hyperventilation changed average P_{CO₂} from 39.8 to 17.2 mm. of mercury, and changed pH from 7.4 to 7.6. Megimide 0.5 per cent was injected at 10 mg. per minute, total dosage 40 to 150 mg. This lowered P_{CO₂} to 37.9 mm. of mercury, but had no effect on pH. The electroencephalographic-activation responses to megimide, therefore, are not caused by respiratory alterations. (*Sellden, U.: Role of Hyperventilation in the Initial Electroencephalographic Responses to Activation with Megimide, Electroenceph. Clin. Neurophysiol.* **14**: 368 (June) 1962.)

PORPHYRIA Acute intermittent porphyria has been regarded as a rare disease. Recent investigations, however, suggest that incidence of this genetic metabolic defect is probably not as rare as was hitherto believed. Recognition of latent carriers of this disease is important, since unrecognized porphyric patients are in danger of being given barbiturates or other drugs which may lead to an acute attack with neurologic damage or even death. The usual initial symptom of an acute attack of intermittent porphyria is severe abdominal colic. During an acute attack, the patient with unrecognized porphyria may be subjected to a needless surgical procedure. The operation may be preceded by administration of a barbiturate for sedation, or anesthesia with a barbiturate may be employed. The abdominal colic may be associated with severe mental derangement and paralysis or paresis of groups of skeletal muscles. The diagnosis, which is often overlooked, can be made by checking the urine for increased porphobilinogen excretion by an easily-performed screening test. Barbiturates should under no circumstances be given to patients with porphyria. (*Editorial: Acute Intermittent Porphyria, J. A. M. A.* **181**: 785 (Sept. 1) 1962.)