

# The Subclavian Perivascular Technique of Brachial Plexus Anesthesia

Alon P. Winnie, M.D., and Vincent J. Collins, M.D.

The prevertebral fascia envelops the brachial plexus from the cervical vertebrae to the distal axilla, forming a subclavian perivascular space that is continuous with the axillary perivascular space. By applying the concept of the axillary perivascular technique to the supraclavicular approach, the authors have developed the subclavian perivascular technique which affords greater simplicity, safety and consistency of results than presently used supraclavicular technique. Just as with peridural technique, once the space has been entered only a single injection is necessary and the extent of anesthesia will depend on the volume of anesthetic and the level at which it is injected. Sufficient volumes by either approach will produce cervical as well as brachial plexus anesthesia since the cervical plexus travels in the same space at a higher level.

Over the past 5 years, the axillary perivascular technique of brachial plexus block has become increasingly popular. Application of the perivascular technique to the axillary approach produced results in many clinics that were far more consistent than those obtained with the supraclavicular approach, which previously had been almost universally preferred for brachial plexus anesthesia. The purpose of this paper is to report the feasibility of applying the perivascular technique to the supraclavicular approach.

## Axillary Perivascular Technique

The original axillary technique of Hirschel<sup>1</sup> in 1911, and the later modification of Pitkin<sup>2</sup> in the 1920's, were actually nerve blocks of the cords, trunks and roots of the brachial plexus. Though the site of skin puncture was indeed in the axilla, the site of injection of anesthetic solution was the level of the first rib or above, as in the supraclavicular ap-

proach. Reding,<sup>3</sup> in 1921, was the first to describe block of the terminal nerves of the plexus within the axilla. More significantly, he noted that the nerves within the axilla were enclosed in a sheath which favored the diffusion of anesthetic solution such that the median, radial and ulnar nerves were all anesthetized with the same injection. Though Reding's results were excellent, blockade at this level was neglected until 1949 when Accardo and Adriani<sup>4</sup> described their technique; however, they did not attempt to identify the sheath, but merely to block the individual nerves separately.

In 1958, the axillary perivascular technique as understood today was described by Burnham.<sup>5</sup> During surgery for a deep laceration of the apex of the axilla he observed the compactness of the nerves arranged around the artery and the manner in which they were enclosed by a fascial sheath, and he was impressed by the potential efficacy of a block at this level. The technique he developed consisted of merely penetrating the axillary sheath above and below the artery at the level of insertion of the pectoralis major and latissimus dorsi muscles. When the needle perforated the sheath, a characteristic "click" was felt, following which the anesthetic solution was injected without any attempt to elicit paresthesias. Eather, who developed an almost identical technique independently,<sup>6</sup> pointed out that results were most consistent when a large volume of solution was injected. In 1961, De Jong<sup>7</sup> showed *volume* to be the critical factor. On the basis of anatomical dissection, he showed that the musculocutaneous and axillary nerves usually leave the axillary sheath at the level of the second portion of the axillary artery and can be reached consistently only when a sufficient volume of solution is injected inside the neurovascular compartment to dif-

Received from the Department of Anesthesiology, Cook County Hospital and Hektoen Institute, Chicago, Illinois; and Northwestern University School of Medicine; accepted for publication February 12, 1964.

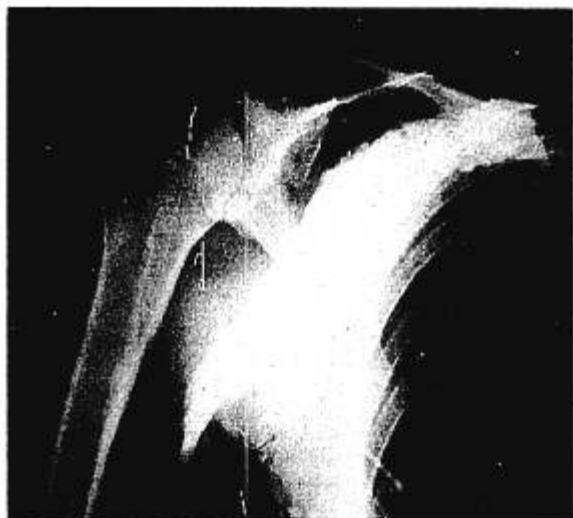

FIG. 1. Roentgenogram taken after injecting 50 ml. of radiopaque dye into the axillary perivascular space. Upper limit of dye is over the first rib.

fuse upwards of the level of the cords. Using the formula for the volume of a cylinder and assuming diffusion to be equal in both directions, he calculated that a minimum of 42 ml. is necessary to achieve this level in the aver-

age adult. These calculations were validated roentgenographically by the present authors by injecting radiopaque dye into the sheath via the axilla, as may be seen in figure 1. Though the solution does not diffuse equally in both

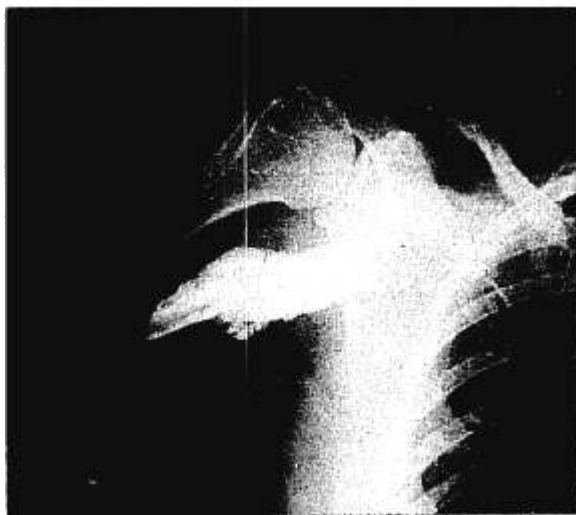

FIG. 2. Roentgenogram taken after injecting 25 ml. of radiopaque dye into the axillary perivascular space. Upper limit of dye does not reach the coracoid process, the approximate level of the cords.

directions, it does require 40–50 ml. to reach the level of the first rib. Figure 2 shows that a 25-ml injection does not even reach the level of the coracoid process (the approximate level of the cords), a result confirming the theoretical conclusion that this volume frequently will be insufficient to block the musculocutaneous and axillary nerves.

The axillary perivascular technique, by its simplicity, safety and consistency of results, rapidly gained popularity; and comparative studies appeared in the literature proclaiming superiority over previously employed supraclavicular techniques.<sup>8,9</sup> However, the accepted practice of making two injections, one superior and one inferior to the axillary artery, seemed no more logical to the authors than making anterior and posterior injections in the epidural space. Thus, we and others have simplified the technique by making a single injection of solution into the sheath without decreasing the high percentage of successful blocks achieved with the two-injection technique. With this simplification, continuous axillary brachial block now became possible and has been used in a number of cases where prolonged analgesia, immobilization and/or sympathetic blockade was desirable. (The roentgenograms shown in figures 1 and 2 were made by injecting radiopaque dye through such continuous axillary catheters in surgical patients upon the completion of operation but before the anesthesia had worn off.)

*The Sheath of the Brachial Plexus.* The axillary sheath, so important to the concept of the axillary perivascular technique, is merely a tubular prolongation of the prevertebral fascia. Thus, the axillary perivascular space is continuous with a subclavian perivascular space formed by the scalene portion of the prevertebral fascia as follows:

As seen in figure 3, the anterior scalene muscle arises from the anterior tubercles of the transverse processes of the third, fourth, fifth and sixth cervical vertebrae, inserts on the scalene tubercle of the first rib, and separates the subclavian vein from the subclavian artery, which lies posterior to this insertion. The middle scalene muscle arises from the posterior tubercles of the transverse processes of the lower six cervical vertebrae. Its insertion is

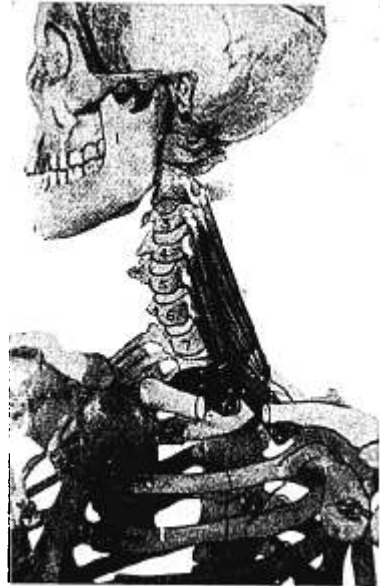

FIG. 3. The formation of the interscalene or subclavian perivascular space by the anterior and middle scalene muscles. (From *Brachial Plexus Anesthesia*, by MacIntosh and Mushin with permission of the publishers.)

separated from that of the anterior scalene by the subclavian groove through which the artery passes.

Thus, since the roots of the nerves comprising the cervical and brachial plexuses travel along the groove between the anterior and posterior tubercles of the transverse processes of the cervical vertebrae, they emerge between the two walls of fascia covering the anterior and middle scalenes, *i.e.*, they enter the interscalene or subclavian perivascular space. As the roots pass down through this space (fig. 4), they converge to form the trunks of the brachial plexus, which together with the subclavian artery invaginate the scalene fascia, which becomes the axillary sheath as it passes under the clavicle. Figure 5 is a cross section through this space, at the level of the first rib, showing the deep but narrow shape of the space at this level, with

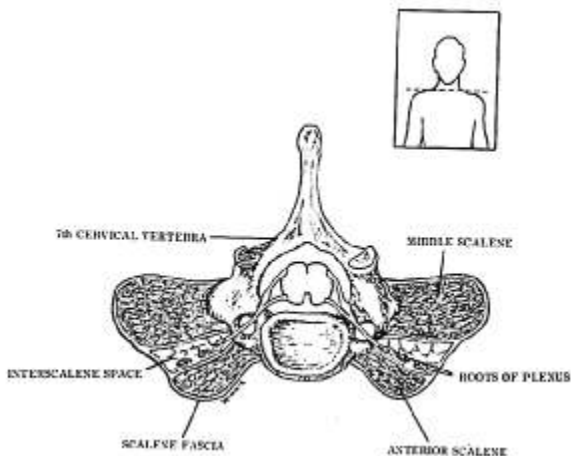


FIG. 4. Cross section through the subclavian perivascular space at a level just superior to the seventh cervical vertebra, showing the fifth and sixth roots traveling down between the fascia investing the anterior and middle scalenes. (After Bonica.)

the trunks lying one atop the other as they cross the rib.

The important concept for the anesthetist is that of a continuous fascia-enclosed space extending from the cervical transverse processes to several centimeters beyond the axilla,

or from the roots of the brachial plexus to the great nerves of the upper arm. Mathews<sup>10</sup> has recently reported that the supra- and infra-clavicular portions of the space are separated by the coraco-clavicular fascia. That such is not the case has been demonstrated by us not

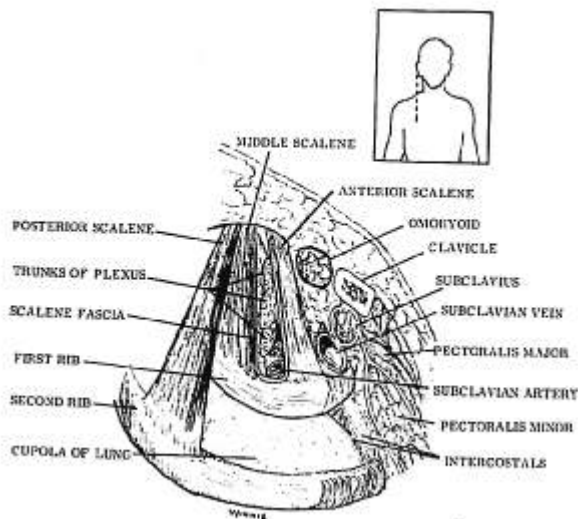
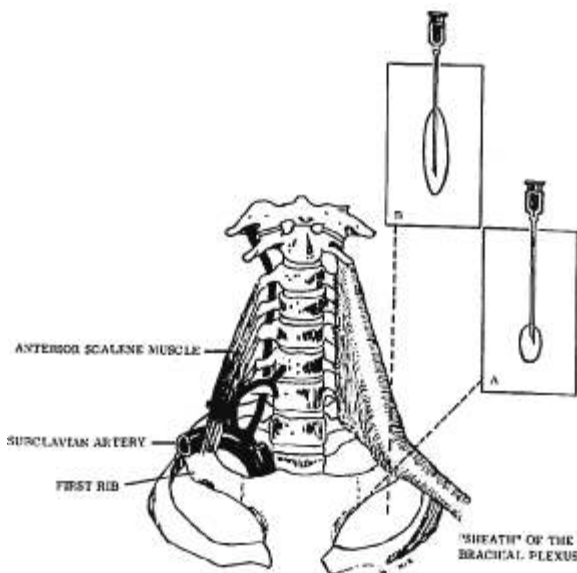


FIG. 5. Cross section through the subclavian perivascular space (in the sagittal plane) at the level of the first rib. Note the deep but narrow shape of the space at this level and the manner in which the trunks lie one atop the other. (Schematized from anatomical dissections.)

FIG. 6. The "brachial plexus sheath" forming the subclavian perivascular space, schematized from an anatomical dissection where the scalene muscles have been removed. Insert A is a cross section through the space at the level of the authors' technique, showing the greater depth of the space at the latter level.



only by radiopaque dye studies but also by demonstrating clinically that cervical plexus anesthesia may be produced by injecting large volumes of anesthetic solution into the axillary sheath. Additional proof lies in the fact, long known to surgeons, that a collection of fluid under the prevertebral fascia may extend down this fascial tube along the axillary vessels and appear as a swelling on the lateral wall of the axilla along the course of the artery.<sup>11</sup>

#### Subclavian Perivascular Technique

Most techniques currently employed in the supraclavicular approach to the brachial plexus have several features in common: First, the site of needle insertion is about one centimeter above the midpoint of the clavicle, just posterolateral to the subclavian artery; second, the direction of injection is mesiad, caudad and dorsad; third, the first rib is used as a "back-stop," and the needle is walked along the rib to obtain paresthesias of various distribution; fourth, the injections are multiple, 5 to 10 ml.

being injected each time a paresthesia is elicited; and fifth, the cupula of the lung may be pierced if the needle overshoots the rib.

A consideration of the anatomy of the "brachial plexus sheath" presented above would seem to make several of these features illogical. Figure 6 (schematized from anatomical dissections) shows the subclavian perivascular or interscalene space to be triangular in shape in a front view, with a shallow anteroposterior dimension when viewed laterally. However, the currently employed techniques, with their mesiad, caudad, dorsad direction, enter this space at the lateral angle of the triangle where the depth of the space is least, as represented in insert A. Even the slightest movement during injection at this point may cause the needle to leave the space, and with multiple injections this possibility is increased. Insert B shows that this depth is greater at a higher level and allows much greater movement of the needle without leaving the space. It can also be seen that the practice of walking the rib to obtain multiple, consecutive paresthesias

thesias is illogical, as the trunks lie atop one another as they cross the first rib and are not spread out horizontally over the rib as is depicted in so many texts.

Applying the perivascular technique to the supraclavicular approach obviates the undesirable features of the classic technique which

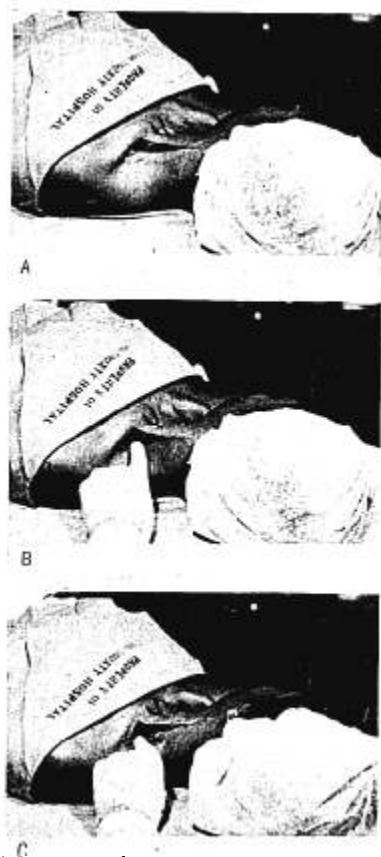


FIG. 7. The steps in performing the subclavian perivascular brachial block. The anterior scalene muscle is represented as solid black just lateral to the clavicular head of the sternocleidomastoid muscle. Note the depth and direction of the needle in C just after paresthesias has been elicited.

is modified as follows. Figure 7-A shows the patient in the customary dorsal recumbent position with the head turned somewhat to the side opposite the side being injected. The patient is told to reach for his knee as this maneuver depresses the shoulder and clavicle. Beginning at the lateral margin of the clavicular head of the sternocleidomastoid muscle, the index finger is rolled laterally across the belly of the anterior scalene muscle (represented in black in the figures) until the interscalene groove is palpated. The finger is moved inferiorly along this groove until the subclavian artery is palpated as it emerges from between the scalene muscles (figure 7-B). Figure 7-C shows that with the finger still on the artery, a  $1\frac{1}{2}$  inch, 22 gauge needle is inserted above this point in a direction that is directly caudad, but not mesial or dorsad. Thus, the direction of insertion is such that the needle is dorsally tangential to the subclavian artery, while the level of insertion is high in the triangular interscalene space, where as pointed out above, the greater depth allows considerably more movement of the needle without leaving the space. The "click" of the needle penetrating the sheath may be clearly felt if the needle is advanced slowly, and a short distance beyond this click a single paresthesia to the hand confirms the fact that the needle is definitely in the perivascular space. At this point a syringe is attached to the needle and the entire anesthetic injection is made.

The direction of needle insertion, the use of a short needle, and the use of a single injection not only tend to improve the incidence of satisfactory results, but also to minimize the possibility of pneumothorax. Since the direction of needle insertion is parallel to the borders of the scalene muscles and since these muscles insert on the rib, the position of the rib and vessels are more precisely located with this technique than with any other, although with our modification, paresthesias are usually obtained before the rib has been contacted. A logical extension of this technique is continuous subclavian perivascular block which is accomplished simply by inserting a polyethylene catheter through a larger needle similarly placed.

### Clinical Application of Perivascular Technique

The concept of perivascular anesthesia has practical clinical applications. Henceforth, brachial plexus anesthesia may be likened to peridural anesthesia, the axillary approach being analogous to the caudal and the subclavian approach to the lumbar epidural method. Thus, as with peridural techniques, once the space has been entered, only a single injection is necessary, and the extent of anesthesia will depend on the volume of anesthetic solution and the level at which it is injected.

When 25 ml. of anesthetic solution is injected into the axillary perivascular space, it will not reach the level of the cords; the musculocutaneous and axillary nerves are not

anesthetized with this volume (fig. 8). The flexors of the forearm, therefore, will not be paralyzed and sensation over the lateral aspect of the forearm will remain intact as denoted by the white areas in the figure.

Figure 9 shows that if the volume of anesthetic injected into the axillary sheath is increased to 50 ml., the solution will reach the first rib and with this larger volume motor and sensory loss of the entire arm will be complete.

In figure 10, it can be seen that 25 ml. of solution injected into the *subclavian* perivascular space results in motor and sensory loss similar to that produced by 50 ml. of solution injected into the axillary perivascular space. This fact has clinical significance, for it refutes the teaching that "the axillary approach is

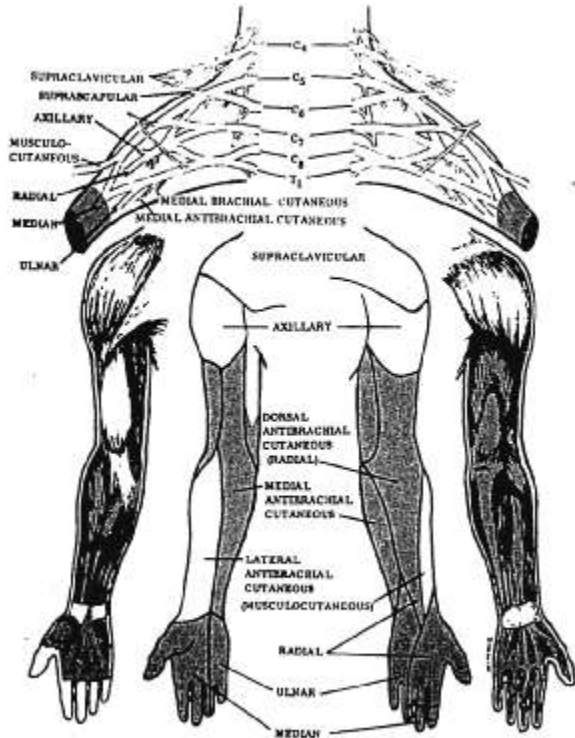


FIG. 8. Sensory and motor loss achieved by 25 ml. of anesthetic injected into the axillary perivascular space. Unshaded areas show sensory and motor components frequently missed with this volume.

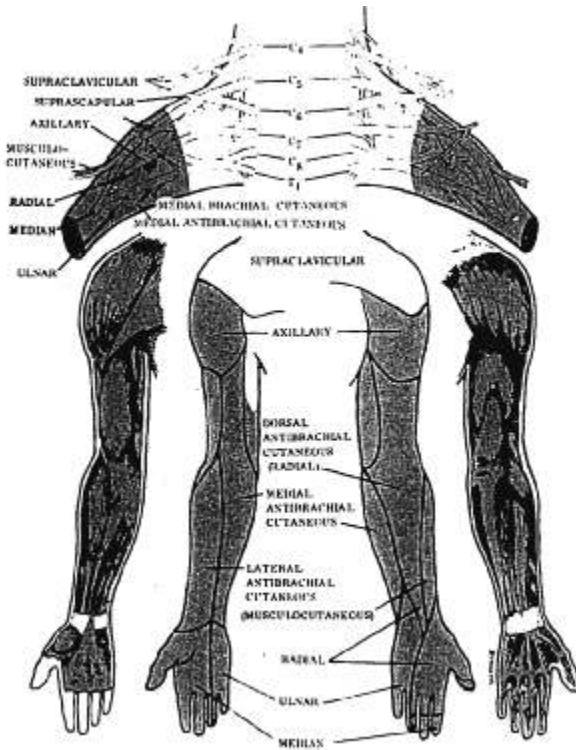


FIG. 9. Sensory and motor loss achieved by 50 ml. of anesthetic injected into the axillary perivascular space.

a compromise and can only be used to block the arm from about 2 inches above the elbow downward.”<sup>12</sup> The two situations can be differentiated clinically, however, by the onset of motor paralysis: when asked to elevate his arm, the patient having received the *subclavian* perivascular block will be unable to do so, as the *flexors* and *abductors* of the arm are the first to be blocked. The patient who has received the 50 ml. axillary perivascular block will be able to elevate his arm, but as it approaches the vertical position, the hand will fall as the *extensors* of the forearm are the first to be blocked in this approach. The *subclavian* perivascular space is well outlined in figure 12, which is a roentgenogram taken after 25 ml. of radiopaque dye was injected into the space in an adult patient.

Finally, if the volume of solution injected into the *subclavian* perivascular space is increased to 50 ml. as in figure 11, anesthesia of the arm, shoulder, and neck results, as the *cervical plexus*, which occupies the upper portion of the *interscalene space*, is blocked as well. Such “*high brachial block*” can be achieved with half this volume if the anesthetic is injected through a *Huber point needle*, which directs most of the solution upward toward the *nerve roots*. As stated earlier, *cervical* (as well as *brachial*) anesthesia can be obtained by injecting large anesthetic volumes into the axillary perivascular space, but this is not recommended clinically because of the high doses of anesthetic required.

The implications of the above data are that the approach of the *brachial plexus* need not



be determined by the level at which the contemplated operation is to be performed, as identical levels of anesthesia of the forearm, upper arm, shoulder girdle and neck may be obtained by either approach simply by varying the volume of anesthetic agent injected.

### Results

The subclavian perivascular technique as described (with paresthesias) provided complete anesthesia in 98 per cent of the first 100 cases injected. It should be emphasized that unlike the axillary perivascular technique the production of paresthesias is essential to obtain this degree of success. This was corroborated in 50 cases where the technique was identical

to that described above except that paresthesias were not elicited, and in this group only 88 per cent of injections provided complete anesthesia.

Mepivacaine (Carbocaine) has been our anesthetic of choice in such procedures. Our clinical data corroborate the experimental findings of Albert and Löfstrom,<sup>13</sup> who showed this agent to have a slightly more rapid onset of action than lidocaine (Xylocaine) with almost twice the duration of analgesia. In addition, we have noted that the effects of mepivacaine on the cardiopulmonary and central nervous systems are far less depressant than equipotent doses of lidocaine. If muscular relaxation is not essential the 1 per cent concentration routinely provides adequate

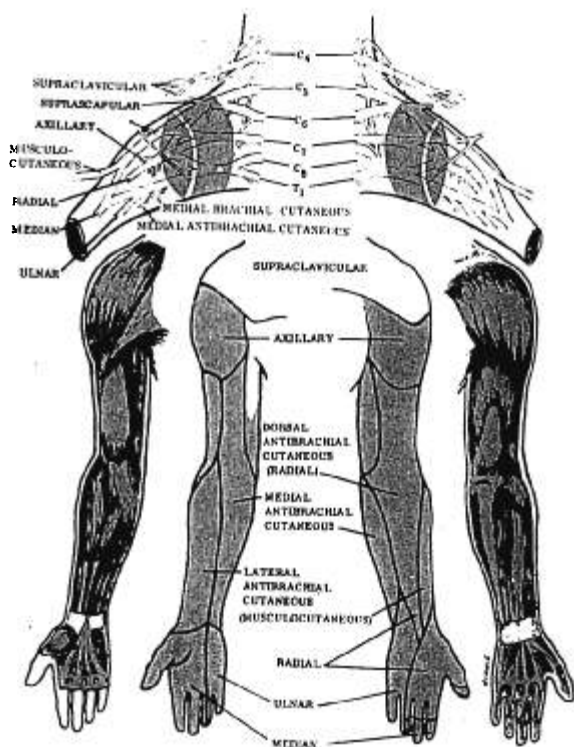


FIG. 10. Sensory and motor loss achieved by 25 ml. of anesthetic injected into the subclavian perivascular space.

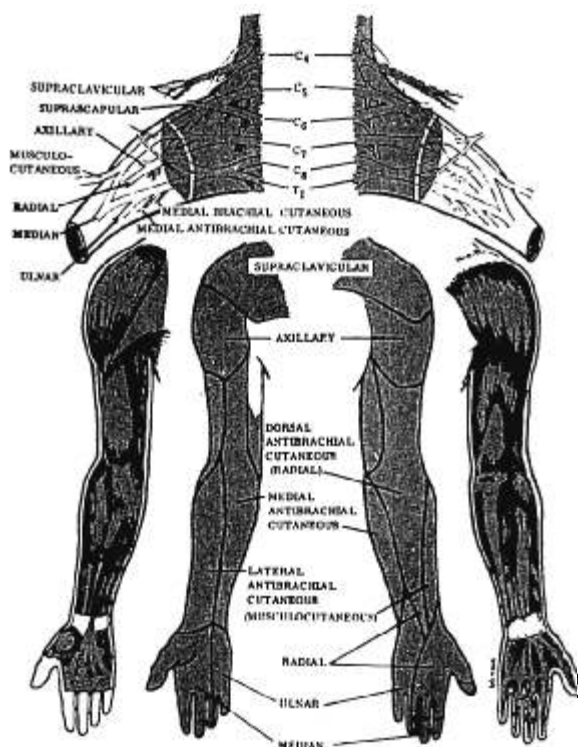


FIG. 11. Sensory and motor loss achieved by 50 ml. of anesthetic injected into the subclavian perivascular space. This volume effects a "high brachial block" as it includes the cervical plexus. The same effect may be obtained by injecting 25 ml. through a Huber point needle directed medially.

anesthesia. However, if relaxation is necessary a 1.5 per cent concentration must be used, as the critical motor concentration in most individuals appears to lie between 1.0 and 1.5 per cent.

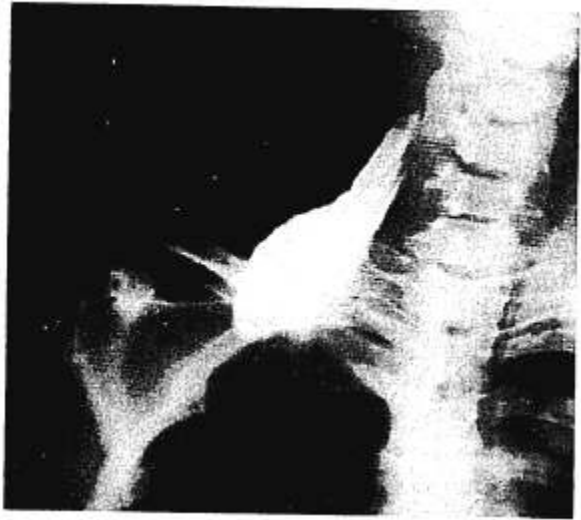**Complications.** We have not seen pneumothorax using this technique, but this was to be expected since the needle follows the course of the scalene muscles which insert on the first rib. Thus, if the needle should overshoot the plexus, it is invariably stopped by the first rib. Occasionally, the subclavian artery is penetrated by the needle, but no such puncture has had serious sequelae. Even the formation of a hematoma is rare with a 22 gauge needle, particularly if the needle has a Huber point.

Phrenic nerve paralysis occurred in one case, and in one case convulsions followed the injection by 40 minutes, but this patient was an epileptic with delirium tremens, so the role of the anesthetic agent would appear to be obscure. There have been no instances of nerve damage following a subclavian perivascular block.

### Summary

If the fact is considered that the prevertebral fascia envelops the brachial plexus from the cervical vertebrae to the distal axilla and thus forms a continuous perineural space, conduction anesthesia of the upper extremity becomes technically very simple. The space may be entered at any level, and the volume of anes-

FIG. 12. Roentgenogram taken after injecting 25 ml. of radiopaque dye into the subclavian perivascular space. The nerve roots can be seen travelling from the transverse processes downward toward the first rib.



thetic injected at that level will determine the extent of anesthesia. Since the plexus is accompanied by the subclavian and axillary artery from the trunks distalward, the space is perivascular as well as perineural, and may be entered most easily by inserting a needle tangential to the vessel at the desired level. The "click" of the needle penetrating the sheath, and in the subclavian perivascular technique, the subsequent production of a paresthesia, signify that the space has been entered. Injection of the anesthetic solution results in an almost immediate onset of anesthesia. The subclavian perivascular technique as described provided complete anesthesia in 98 of the first 100 cases blocked.

### References

1. Hirschel, G.: Die Anesthesierung des Plexus Brachialis bei Operationen an der oberen Extremitat, Munchen. med. Wschr. 58: 1555, 1911.
2. Southworth, J. L., Hinson, R. A., and Pitkin, W. M.: Pitkin's Conduction Anesthesia. Philadelphia, J. B. Lippincott Company, 1953.
3. Reding, M.: Nouvelle Methode D'Anesthesie Du Membre Superieur, Presse Med. 29: 294, 1921.
4. Accardo, N. J., and Adriani, J.: Brachial plexus block: a simplified technic using the axillary route, South. Med. J. 42: 920, 1949.
5. Burnham, P. J.: Regional block of the great nerves of the upper arm, ANESTHESIOLOGY 19: 281, 1958.
6. Eather, K. F.: Axillary brachial plexus block (correspondence), ANESTHESIOLOGY 19: 683, 1958.
7. De Jong, R. H.: Axillary block of the brachial plexus, ANESTHESIOLOGY 22: 215, 1961.
8. Hamelberg, W., Dysart, R., and Bosomworth, P.: Perivascular axillary versus supraclavicular brachial plexus block and general anesthesia, Anesth. Analg. 41: 85, 1962.
9. Brand, L., and Papper, E. M.: A comparison of supraclavicular and axillary techniques for brachial plexus blocks, ANESTHESIOLOGY 22: 226, 1961.
10. Mathews, W. A.: Axillary block, Int. Anesth. Clin. 1: 707, 1963.
11. Anson, B. J., and Maddock, W. G.: Callander's Surgical Anatomy. Philadelphia, W. B. Saunders Company, 1958.
12. Moore, D. C.: Regional Block of the Upper Extremity: Supraclavicular Approach Versus Axillary Approach. Refresher course, Annual Meeting of American Society of Anesthesiologists, November 2-6, 1963.
13. Albert, J., and Löfstrom, B.: Bilateral ulnar nerve blocks for the evaluation of local anesthetic agents, Acta Anaesth. Scand. 5: 99, 1961.