

Evaluation of Methods Employed in the Treatment of the Chemical Pneumonitis of Aspiration

Aleksander Lewiński, M.D.

The object of the study was to examine the efficacy of methods used in handling the aspiration syndrome. Fifty animals, grouped in two series, were studied. The first series (26 cats) served to establish the amount of 0.1 N HCl producing inflammatory changes and the time of their occurrence, and to ascertain whether the liquids and drugs used for instillation into the tracheobronchial tree produce morphologic changes in the lungs. The second series (24 cats) served to determine the therapeutic efficacy of instilling the aforementioned solutions and drugs after instillation of hydrochloric acid. The results obtained and a review of the experiments of others suggest that the treatment of aspiration chemical pneumonitis should be carried out by immediate instillation of small quantities of highly concentrated hydrocortisone into the tracheobronchial tree with supporting intramuscular or intravenous injections of that drug in the postoperative period, and simultaneous administration of antibiotics.

THE PRESENT study was undertaken in order to examine the efficacy of the methods employed in handling the aspiration syndrome,^{1, 5, 6, 8-13, 15, 16, 19} described by Mendelson¹⁴ and to attempt to find better procedures capable of preventing this serious complication.

Material and Methods

The first series of experiments was designed to determine the amount of 0.1N HCl producing microscopically detectable inflammatory responses in the lung parenchyma and to find out at what stage these lesions are most marked. These experiments served also to ascertain whether the solutions (normal saline, distilled water, 1.3 per cent sodium bicarbonate) instilled into the tracheobronchial tree without previous treatment with hydro-

chloric acid, are responsible for morphologic changes in the lung tissue.

The second series of experiments was intended to determine the therapeutic efficacy of instilling the aforementioned solutions into the tracheobronchial tree after instillation of hydrochloric acid.

Experiments were carried out on male and female cats, weighing 1,400 g. to 3,700 g., kept in individual cages and fed a normal diet. A total of 60 animals were used. Ten died during the experiments, 4 immediately after receiving HCl solution, 6 in consequence of lung edema. The remaining 50 animals formed the basis of the experiments. Twenty-six animals were used in the initial series of experiments; 24 formed the experimental series proper. The first group of the first series consisted of 11 animals which served to establish the amount of 0.1N HCl required to produce marked inflammatory changes, and the time in which these changes occur. The 15 animals in the second group of that series were subjected only to instillation into the tracheobronchial tree of drugs whose efficacy was examined in further experiments. Three animals were used to test each of the solutions and drugs instilled. The lungs of one group were examined 48 hours following the instillation, others after 48 hours and after 21 days, respectively.

In the second series of experiments 24 animals had 10 ml. 0.1N HCl instilled into the lungs and then were subjected to the following procedures (all subsequent instillations within 2 to 3 minutes):

Group I—10 ml. of saline instilled into the lungs.

Group II—10 ml. of distilled water instilled.

Group III—10 ml. of 1.3 per cent sodium bicarbonate solution instilled.

From the Department of Anaesthesia, Third Surgical Clinic (Head: Prof. Z. Kieturakis), Medical Academy, Gdańsk, Poland. Accepted for publication September 3, 1964.

TABLE 1. Therapeutic Efficacy of Solutions and Drugs in the Tracheobronchial Tree After Instillation of 0.1N HCl

Group	Animals	Body Weight g.	Agent	Dose	Macroscop. Changes %*	Microscopically					Remarks
						Edema	Sloughing	Suppuration	Necrotizing Lesions	Hemorrhagic Lesions	
I	1	2,800	Normal Soda	10 ml.	12.5	-	-	++	+++	+++	died after experiment died after 30 hours
	2	1,750		10 ml.	12.5	+	+	++	+++	+++	
	3	2,270		10 ml.	50	+	+	++	+++	+++	
II	1	3,650	Distilled H ₂ O	10 ml.	25	+	+	++	+++	+++	
	2	1,850		10 ml.	12.5	+	+	++	+++	+++	
	3	2,650		10 ml.	50	++	+	+	++	++	
III	1	2,700	1.3% Soda Bicarbonate	10 ml.	50	+	+	+	++	++	slight transitory lung edema during experiment
	2	2,750		10 ml.	12.5	+	+	+	+++	+++	
	3	2,050		10 ml.	12.5	++	+	+	++	++	
IV	1	2,000	Hydrocortisone (intranasal)	every 6 hours 10 mg.	50	+++	++	-	++	++	died after 18 hours
	2	1,650		every 6 hours 10 mg.	12.5	++	+	-	++	++	
	3	2,000		every 6 hours 15 mg.	25	+	+	-	+++	+++	
V	1	2,575	Urea (intravenous)	1 g./kg.	50	+++	+	++	+	+	
	2	2,600		1 g./kg.	12.5	+++	++	-	+	+	
	3	2,700		1 g./kg.	25	+++	++	+	+	+	
	4	3,000		1.5 g./kg.	50	+++	++	+	++	++	
	5	2,250		1.5 g./kg.	25	+++	++	+	+	+	
	6	2,500		1.5 g./kg.	25	+++	++	+	+	+	
VI	1	2,650	Hydrocortisone (intravenous)	25 mg./10 ml. Natr. bicarb.	-	+	+	-	-	-	
	2	1,430		25 mg./10 ml. Natr. bicarb.	6.25	+	+	-	+	+	
	3	2,450		50 mg./10 ml.	-	+	+	-	+	+	
	4	3,250		50 mg./10 ml.	-	+	+	-	+	+	
	5	3,000		50 mg./10 ml.	6.25	+	+	-	-	-	
	6	3,500		25 mg./10 ml.	-	+	+	-	-	-	

*% 1 lung = 50%.

+++ = very extensive; ++ = extensive; + = slight; - = no changes.

Group IV—intramuscular injections of 10 and 15 mg. of hydrocortisone every 6 hours.

Group V—intravenous injections of 1–1.5 g. of 30 per cent urea in invert glucose solution/kg. of body weight.

Group VI—25–50 ml. of hydrocortisone solution in 10 ml. diluent (sodium bicarbonate) instilled into the lungs.

In groups I, II, III and IV, 3 cats each were examined, in groups V and VI 6 cats each.

All experiments were carried out under general anesthesia (ethyl chloride and ether), until the animals were sacrificed and thoracotomy was performed. The organs of the thorax were examined macroscopically and preserved in 10 per cent formaline. Two to three sections from each lung and one section from the trachea were examined microscopically. Sections were stained with hematoxylin and eosin.

Results

The first series of experiments gave evidence that the most severe lesions occur 48 hours following the instillation of 5 ml. 0.1N HCl into the tracheobronchial tree. There appeared extensive exudates, aggregation of a large number of neutrophils and hemolyzed red blood cells, necrotizing lesions of the respiratory epithelium and subsequent rupture of the interalveolar septa.

The second group of this series of experiments comprised the animals which had the aforementioned liquids instilled into the tracheobronchial tree, without previous administration of hydrochloric acid. No macroscopic or microscopical lesions were found in the lungs after 48 hours. Thus 48 hours following the instillation of HCl was established as a basis for further investigations. In order to

test the effect of the drugs employed, the amount of HCl was doubled.

The results of the second series of experiments following the administration of hydrochloric acid and subsequent treatment are listed in table I. The table shows the microscopical data, with consideration given to presence or absence of suppuration, necrotizing lesions of the alveolar septa and vascular walls, development of hemorrhagic lesions and sloughing of the bronchial epithelium. Intensity of the observed changes is represented by the symbols +++ for very extensive lesions, ++ for extensive and + for slight changes. Attention was likewise paid to the macroscopical changes. The degree of change is shown in percentages, 50 per cent representing damage equivalent to destruction of one lung.

The lungs in group I which first had 0.1N HCl and then saline instilled into the tracheo-bronchial tree, showed marked necrotizing changes with extensive hemorrhagic lesions, fairly distinct suppuration and slight edematous changes. Group II which had distilled water, and group III which had 1.3 per cent sodium bicarbonate solution instilled, revealed macro-

scopical and microscopical changes similar to those in group I, with slight individual differences in the edematous and suppurative changes. Extensive necrotizing changes and numerous hemorrhagic lesions were found in all animals in groups I, II and III (figs. 1 and 2).

In group IV which received no instillations but had been given intramuscular injections of hydrocortisone, the macroscopical and microscopical changes were on the whole similar to those in the former groups. However, neither suppurative exudates nor necrotizing or hemorrhagic lesions were found; but there were more pronounced edematous changes. The macroscopical changes in group V, which had received intravenous injections of urea, were on the whole extensive. The microscopical changes showed marked edema and sloughing of the bronchial epithelium, with insignificant necrotizing and hemorrhagic lesions. The suppurative lesions in this group were nonuniform, ranging from none to very pronounced (fig. 3).

The morphologic picture in group VI (figs. 4 and 5), which had hydrocortisone instilled

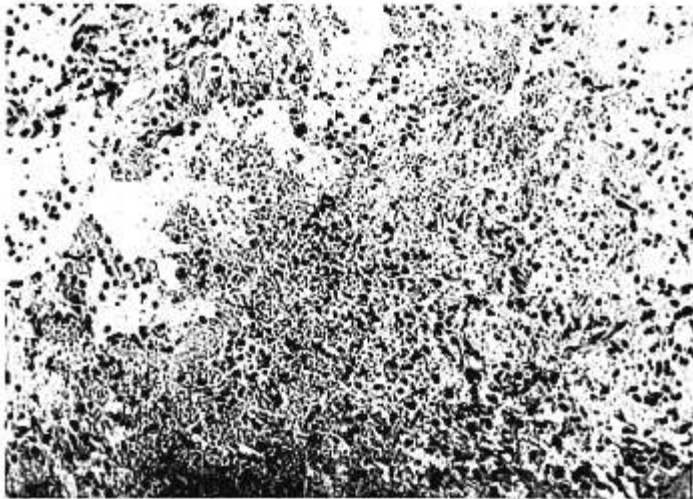


Fig. 1. Necrotizing pneumonitis 48 hours following instillation of HCl and 1.3 per cent sodium bicarbonate solution. From $\times 150$ (H and E).

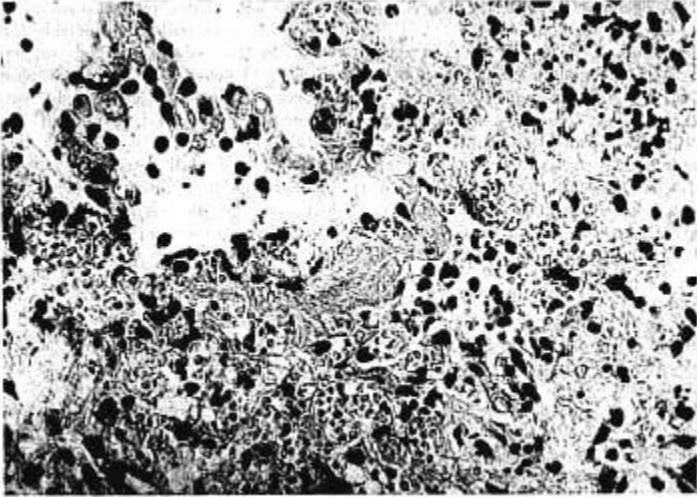


FIG. 2. Necrotizing pneumonitis. Data as in figure 1. From $\times 450$ (H and E).

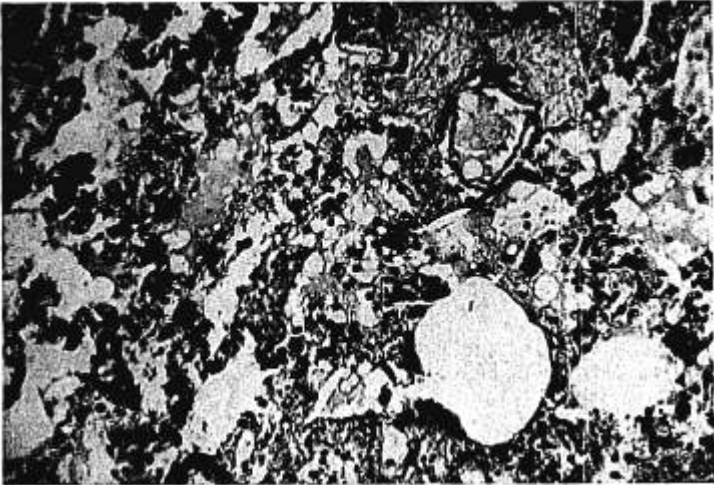


FIG. 3. Lung damage 48 hours following instillation of HCl and subsequent intravenous administration of urea. From $\times 150$ (H and E).

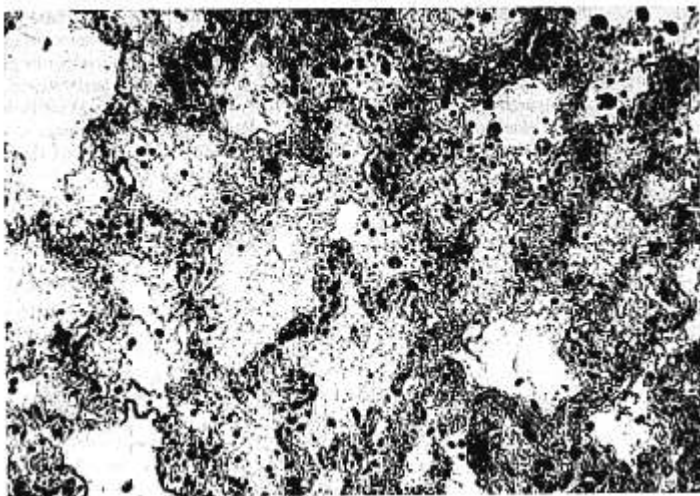


FIG. 4. Lungs 48 hours following instillation of HCl and hydrocortisone solution. From $\times 150$ (H and E).

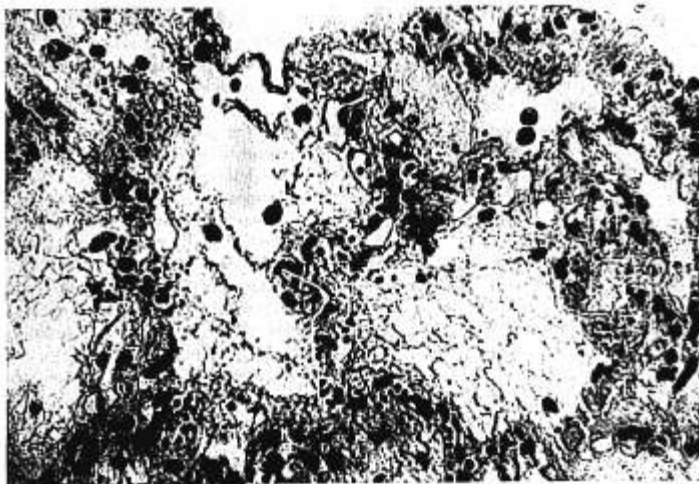


FIG. 5. Lung 48 hours after instillation of HCl and hydrocortisone. From $\times 450$ (H and E).

into the lungs, differed fundamentally from that in all other experimental groups. On gross inspection no lesions were found, or only small areas in the form of thinly disseminated infiltrative foci in the parenchyma. The microscopical picture was close to normal; there were only a few infiltrative foci with necrotizing or hemorrhagic lesions. Moderate edematous changes and sloughed bronchial epithelium were found in all cases in this group. Suppuration was not found in any of them.

The results of the experiments summarized in table 1 show a striking difference in group VI from the other groups, and a different morphologic response in group V. It appears that intravenous injection of urea changed the morphologic response in experimental pneumonitis, intensifying exudation and decreasing the necrotizing and hemorrhagic lesions, while hydrocortisone instilled into the tracheobronchial tree almost entirely inhibited the inflammatory response of the lungs to the irritating action of hydrochloric acid. Thus the most effective inhibiting action was produced in cats by the instillation of hydrocortisone into the tracheobronchial tree.

Discussion

Mendelson¹⁴ reported in his original work that the instillation into the tracheobronchial tree of neutralized liquid vomitus or HCl solution with a pH above 2.5,¹⁷ did not produce inflammatory changes characteristic of chemical pneumonitis. These observations led investigators^{2, 4, 5, 8, 12, 16, 18} to instill neutralizing drugs into the tracheobronchial tree in the therapy of aspiration pneumonitis. Simonstad, Calway and MacLean¹ reported that the instillation of large amounts of normal saline into the tracheobronchial tree was well tolerated by dogs, with, however, a marked decrease in the compliance of the lungs.¹ The same authors stressed the inefficacy of instillation of 0.5 per cent sodium bicarbonate solution, oxygenated water or distilled water into the tracheobronchial tree. Infusion of these solutions into the trachea before treatment with hydrochloric acid was found, in addition to inhibit inflammatory changes. These observations were based solely on the clinical picture, as no pathological investigations were carried out.

Bannister and his associates³ whose investigations were based on anatomico-pathologic examinations, supplied evidence that there was no effects or only minimal improvement produced by instillation of saline, sodium bicarbonate solution or other diluents into the lungs after regurgitation. The fact that large amounts of liquid instilled into the tracheobronchial tree caused changes over greater areas of the bronchial epithelium, showed that diluents not only do not neutralize hydrochloric acid but cause further spread to unaffected areas. This observation is supported by the present investigations performed in the three control groups (I, II, III).

The mechanism of spread of the lesions following HCl instillation into the tracheobronchial tree requires a somewhat different explanation. The rapidity with which HCl, in consequence of a chemical reaction, produces inflammatory and necrotizing changes in the respiratory pathways is so great that subsequent instillation of neutralization or diluting solutions is not capable of preventing the development of these lesions. The instilled liquid produces a mechanical block of already anoxic areas of the lung tissue, thus provoking atelectasis and secondary inflammatory changes. This explanation differs from Bannister's view that HCl, when mixed with the liquids used for instillation, causes spread of hydrochloric acid to additional areas of the pulmonary parenchyma. It can be preserved, based on the present experiments, that it is the amount of the instilled liquid that plays a decisive role here.

The latter view is supported by the fact that extensive exudates in the surrounding lung tissue, besides focal necrotizing inflammatory changes typical of chemical pneumonitis, were found after the instillation of the aforementioned liquids into the tracheobronchial tree. It seems, therefore, in cases of aspiration of liquid material into the lungs that the fracture of instillation of the aforementioned solutions should be limited, if not entirely abandoned.

Clinical and experimental investigations have revealed an anti-inflammatory action of intramuscular and intravenous injections of adrenocortical steroids.^{1, 3, 4, 6-9, 12, 13} It may be assumed that the subsequent intramuscular or intravenous administration of hydrocortisone is

not capable of preventing damage to the respiratory tract and inflammatory lesions in cases of aspiration of acid secretions having a pH less than 2.5 and in the presence of a rapidly developing local chemical reaction. The results of Bannister⁸ and his associates showed that the inflammatory lesions (macroscopical and microscopical) in the lungs were considerably less intense in animals which had received prophylactic intramuscular injections of 25-50 mg. of hydrocortisone. Bannister⁸ and his associates found similar results in a group of animals which had received intravenous injections of hydrocortisone with penicillin and streptomycin.

An advantageous action of intramuscular hydrocortisone injections was confirmed by the present experiments. An exact histological analysis of group IV shows, however, that the effects are not quite satisfactory. In consideration of this, it was decided to examine the local action of hydrocortisone solution administered into the trachea in 10 ml. of sodium bicarbonate diluent (group VI). The purpose of this experiment was to produce a more rapid action on the damaged areas and to cause a more efficient absorption of the hydrocortisone solution into the still well-vascularized pulmonary tissue than is produced by intramuscular and/or intravenous injections. The results in experiments performed on 3 cats after instillation of hydrocortisone were so decisive that the experiment was repeated on others. The results again confirmed the assumption that the instillation of hydrocortisone solution into the tracheobronchial tree largely prevents the macroscopical and microscopical changes typical of the chemical pneumonitis.

Johnson's report¹⁰ on an advantageous action of urea in pulmonary edema following regurgitation was checked in another of our experiments which brought forth evidence that urea produces changes in the morphologic reaction in the lungs in the form of intensified exudates and decreased necrotizing and hemorrhagic lesions, without, however, producing as pronounced an improvement as that brought about by hydrocortisone solution instilled into the tracheobronchial tree. It seems therefore that urea should not play a part in the treatment of chemical pneumonitis, as suggested by Johnson.

It is concluded therefore that an appropriate treatment of the aspiration syndrome consists in the instillation of highly concentrated hydrocortisone in a small quantity of diluent into the tracheobronchial tree, with supporting intramuscular or intravenous injections of that drug in the postoperative period. Simultaneous administration of antibiotics may prevent secondary changes of bacterial origin. Although experiments have shown that hydrocortisone instillations are undoubtedly of value, they cannot be regarded as a definitive answer to the problem of chemical pneumonitis. There still remains the unsolved problem of prevention of vomiting or regurgitation, and treatment of the bronchospastic reflexes which play a considerable part in the pathogenesis of the aspiration syndrome.

Conclusion and Summary

Intrabronchial instillation of 5 to 20 ml. of 0.1N HCl solution produced chemical pneumonitis in cats; the most pronounced changes occurred after 48 hours. Instillation into the tracheobronchial tree of normal saline, distilled water, 1.3 per cent sodium bicarbonate solution or hydrocortisone solution did not produce inflammatory changes in the lungs. Instillation into the tracheobronchial tree of saline, distilled water and 1.3 per cent sodium bicarbonate solution following instillation into the tracheobronchial tree of 10 ml. 0.1N hydrochloric acid, did not prevent pneumonitis. Instillation into the tracheobronchial tree of hydrocortisone solution provided the most effective inhibitory action on the development of inflammatory changes in chemical pneumonitis. Intramuscular hydrocortisone injections decreased the extent of lesions in chemical pneumonitis without, however, changing the type of inflammatory response. Intravenous urea prevented necrotizing lesions in the lungs, but markedly increased the edematous reaction.

References

1. Allbritten, F. F., Jr.: Pulmonary problems and anesthesia, *Surg. Gynec. Obstet.* 116: 153, 1963.
2. Adriani, J., and Berson, W.: Aspiration during anesthesia and surgery, *Amer. Surg.* 20: 568, 1954.

3. Bannister, W. K., Sattilaro, A. J., and Oris, R. O.: Therapeutic aspects of aspiration pneumonitis in experimental animals, *ANESTHESIOLOGY* 22: 440, 1961.
4. Bannister, W. K., and Sattilaro, A. J.: Vomiting and aspiration during anesthesia, *ANESTHESIOLOGY* 23: 251, 1962.
5. Dam, W. H.: Personal communication.
6. Dines, D. E., Baker, W. G., and Scantland, W. A.: Aspiration pneumonitis—Mendelson's syndrome, *J.A.M.A.* 176: 229, 1961.
7. Dougherty, T. F., and Schneebeli, G. L.: The use of steroids as anti-inflammatory agents, *Ann. N. Y. Acad. Sci.* 61: 328, 1955.
8. Hamilton, W. K.: Atelectasis, pneumothorax and aspiration as postoperative complications, *ANESTHESIOLOGY* 22: 705, 1961.
9. Hausmann, W., and Lunt, R. L.: The problem of the treatment of peptic aspiration pneumonia following obstetric anesthesia, *J. Obstet. Gynec. (Brit. Emp.)* 62: 509, 1955.
10. Johnson, H.: Pulmonary aspiration of gastric acid: Mendelson's syndrome. Successful treatment with lyophilized urea and ten per cent. invert. sugar, *J.A.M.A.* 179: 900, 1962.
11. Keating, V.: *Anesthetic Accidents*, London, Lloyd-Luke, Ltd., 1956.
12. Marshall, D. M., and Gordon, R. A.: Vomiting, regurgitation and aspiration in anaesthesia I, *Canad. Anaesth. Soc. J.* 5: 274, 1958.
13. Marshall, D. M., and Gordon, R. A.: Vomiting, regurgitation and aspiration in anaesthesia II, *Canad. Anaesth. Soc. J.* 5: 438, 1958.
14. Mendelson, C. L.: Aspiration of stomach contents into the lungs during obstetric anesthesia. *Amer. J. Obstet. Gynec.* 52: 191, 1946.
15. Merrill, R. B., and Hingson, R. A.: Study of incidence of maternal mortality from aspiration of vomitus during anesthesia occurring in major obstetric hospitals in the United States, *Anesth. Analg.* 30: 121, 1951.
16. Morton, H. J. V., and Wylie, W. D.: Anaesthetic deaths due to regurgitation or vomiting, *Anaesthesia* 6: 190, 1951.
17. Teabeault, J. R.: Aspiration of gastric contents. An experimental study, *Amer. J. Path.* 28: 51, 1952.
18. Weiss, W. A.: Regurgitation and aspiration of gastric contents during inhalation anesthesia, *ANESTHESIOLOGY* 11: 102, 1950.
19. Wylie, W. D., and Churchill-Davidson, H. C.: *Anestezjologia*, P.Z.W.L., Warszawa, 1962 (Polish translation of a *Practice of Anaesthesia*. London, Lloyd-Luke, Ltd., 1960.)

ARRHYTHMIAS Direct current countershock under methohexital anesthesia abolished 92 of 101 episodes of atrial fibrillation in 86 patients. There were no serious ventricular arrhythmias in this series when synchronized energies up to 400 watt-seconds were employed. Transient supraventricular arrhythmias were not infrequent immediately after countershock, but they were not hazardous to the patient. On two occasions a slow atrioventricular nodal rhythm appeared; it was followed by recurrence of atrial fibrillation in a few hours without return to sinus node activity. The following arrhythmias were observed immediately after countershock and prior to the establishment of regular sinus rhythm: atrioventricular dissociation, 12 times; passive atrioventricular nodals rhythm, five times; atrioventricular nodal tachycardia, five times; atrial flutter or tachycardia, four times. The following disorders of rhythm were seen after countershock had established a regular sinus pacemaker: atrial extrasystoles, atrioventricular nodal extrasystoles or escapes, atrial flutter or tachycardia, atrial fibrillation, atrioventricular nodal tachycardias, and a bizarre, multifocal atrial arrhythmia. Pretreatment with quinidine was effective in reducing the incidence of arrhythmias occurring after conversion. (*Lemberg, L., and others: Arrhythmias Related to Cardioversion, Circulation* 30: 163 (August) 1964.)