

6. Kravitz, H., Elegant, L. D., Kaiser, E., and Kagan, B. M.: Methemoglobin values in premature and mature infants and children, *Amer. J. Dis. Childr.* 91: 1, 1956.
7. Nyhan, W. L., and Lampert, F.: Response of the fetus and newborn to drugs, *ANESTHESIOLOGY* 26: 487, 1965.
8. Darling, R. C., and Roughton, F. J. W.: Effect of methemoglobin on equilibrium between oxygen and hemoglobin, *Amer. J. Physiol.* 137: 56, 1942.
9. Eastman, N. J., and Hellman, L. M.: *Williams Obstetrics*, ed. 12. New York, Appleton-Century-Crofts, 1961, p. 246.
10. Hjelm, M., and Holmdahl, M. H.: Clinical chemistry of prilocaine and clinical evaluation of methaemoglobinemia induced by this agent, *Acta Anaesth. Scand., Suppl.* 16: 161, 1965.
11. Adams, J. Q., and Alexander, A. M.: Alterations in cardiovascular physiology during labor, *Obstet. Gynec.* 12: 542, 1958.
12. Hendricks, C. H., and Quilligan, E. J.: Cardiac output during labor, *Amer. J. Obstet. Gynec.* 71: 953, 1956.
13. Schlichter, J. G.: Diseases of the heart and circulatory system in pregnancy, *In: Greenhill, J. P.: Obstetrics*, ed 12. Philadelphia, W. B. Saunders Company, 1961, ch. 38, p. 511.
14. Bartels, H.: Chemical Factors Affecting Oxygen Carriage and Transfer from Maternal to Foetal Blood, Symposium on Oxygen Supply to the Human Fetus. Oxford, Blackwell Scientific Publications, 1959, p. 36.
15. Shnider, S. M.: Local anesthetics and the neonate, *New Eng. J. Med.* 274: 226, 1966.
16. Leahy, T., and Smith, R.: Notes on methemoglobin determination, *Clin. Chem.* 6: 148, 1960.
17. Poppers, P. J., Vosburg, G. J., and Finster, M.: Methemoglobinemia following epidural analgesia during labor, *Amer. J. Obstet. Gynec.* 95: 630, 1966.

### Persistent Postoperative Idionodal Hypotension Treated with Minimal Bicarbonate

JACOBUS W. MOSTERT, M.D., AND RAYMOND J. TRUNOWSKI, M.D.\*

A wandering pacemaker is very common during anesthesia and idionodal rhythm is frequently encountered. Under these circumstances it is usually evanescent and requires no treatment. This report describes the successful use of sodium bicarbonate in correcting postoperative idionodal rhythm associated with hypotension and resistant to treatment with numerous antiarrhythmic drugs.

#### CASE REPORT

A 69 year old man without clinical or ECG (preoperative) evidence of heart disease underwent a radical neck dissection for recurring cancer under controlled hypotension. Cervical epidural anesthesia was induced and maintained with intermittent doses of 2 per cent lignocaine; a total of 40 ml. being given over a three and a half hour period. The regional anesthesia was supplemented with fractional doses of thiopental totaling 500 mg. with nitrous oxide, and the trachea was intu-

bated after the intravenous injection of Demerol and Scopolamine. During and after anesthesia ECG recordings were made from an esophageal electrode. A plastic cannula was introduced into the superior vena cava through a brachial vein and all the drugs mentioned below administered through it. Central venous pressure (CVP) was monitored by means of extension tubing attached to a manometer and a three-way stop-cock.

At the end of the second hour of anesthesia a few premature ventricular contractions occurred and the CVP rose from 2 cm. to 32 cm. of water. Some muscular twitching supported the impression that the blood content of lignocaine had approached a toxic level. Hypotension was subsequently maintained with the aid of pentolinium and chlorprothixene totaling 30 mg. and 12.5 mg. respectively. CVP gradually fell to 16 cm. of water. Operative time was 7 hours, measured blood loss was 700 cc. Two units of whole blood, 2 liters of Ringer's lactate solution and 1,500 ml. of 5 per cent dextrose in water was ad-

\* Department of Anesthesiology, Roswell Park Memorial Institute, Buffalo, New York.

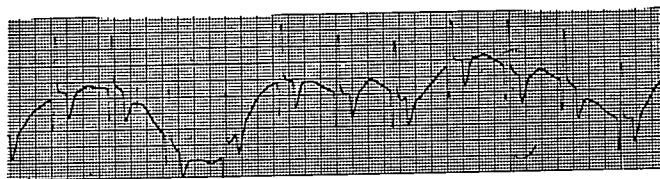


FIG. 1. Esophageal electrocardiogram following the use of metaraminol. Note the persistent idionodal rhythm and the deep and peaked T waves.

ministered in the operating room. Ninety minutes before the surgery was completed an idionodal rhythm appeared with a cardiac rate of 16 per minute. No further anesthetic drugs were used except for nitrous oxide. Oxygen was administered throughout the entire operative and postoperative period in concentrations of at least 50 per cent either by anesthetic gas machine or nasopharyngeal catheter. Systolic blood pressure, however, remained at 75 mm. of mercury. Atropine, 0.6 mg., had no immediate effect on the heart rate or blood pressure and after 20 minutes the heart rate remained slow (32/min.). Metaraminol (5 mg.) was given for its beta-adrenergic-stimulating effect and resulted in a gradual increase of the pulse rate which stabilized at 78 per minute with persistent idionodal rhythm, transient doubling of the amplitude of the negative T waves (fig. 1), a CVP of 22 cm. of water and a blood pressure of 220/120 mm. of mercury. The blood pressure returned to 80/55 mm. of mercury, the T waves assumed their normal size. Heart rate returned to 32 per minute 20 minutes after the metaraminol was given. Propranolol,

5 mg., was then given. This drug raised the pulse rate and caused many atrial premature contractions as illustrated in the top tracing of figure 1. We then repeated the 5 mg. metaraminol 20 minutes after the propranolol injection, and the blood pressure at this time did not exceed 110/80 mm. of mercury returning to 90/70 mm. of mercury within 15 minutes. The nodal rhythm was also unaffected by 0.2 mg. isoproterenol, 50 mg. ephedrine and 250 mg. aminophyllin.

Two hours postoperatively, and thirty minutes after the last drug administration the blood pressure was 90/50 in association with the idionodal rhythm at 79 beats per minute. Because we were confident that blood loss was replaced and hydration adequately maintained during surgery<sup>2</sup> (table 1), we decided to treat the slight metabolic acidosis (table 2). Sodium bicarbonate, 44.6 mEq. (17 mEq./kg.), was rapidly administered. P waves immediately appeared in a recurring pattern of three different complexes. In the first com-

\* Ideral (AY-64043) was provided by Alex Sahagian-Edwards, M.D., Assistant Medical Director, Ayerst Laboratories.

TABLE 1. Hematoerit of Arterial Blood

	Percentage
1. Before Ringer's lactate infusion	42
2. After Ringer's lactate infusion	35
3. Prior to blood transfusion	37
4. After first unit of blood	38.5
5. After second unit of blood	40.5
6. On discharge from Recovery Room	41

TABLE 2. Acid-base Values of Brachial Artery Blood Using the Astrup Method

Unit	Before Administration of Sodium Bicarbonate	After Administration of 44.6 mEq. of Sodium Bicarbonate
pH	7.415	7.57
Pco <sub>2</sub>	26.5	32.0
Base excess	-5.4	+3.3
Buffer base	44.7	40.0
Standard bicarbonate	30.0	27.0
Actual bicarbonate	19.2	27.5
Total CO <sub>2</sub>	20.0	27.6

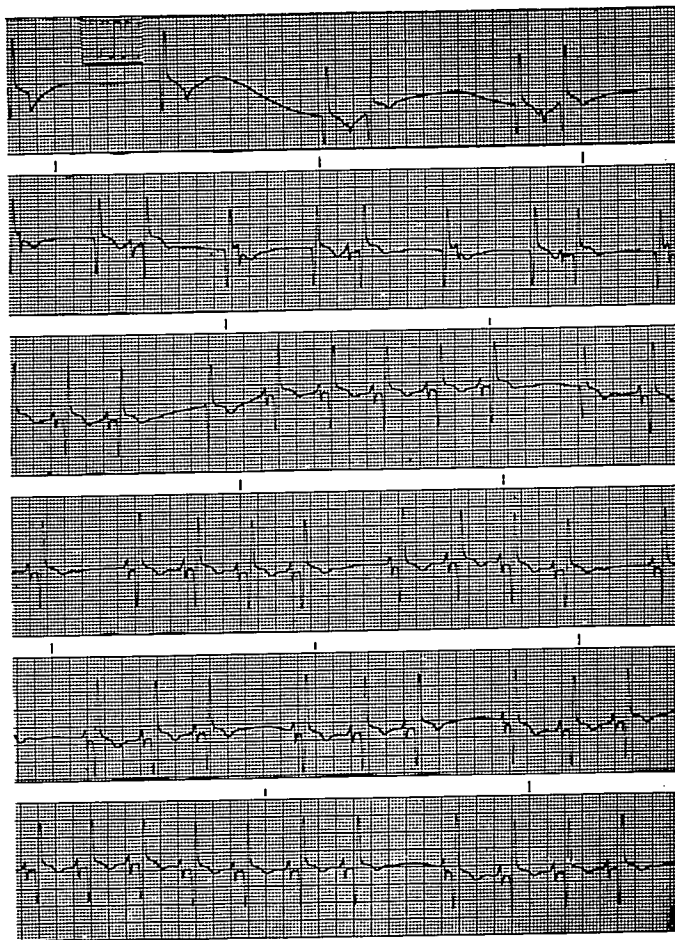


FIG. 2. Esophageal electrocardiograms showing atrial premature beats after propranolol (Inderal). The correction of persistent idionodal rhythm by sodium bicarbonate is illustrated in the second through sixth tracings.

plex the P wave immediately followed the R wave, the second was idionodal and the third occurred normally as a sinus complex (fig. 2, second tracing from top). This rhythm continued for one minute after which there were two episodes of pacemaker arrest (fig. 2, third tracing from top). During the next minute pacemaker failure occurred once after every four normal cycles (fig. 2, fourth tracing from top) and after three normal cycles (fig. 2, fifth tracing). Thirty seconds later there was a normal electrocardiogram except for two more episodes of pacemaker failure as illustrated in the bottom tracing. The pH was 7.57 (table 2), the heart rate was 100 beats per minute, the CVP 11 cm. of water and the blood pressure 160/80 mm. of mercury. Frequent postoperative examinations confirmed that the patient had an uneventful recovery without any further episodes of hypotension or arrhythmias.

#### COMMENT

A case is reported of idionodal rhythm. The arrhythmia was associated with persistent bradycardia and hypotension following controlled hypotensive anesthesia which included the possibility of lignocaine toxicity. The idionodal rhythm, persistent bradycardia and associated hypotension unresponsive to atro-

pine, metaraminol, propranolol, isoproterenol, ephedrine and aminophyllin were apparently corrected with 44.6 milliequivalents of sodium bicarbonate in the presence of an arterial pH of 7.415 prior to the bicarbonate administration. Arterial pH rose to 7.57 five minutes after the bicarbonate was injected. This situation in this case is worthy of note because Reid *et al.*<sup>1</sup> found no electrocardiographic alterations which they could ascribe to changes in pH in the induced range of 7.30 to 7.64. While electrocardiographic abnormalities may not be experimentally induced by minor variations in pH, the corollary, however, does not seem to hold true. In our experience we have frequently been able to correct arrhythmias, particularly those found in association with halothane and cyclopropane, with a small dose of sodium bicarbonate. A slight variation in pH toward alkalinity clearly corrected the arrhythmia and associated hemodynamic disturbance in the reported case.

#### REFERENCES

1. Reid, J. A., Enson, Y., Harvey, R. M., and Ferrer, M. I.: The effect of variations in blood pH upon the electrocardiogram in man, *Circulation* 31: 369, 1965.
2. Trudnowski, R.: Hydration with Ringer's lactate solution. Its effectiveness in maintaining stable circulation during and after surgery, *J.A.M.A.* 195: 545, 1966.

## Exaggerated Spread of Epidural Block

RAY J. DEFALQUE, M.D.\*

A 69 year old man (5 feet 11 inches and 199 pounds) was to undergo Knowles pin insertion for a five day old right femoral neck fracture. Abnormal preoperative findings included blood pressure 160/75 mm. of mercury, pulse 100/minute, temperature 100° F., rales in both pulmonary bases and blood urea nitrogen 40 mg./100 ml. He had also been treated for severe thoraco-lumbar degenerative arthrospondylitis, paralysis agitans, obstructive pulmonary emphysema, essential hy-

pertension, and mild hemiparesis following a recent cerebral hemorrhage.

Two hours after premedication with mep- eridine 50 mg. and scopolamine 0.2 mg. intramuscularly, and five minutes after meth- oxamine 20 mg. intramuscularly, the patient was placed in the left lateral position. Although meaningful flexion of his back was impossible, a 17 G Tuohy-Huber needle was inserted with little difficulty in the T 12-L 1 interspace. The peridural space was easily identified by the loss of resistance to injection technique. After aspiration, 5 ml. of lidocaine

\* Indiana University Medical Center, Indian- apolis, Indiana.