

Questioning of the patient failed to uncover any history of laryngeal symptoms. The laryngeal band was later excised under local anesthesia, at which time the photograph (fig. 1) was obtained.

DISCUSSION

This case is presented because of the interesting difficulties encountered with intubation, and because of the possible relationship between the laryngeal band and previous prolonged mechanical ventilation via a nasotracheal tube. Whether or not the endotracheal tube caused the formation of the laryngeal band is conjectural, but the past anesthetic history strongly suggests a causal relationship.

Although many reports have related contact granulomata to endotracheal intubation,^{1,2} laryngeal band has not been described previ-

ously as a sequel of intubation. It possibly represents a variant of laryngeal web formation, as described by Young and Stewart,³ who postulated the sequence of events as being: initial abrasion or hematoma, followed by infection, ulceration and granulation, with ultimate organization to a nodule or web cicatrix. Continued movement of the tube, and especially the cuff, against the sub-glottic mucosa, could have initiated this sequence in this case.

REFERENCES

1. Jackson, C.: Contact ulcer granuloma and other laryngeal complications of endotracheal anesthesia, *ANESTHESIOLOGY* 14: 425, 1953.
2. Gillespie, N. H.: Endotracheal anesthesia, ed. 3. Madison, The University of Wisconsin Press, 1963.
3. Young, N., and Stewart, S. Laryngeal lesions following endotracheal anesthesia: a report of 12 adult cases, *Brit. J. Anaesth.* 25: 32, 1953.

Succinylcholine Danger in the Burned Patient

JOHN D. TOLMIE, M.D., THOMAS H. JOYCE, M.D., GEORGE D. MITCHELL, M.D.*

Interest continues in cardiac arrest during anesthesia in the severely burned patient. Previously reported cases, and the present case have many things in common; debilitation, anxiety, multiple uneventful anesthetic administrations followed by one or more episodes of cardiac arrest occurring at least twenty-one days post-burn. This cardiac phenomenon has been ascribed to vagal stimulation associated with intubation, effects of succinylcholine on vagal ganglia, depleted levels of pseudocholesterase, fluid depletion, acidosis, anesthetic overdose, and potassium efflux.¹⁻³ Although all of these may play a part, the latter is probably the major factor in this case and deserves further consideration. Effort was made to

alter the anesthetic technique by only one variable on each occasion in an effort to identify the specific mechanism of the arrest.

CASE REPORT

In South Viet Nam, a 19 year old Marine sustained a bullet wound to his left thigh. This exploded a phosphorous grenade in his hip pocket resulting in a compound, comminuted fracture of his left femur, massive soft tissue destruction of his left buttock and 35 per cent third degree burns involving legs, back and occiput. Within four hours, he received 4,500 ml. of whole blood, massive debridement was carried out, a Steinmann pin inserted and the first of many halothane-nitrous oxide-oxygen, endotracheal anesthetics administered. During the next 26 days (from the Philippines to Philadelphia) he had 10 uneventful anesthetics for dressing changes or debridement; one consisted of thiopental-ni-

* Department of Anesthesiology, U. S. Naval Hospital, Philadelphia, Pennsylvania. The opinions expressed in this paper are those of the authors and do not necessarily reflect the views of the Bureau of Medicine and Surgery, U. S. Navy, or the Naval Service at large.




FIG. 1 A. Serum potassium after intravenous injection of 60 mg. succinylcholine (curve A), 40 mg. succinylcholine (curve B), 40 mg. succinylcholine (curve C), and 100 mg. gallamine (curve D).

trous oxide-oxygen-succinylcholine drip, while the remainder were halothane-nitrous oxide-oxygen with thiopental for induction and 30 to 80 mg. of succinylcholine intravenously to facilitate intubation.

On the thirty-first post-burn day, without premedication (which was omitted because of a temperature of 100.8° F. and a pulse rate of 120 per minute), the eleventh anesthetic consisted of induction with 160 mg. thiopental, 3 liters/minute nitrous oxide, 2 liters/minute oxygen and 60 mg. succinylcholine intravenously, with rapid, easy intubation. Within four minutes of succinylcholine administration and intubation, pallor, cyanosis, diaphoresis, and imperceptible pulse and blood pressure were noted. Cardiac arrest was diagnosed and treated with external cardiac massage, withdrawal of anesthetic agents and intravenous sodium bicarbonate. In three minutes, pulse and blood pressure returned to 100/50 and 120/minute, and the redressing procedure was completed uneventfully during nitrous oxide-halothane anesthesia. Postoperatively no adverse neurological or electrocardiographic abnormalities developed.

Five days later, again without premedication or thiopental for induction, anesthesia was carried out as before. Preoperative arterial blood gases were P_{CO_2} —35; P_{O_2} —84, and pH of the blood was 7.4. Following the injection of 60 mg. of succinylcholine intravenously, the electrocardiogram, lead 2, showed progres-

sive decrease of voltage with widening of the QRS complex, tall peaked T-waves with widening and disappearance of the P-wave, then ventricular fibrillation. External cardiac massage and 44.5 mEq. sodium bicarbonate intravenously, restored pulse to 120/minute and blood pressure to 140/80 within two minutes. Again the patient showed no ill effects post-operatively.

On the fortieth post-burn day, four days after the previous procedure, he was anesthetized as before, except that transtracheal injection of 4 ml., 2 per cent lidocaine was completed prior to intubation. Once more ventricular fibrillation was noted both clinically and on the electrocardiogram about four minutes after succinylcholine administration. This time he was resuscitated within thirty seconds by only 10 compressions of his precordium followed by 44.5 mEq. sodium bicarbonate. Just prior to arrest, blood samples were taken for serum electrolytes. Halothane and nitrous oxide were reinstated and the dressing change completed without incident.

Five days later, during his fifteenth anesthetic, which was conducted similar to his fourteenth, no actual arrest occurred. But, marked ECG changes similar to those already described, leading to nine seconds of ventricular tachycardia, were recorded (fig. 1). Serial blood samples were drawn following the succinylcholine injection for electrolyte analysis. A repeat dose of 40 mg. succinylcholine toward the end of this anesthetic again elicited electrocardiographic changes but of a lesser degree. The skin grafting was completed uneventfully.

On the fiftieth post-burn day nitrous oxide-oxygen-halothane anesthesia was administered following premedication with 0.4 mg. atropine one hour preinduction. Only 40 mg. of succinylcholine was given but no attempt was made at intubation. Blood samples were taken. ECG changes developed similar to those seen previously noted but with no ventricular arrhythmias. Once the ECG had returned to control pattern, 100 mg. gallamine was injected intravenously and again blood samples were drawn and ECG recorded as intubation was accomplished without incident. At present the patient has shown steady im-

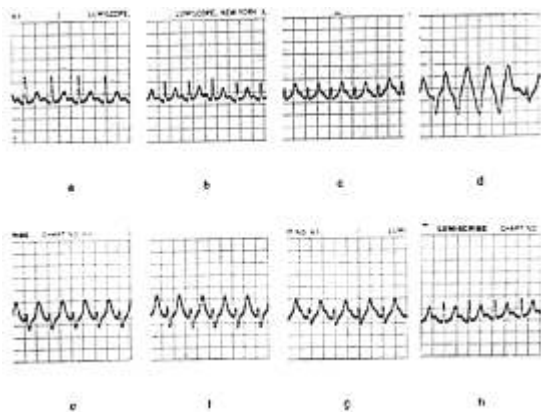


FIG. 1 B. Small letters identify electrocardiogram strips showing progressive hyperkalemia at each point on curve A.

provement with no ill effects from his arrest periods.

His medications during this period were Chloroquine 0.5 g. and Primaquine 45 mg. weekly, vitamins daily, sodium oxacillin (Prostaphlin) replaced by sodium nafcillin (Unipen) on the thirty-sixth post-burn day and cephalothin (Keflin) for two weeks prior to the first episode of arrest.

COMMENT

The effects of poor nutrition, stress, and infection on the physiology of the burned patients must be profound. Clinically these effects are evident only in "gross" parameters such as persistent tachycardia, weight loss, excessive anxiety and unexpected responses to medications like succinylcholine. In regard to cardiac arrest some reports suggest that succinylcholine is not a factor and point to vagal activity as the cause of arrest.¹ We attempted vagal stimulation in this patient by carotid massage, eyeball pressure and endotracheal tube movement following cardiac resuscitation and at no time could we duplicate the clinical or ECG effects obtained following succinylcholine. Another argument against a prime vagal cause is the fact that we observed the pre-arrest ECG following succinylcholine prior to any attempted intubation. In addition,

our patient and others like him showed no vagal bradycardia before arrest even in a totally unatropinized state.²

It is difficult to indict pseudocholinesterase depletion in this entity. Bush has shown the lowest levels are at fourteen days post-burn whereas three weeks seems to be the beginning of the danger period for succinylcholine administration.⁶ Also one would expect to see other effects of lowered pseudocholinesterase such as prolonged apnea. We saw no evidence of this, nor have others reported it.

Certainly, early in the burn patient's course body fluid dynamics are abnormal and the required time for readjustment is uncertain. Debilitation with hypovolemia may be present but debilitated non-burn patients are regularly anesthetized without these ECG changes. If hypovolemia were the cause of the cardiac arrests in our patient, it is notable that he was so readily revived without much fluid and that subsequent management was uneventful without the use of fluids or vasopressors. Hence we are forced to reject the idea that hypovolemia is the prime cause of cardiac arrest in burn patients at this stage of their illness. The acidosis common to many burn patients has been implicated as contributing to abnormal myocardial responses to electrolytes. This may be true when it exists, but our patient was in

respiratory alkalosis just prior to the second procedure in which he had a cardiac arrest. However, the part played by other factors, such as his anti-malarial therapy are uncertain. Certainly thiopental degradation does not seem to be a factor in the development of cardiac arrest.

We believe we have excluded most of the common explanations for this type of cardiac arrest except for transient hyperkalemia. The idea of an efflux of potassium ion associated with succinylcholine administration is not new and has been shown in cat hind limbs by Paton.⁷ In essence we have demonstrated what Allan, Cullen and Gillies postulated; that there is an appreciable rise in serum potassium, associated with concurrent ECG evidence of hyperkalemia following intravenous succinylcholine in the three week post-burn patient⁵ (fig. 1). The most likely mechanism of the arrest reported here was hyperkalemic arrhythmias and cardiac atony. This is substantiated by the fact that as long as the potassium level remained below 6.5 mEq./liter no arrhythmias occurred.⁵ An atonic flabby myocardium was noted upon opening the chest for massage in several reported cases.^{1,5} The source of this potassium is most likely skeletal muscle, for as was shown by Paton, succinylcholine elicited hyperkalemia in hepatectomized dogs, in which epinephrine stimulated potassium release from liver could not have occurred.⁷ As Dripps has suggested, muscle contraction is presumably the major source of potassium ion concentration in the plasma.⁹ Interestingly, our patient's muscles did not fasciculate on receiving succinylcholine. Perhaps there is an alteration in the burn patient's metabolism that retards the normally rapid reflux of potassium ions back into the muscle cell.

In the reported experience the effect of succinylcholine seemed to be dose related, in that with 40 mg. we saw T-wave peaking with loss of QRS voltage but no progression to ventricular tachycardia, as was noted with 60 mg. However, rather than recommend smaller doses of succinylcholine it would seem more advisable to use gallamine to facilitate intubation on the post-burn patient for we could demonstrate none of the adverse succinylcholine-like effects with its use.

REFERENCES

1. Fleming, W. B., Hueston, J. T., Stubble, J. L., and Villiers, J. D.: Two episodes of cardiac arrest in one week, *Brit. Med. J.* 5167: 157, 1960.
2. Finer, B. L., and Nylen, B. O.: Double cardiac arrest with survival, *Brit. Med. J.* 5122: 624, 1959.
3. Bush, G. H., Graham, H. A. P., Littlewood, A. H. M., and Scott, L. B.: Danger of suxamethonium and endotracheal intubation in anesthesia for burns, *Brit. Med. J.* 5312: 1081, 1962.
4. Lowenstein, E.: Succinylcholine administration in the burned patient, *ANESTHESIOLOGY* 27: 494, 1966.
5. Allan, C. M., Cullen, W. G., and Gillies, D. M. M.: Ventricular fibrillation in a burned boy, *Canad. Med. Ass. J.* 85: 432, 1961.
6. Bush, G. H.: The use of muscle relaxants in burnt children, *Anaesthesia* 19: 231, 1964.
7. Paton, W. D. M.: Mode of action of neuromuscular blocking agents, *Brit. J. Anaesth.* 28: 470, 1956.
8. Friedberg, C. K.: *Diseases of the Heart*, ed. 2. Philadelphia, W. R. Saunders, 1962, p. 1030.
9. Williams, C. H., Deutsch, S., Linde, H. W., Bullough, J. W., and Dripps, R. D.: Effects of intravenously administered succinylcholine on cardiac rate rhythm and arterial blood pressure in anesthetized man, *ANESTHESIOLOGY* 22: 947, 1961.