

will appear less efficient because of cooling. For anesthetics as soluble as methoxyflurane it is difficult to achieve an effective alveolar concentration with inspired concentrations much lower than 3 per cent. This question has been examined in detail by Eger,⁶ who demonstrated the need for high inflow rates and high concentrations during induction of methoxyflurane anesthesia with an out-of-circuit vaporizer.

The output concentration of anesthetic depended more on the position of the hood than on the flow rate of carrier gas. However, at low flows (less than 2 l/min) the diversion through the hole in the hood caused a noticeable fall in the output concentration (fig. 2).

Though imprecise, the whole range of possible concentrations can be achieved by changing the position of the hood. Using intermediate positions of the lever complicated attempts to control the concentrations and, in some circumstances, caused increases in output when decreases were anticipated. The explanation is that with the hood submerged the hydrostatic resistance to flow causes some gases to bypass the jar. Removal of the hood from the liquid facilitates gas flow through the jar and concentrations may rise. Since the graduations for the lever serve no useful purpose, the ar-

angement might be better served by a spring-loaded mechanism designed for either the "on" or the "off" mode.

While the foregoing discussion could relate *in principle* to any volatile anesthetic, absolute concentrations of certain other vapors (notably halothane) could reach potentially dangerous levels, as may be predicted from their vapor pressure and potency.

The author is grateful to Dr. W. W. Mapleson and Dr. T. C. Smith for their suggestions and encouragement.

REFERENCES

1. Macintosh, R. R., and Mushin, W. W.: *Physics for the Anaesthetist*. Oxford, Blackwell Scientific Publications, 1963, p. 279.
2. Epstein, H. G.: Principles of inhalers for volatile anaesthetics, *Brit. Med. Bull.* 14: 18, 1958.
3. Lowe, H. J.: Flame ionization detection of volatile organic anesthetics in blood, gas, and tissues, *ANESTHESIOLOGY* 25: 808, 1964.
4. Mapleson, W. W.: Trichlorethylene concentration from a "Boyle" type anaesthetic apparatus, *Brit. J. Anaesth.* 29: 3, 1957.
5. Takahashi, H.: Evaluation of Penthrane vaporizers, *Jap. J. Anesth.* 14: 270, 1965.
6. Eger, E. L., II: Uptake of methoxyflurane in man at constant alveolar and constant inspired concentration, *ANESTHESIOLOGY* 25: 284, 1964.

CASE REPORT

Fatal Massive Necrosis of the Liver after Repeated Exposure to Methoxyflurane

MARIO STEFANINI, M.D.,* ALEXANDER HERLAND, M.D.,†
EUGENE P. KOSYAK, M.D.†

Hepatotoxic effects following the use of methoxyflurane (Penthrane) are rare.¹ A case of acute hepatitis after a second administration of methoxyflurane has been reported by Klein

and Jeffries.² Their patient developed hepatocellular necrosis with jaundice, but ultimately recovered. These authors also refer to two other cases of fatal atrophy of the liver following the use of methoxyflurane. In the present report we discuss a case of fatal massive necrosis of the liver which followed a second administration of methoxyflurane and may have resulted from acquired hypersensitivity to the drug.

* Pathologist, Saint Elizabeth Hospital.

† Staff member, Hoopeston Community Memorial Hospital.

Received from the Department of Surgery, Hoopeston Community Memorial Hospital, and the Department of Pathology, Saint Elizabeth Hospital, Danville, Illinois.

TABLE 1. Summary of Medications and Results of Laboratory Tests

	Dilation and Curettage		Hysterectomy		Jaundice			
	3/29	4/24	4/25	4/26	4/27	4/28	4/29	4/30
Demerol, 100 mg	+		+	+++				
Succinylcholine, 80 mg								
Atropine, 6.5 mg	+			+	+			
Tubocurarine, 3 mg	+		++					
Seconal, 100 mg		+	+	+				
Tigan, 100 mg		++						
Gantresin, 0.5 gm		+	+					
Ampicillin, 500 mg					+	+	+	
Neomycin, 500 mg						+++++	+++++	
Solucortef, 200 mg, im					+	+	+	+
Hykinone, 10 mg						+	+	
Nitrous oxide	+							
Oxygen	+		+					
Methoxyflurane	+		+					
Serum GPT (units)	8				3,040	3,380	2,900	1,760
BUN (mg/100 ml)	11.5						4.7	2.5
Serum bilirubin								
Total (mg/100 ml)	0.4				7.8		6.9	
Direct (mg/100 ml)					4.5		4.9	
Indirect (mg/100 ml)					3.3		2.0	
Blood ammonia (mg/100 ml)						4.65	12.1	12.9
Bilirubinuria					+++		SS*	
Prothrombin time of plasma (sec)								
Hemoglobin (gm/100 ml)	12.1	12.0			11.4			
Hematocrit (per cent)	38	38						
Leukocyte count	6,700	5,900			16,700			
band forms	6	12			8			
neutrophils	38	48			75			
eosinophils	1	4			—			
basophils	—	1			—			
lymphocytes	28	28			17			
monocytes	6	7			—			

* Control, 12 sec.

CASE REPORT

A 44-year-old woman was admitted to the hospital because of urinary incontinence and unexplained uterine bleeding of a few days' duration. Physical findings were unremarkable except for cystocele and rectocele. Urinalysis, blood studies and tests (table 1) (including tests for evaluation of parenchymal hepatic function) were carried out on the day of admission; results were within normal limits. A dilatation and curettage procedure was done with the patient anesthetized with methoxyflurane and nitrous oxide. Microscopic examination of the curettings revealed focally-atypical glandular hyperplasia of the endometrium. The postoperative course was uneventful. Fever, hypertension and jaundice were not observed.

Panhysterectomy and Marshall-Marchetti suspension were carried out three weeks later. Thiopental was used for induction, 80 mg of succinylcholine given intravenously, the patient oxygenated and the trachea was intubated with a #34 endotracheal tube with cuff. Anesthesia was maintained with methoxyflurane-oxygen-nitrous oxide. Three mg *d*-tubocurarine were given for relaxation at 55 and 75 minutes after the start of the operation. Assisted respiration was used throughout. The anesthesia record indicated that the blood pressure, 110/60 mm Hg upon admission, was maintained at a level of 90/50 mm Hg dur-

ing the first two hours and at a level of 90/40 mm Hg during the last hour of the operation. Medications received prior to, during and following surgery are detailed in table 1.

Examination of the uterus confirmed the diagnosis of focally atypical endometrial glandular hyperplasia.

Occasional oozing of bright blood from the wound was noted for about 36 hours following the operation, and the patient complained of lassitude and weakness. During this interval, the blood pressure remained at 110/60 mm Hg and the urinary output averaged 75 ml/hour. Jaundice of skin and sclerae and a dark color of the urine were first noted 36 hours after operation. Simultaneously, the patient developed irritability, extreme fatigue and mental confusion; petechiae and ecchymoses of skin became evident. Studies at this time (table 1) showed elevation of GPT activity and bilirubin in serum and bilirubinuria. Over the next 96 hours the patient became deeply jaundiced and oliguric. Increased ammonia levels, prolonged plasma prothrombin time and decreased blood urea nitrogen levels were recorded. Notwithstanding treatment with Solucortef, Neomycin, Ampicillin and Hykinone (table 1), deep coma followed. Because of the critical condition of the patient, an attempted exchange blood transfusion was limited to the administration of 2,500 ml of

whole blood with withdrawal of about 1,200 ml of blood. Hypotension developed, and manifestations of bleeding became more pronounced. The patient then died.

Necropsy Findings. At postmortem examination of the unembalmed body ten hours after death, numerous petechiae and ecchymoses were present at sites of venipuncture. Skin and mucosae showed intense pallor and yellowish color; lips and nails were cyanotic. All organs, fat, mucosal and serosal surfaces were tinged by a greenish-yellow pigment and were studded with petechial hemorrhages and ecchymoses. Each pleural cavity contained approximately 50 ml of bloody fluid. The lower and middle right lobes of the lungs were reddish and contained abundant yellowish serous fluid mixed with air. The pericardial sac showed a few fibrinous patches covering areas of recent hemorrhage. The abdominal cavity contained about 150 ml of hemorrhagic fluid. Stomach, duodenum, jejunum and the upper portion of the ileum were filled with coffee-ground material and liquified blood. The biliary tree and ampulla of Vater were patent. The liver weighed 402 g and was soft and reddish yellow in color, the gallbladder empty. The vaginal stump was closed.

Histologic findings (hematoxylin and eosin stain) showed multiple petechiae and congestion of all

organs and tissues. There was deposition of yellowish pigment in most organs and of brown pigment within muscle fibers of the heart. Sections of lungs revealed focal atelectases, edema fluid and amorphous debris within the alveoli. Sections of the liver showed massive necrosis with collapse of stroma, falling-out of cells, only occasional remnants of portal triads, and a focal inflammatory response which did not involve the subcapsular spaces (fig. 1). Silver stains (fig. 2) indicated only a few surviving reticular fibers. The endothelial cells of the renal glomeruli showed swelling and the tubular cells contained greenish-yellow pigment. The lumina of renal tubules were filled with amorphous eosinophilic debris. The final anatomic diagnosis was acute massive necrosis of the liver, with multiple hemorrhages related to acute hepatic failure, and acute pulmonary edema.

DISCUSSION

Necrosis of the liver in this patient was rapid and massive. Evaluation^{3,4} of the possible pathogenesis of the massive hepatic necrosis indicated that neither overwhelming infection nor severe congestive heart failure were present in our patient. There was no clinical or laboratory evidence of pre-existing severe




FIG. 1. Section of necrotic liver stained with hematoxylin and eosin, $\times 100$ (see text).

Downloaded from <http://anesthesiology.com/> at 03:21:43Z on 05 July 2022

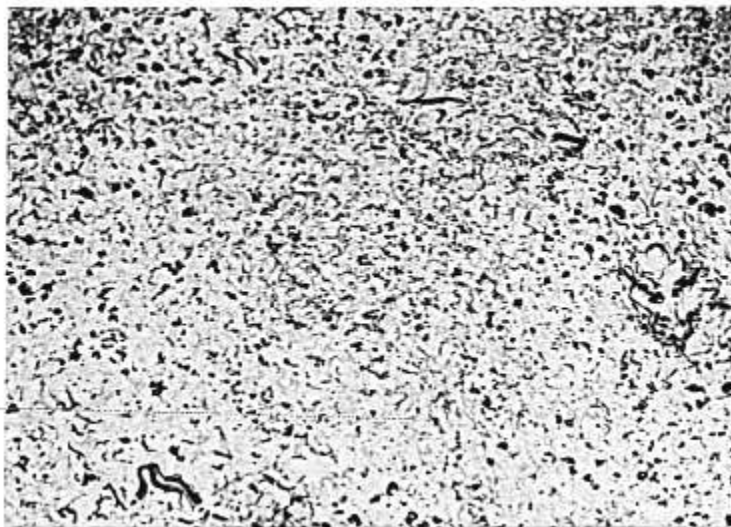


FIG. 2. Section of necrotic liver stained with silver, $\times 100$.

parenchymal hepatic disease. The role of shock seemed insignificant as indicated by operative and postoperative records and because the histologic findings were not consistent with those observed in hepatic necrosis related to prolonged and sustained hypotension.⁵ Finally, the possibility of acute infectious hepatitis was considered, especially because the histopathology of the liver in hepatic necrosis related to halothane (Fluothane)^{4,5} is similar to that encountered in infectious hepatitis. The clinical course of the patient before and after operation, however, and such histologic findings as the massive destruction of reticular fibers and the absence of subcapsular lymphocytic infiltration, made this diagnosis unlikely. Also, no cases of infectious hepatitis had been reported from the area for periods of six months preceding and following the death of our patient.

It appears at this time that halothane is capable of inducing hepatitis through a mechanism of sensitization.^{4,6-10} Either an allergic process following acquired hypersensitivity or

the development of autoimmunization with the liver as the target organ could be responsible for the acute hepatic damage following the repeated use of halothane. Because of the rarity of the event, a similar mechanism, obviously based on a highly individualized idiosyncrasy, may be responsible for the development of massive necrosis of the liver following repeated administration of methoxyflurane. In fact, the pattern of hepatic injury following the use of methoxyflurane² has characteristics which closely resemble those encountered in hypersensitivity.¹¹ Of the drugs given our patient prior to the development of jaundice, methoxyflurane was the only one administered twice and at an interval of time sufficient to allow for the development of hypersensitivity.

The authors express their appreciation to Drs. Lionel Rabin and Bruce H. Smith, Captain, MC, USN, Armed Forces Institute of Pathology, who examined the histologic sections of liver and contributed to their interpretation. Dr. Edmund Andracki of Danville, Illinois, reviewed the anesthesia record.

REFERENCES

1. van Poznak, A., and Artusio, J. F., Jr.: Anesthetic properties of a series of fluorinated compounds, *Toxic. Appl. Pharmacol.* 2: 363, 1960.
2. Klein, N. C., and Jeffries, G. H.: Hepato-toxicity after methoxyflurane administration, *J.A.M.A.* 197: 1037, 1966.
3. Dykes, M. H. M., Walzer, S. G., Slater, E. M., Gison, J. M., and Ellis, D. S.: Acute parenchymatous hepatic disease following general anesthesia: Clinical appraisal of hepato-toxicity following administration of halothane, *J.A.M.A.* 193: 339, 1965.
4. Summary of the National Halothane Study. Possible Association between Halothane Anesthesia and Postoperative Hepatic Necrosis. Subcommittee, National Halothane Study of the Committee on Anesthesia, National Academy of Sciences, 1967.
5. DeBacker, L. J., and Longnecker, D. S.: Prospective and retrospective searches for liver necrosis following halothane anesthesia, *J.A.M.A.* 195: 157, 1966.
6. Little, D. M.: Effects of halothane on hepatic function. In Greene, N. M. (ed.): *Clinical Anesthesia: Halothane*. Philadelphia, F. A. Davis, 1968, pp. 85-137.
7. Green, K. G., and Mungavin, J. M.: Halothane and the liver: Retrospective studies. *Proc. Roy. Soc. Med.* 57: 311, 1964.
8. Griner, P. F.: Hepatitis after repeated exposure to halothane, *Ann. Intern. Med.* 65: 753, 1966.
9. Morgenstern, L., Sacks, H. J., and Marmen, M. J.: Postoperative jaundice associated with halothane anesthesia, *Surg. Gynec. Obstet.* 121: 728, 1965.
10. Tammisto, T., Tiitinen, P., Elfving, G., and Hastabacka, J.: Repeated halothane anesthesia and possible liver damage, *Ann. Chir. Gynaec. Fenn.* 56: 45, 1967.
11. Klatskin, G.: Symposium on toxic hepatic injury, *Gastroenterology* 38: 786, 1960.

Epsom-salts Poisoning and a Review of Magnesium-ion Physiology

JOHN W. DITZLER, M.D.*

REPORT OF A CASE

A healthy 28-year-old woman had two martinis with dinner, followed by a postprandial bottle of beer. Several hours later she experienced gastric distress and took several antacid tablets. When this did not produce relief, she obtained a "box" of epsom salts and took "several tablespoonfuls" orally. This did not result in catharsis, and the possibility exists that she repeated the dose. By midnight, the patient was feeling weak and sleepy. Why this was considered abnormal at midnight was not made clear, but the patient was brought to the hospital, where she complained of dyspnea.

Examination revealed a sleepy, healthy woman, who appeared to have enlarged breasts and a lower abdominal swelling, believed at first to be due to pregnancy, but later found to be a greatly distended bladder. After catheterization the swelling disappeared, but the patient lost consciousness.

On the basis of the history and events, an intern drew a sample of blood for toxicologic examination and administered calcium gluconate, 1 g, intravenously. This was followed by the return of consciousness, and the patient appeared to be improved. The duration of the recovery was brief; she soon began to complain of weakness in her legs. Neurologic examination did not

reveal a sensory deficit, but there was obvious lower-limb weakness. Calcium gluconate was repeated, with a slight subjective improvement, but without materially changing the muscle weakness.

On rectal examination, a soft normal-colored well-formed stool was detected. There was no evidence of diarrhea. Between 1:00 AM and 2:45 AM, there was progressive ascending muscle weakness, which appeared to delineate at the fourth thoracic dermatome. The patient continued to complain of difficulty in breathing, although when asked to breathe deeply, there were normal respiratory excursions. Calcium chloride was now injected, but without subjective effect. At 3:00 AM the patient became agitated and complained bitterly of her inability to breathe, despite satisfactory diaphragmatic excursion, good vocal power, and full activity of the neck and jaw muscles. Additional information was sought relative to other drugs that might have been taken, but none could be confirmed. Differential diagnosis included a thrombosis of the anterior spinal artery, Guillain-Barré syndrome, myasthenia gravis and magnesium toxicity.

Fifteen milligrams of edrophonium (Tensilon) were administered without effect. Ventilation was assisted with a breathing bag, but the patient pleaded that the mask be removed. Gastric distention was noted. An attempt was made to pass a nasogastric tube, but the patient vocally objected although she was unable to move her arms and hands in protest. Despite this, she could

* Professor of Anesthesia, Northwestern University Medical School; Associate Director, Department of Anesthesia, Chicago Wesley Memorial Hospital, Chicago, Illinois.