

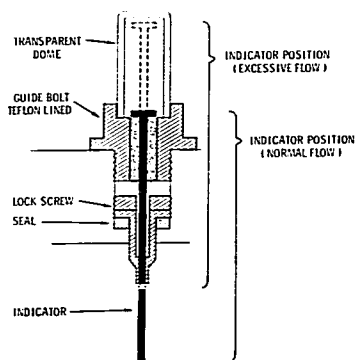Fig. 2. Signal device in raised and lowered positions.

bin would push the pin upward and the red top would be visible through the lucite chamber (fig. 1).

We chose the Foregger anesthesia machine as subject for our first prototype, but we believe that the device can be applied equally well to other anesthesia machines. A mechanical drawing of the device is shown in figure 2.

The authors thank Karl Pfaff for constructing the prototype.

#### REFERENCES

1. Adriani J: *Techniques and Procedures of Anesthesia*. Third edition. Springfield, Ill., Charles C Thomas, 1964
2. Dripps RD, Eckenhoff JE, Vandam LD: *Introduction of Anesthesia*. Third edition. Philadelphia and London, W. B. Saunders Co., 1968.

## Pneumatic Exsanguination for Intravenous Regional Anesthesia

ALON P. WINNIE, M.D., AND S. RAMAMURTHY, M.D.

Intravenous regional anesthesia is a simple procedure readily performed even by one inexperienced with the technique. It may be the anesthesia of choice for elective surgery in patients with severe impairment of cardiac reserve, since the blood levels of local anesthetic resulting from this type of anesthesia, when properly conducted, are considerably lower than those resulting from brachial plexus anesthesia.<sup>1</sup>

One of the problems originally associated with the intravenous regional anesthesia technique was that of tourniquet pain. This was largely solved by application of a double-cuffed tourniquet or a second tourniquet distal to the first in the area of anesthesia, with subsequent removal of the proximal cuff.<sup>2,3</sup> However, another problem which has remained unsolved is that presented by the patient with trauma to the hand or arm so that application of an Esmarch bandage is too painful, and even simple elevation of the extremity as a compromise to produce some degree of exsanguination is unbearable. In this situation inadequate exsanguination all too often results in spotty or absent anesthesia. In addition,

back-bleeding becomes a significant problem during the course of surgery.

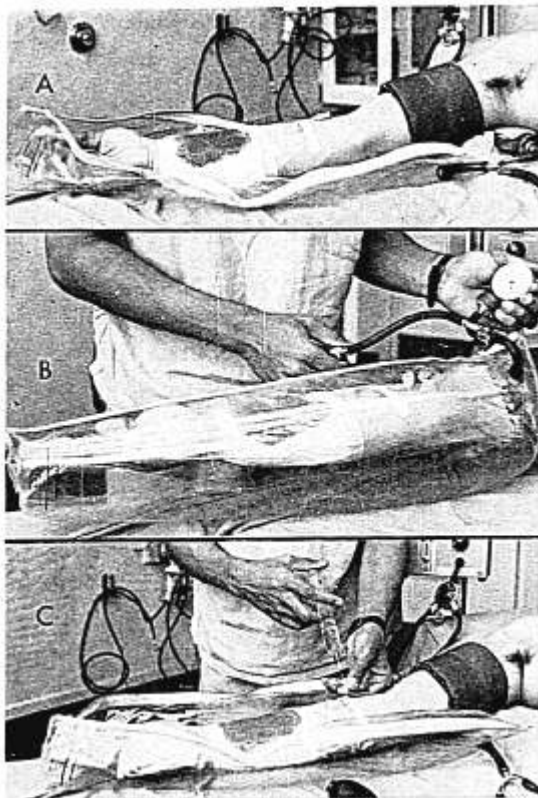
For such situations we have developed a painless technique of pneumatic exsanguination (fig. 1). When the patient is positioned on the surgical table, the painful extremity is placed in an inflatable arm splint<sup>\*</sup> designed for the stabilization of fractures. After venipuncture has been accomplished with a rubber-stoppered butterfly needle, the zipper is closed. The splint is then inflated to a pressure that exceeds arterial pressure, either by using a hand pump (fig. 1B) or, more simply, by attaching the delivery tube of an anesthesia machine and filling the splint with nitrous oxide.

Usually, as the pressure in the splint increases the pain in the extremity decreases, particularly if the injury is an unstable fracture. After the appropriate pressure has been reached in the splint, the proximal cuff of the double-cuffed tourniquet is inflated, the pneumatic splint is deflated and unzipped, and the intravenous injection of local anesthetic is made via the butterfly needle (fig. 1C). When

Received from the Division of Anesthesiology, Cook County Hospital, Chicago, Illinois.

\* Available as Redi Splint (Half-Arm Splint #30-966-1), Parke, Davis and Company, Detroit, Michigan 48232.

FIG. 1. The technique of intravenous regional anesthesia using pneumatic exsanguination. The injured extremity is placed on the open, uninflated pneumatic splint, a double-cuffed tourniquet is applied, and venipuncture is accomplished with a rubber-stoppered butterfly needle (A). The splint is zipped closed and the pressure is inflated to just above arterial pressure (B), after which the proximal cuff of the double-cuffed tourniquet is inflated to a similar pressure. The splint is then deflated and unzipped and the local anesthetic injected via butterfly needle (C). Following the onset of anesthesia the distal cuff of the double-cuffed tourniquet is inflated and the proximal cuff is deflated.



anesthesia is complete, the anesthetized arm is painlessly lifted out of the splint, the distal tourniquet cuff is inflated and the proximal cuff deflated, and the surgical procedure may be accomplished with ease.

Although designed for exsanguination of the painful extremity prior to administration of intravenous regional anesthesia, this technique of pneumatic exsanguination has proved to be so simple and effective that it has been adopted at our institution as the routine means of exsanguinating the arm whenever this form of anesthesia is indicated. The only problems that have been encountered resulted from errors on the part of the anesthetist: 1) failure

to utilize a pressure greater than arterial pressure; and 2) use of the technique to exsanguinate an arm which could not be straightened due to a fracture of the radial head.

#### REFERENCES

1. Mazze RI, Dunbar RV: Plasma lidocaine concentrations after caudal, lumbar epidural, axillary block, and intravenous regional anesthesia. *ANESTHESIOLOGY* 27:574-579, 1966
2. Momberg S: On Bier's intravenous anesthesia (Zur Venen anasthesie Bier's). *Zentralblatt fur Chir.* 36:1413-1414, 1909
3. Hoyle JR: Tourniquet for intravenous regional analgesia. *Anesthesia* 19:294-295, 1964