

Backflow of Liquid Halothane into a Flowmeter

To the Editor:—This letter describes a minor production defect in a recently-installed piece of anesthetic equipment which was manifested in an initially baffling event.

We were inducing anesthesia with thiopental, nitrous oxide, and halothane, using a new "Side-arm" Verni-trol vaporizer for the first time. The induction was uneventful until positive-pressure ventilation was initiated. Then, each time the reservoir bag was compressed, liquid halothane cascaded from the vaporizer into the "Side-arm" flowmeter. The rotameter

tube quickly filled sufficiently to obstruct further flow of oxygen. Since the liquid traveled only retrograde from the Verni-trol, no liquid halothane reached the patient circuit. We immediately switched off the defective system, substituted a portable halothane vaporizer, and completed the anesthetization without difficulty.

Subsequent analysis disclosed the source of malfunction to be a loose hex-nut cap on the flowmeter tube (fig. 1). Application of positive pressure at the patient end of the va-

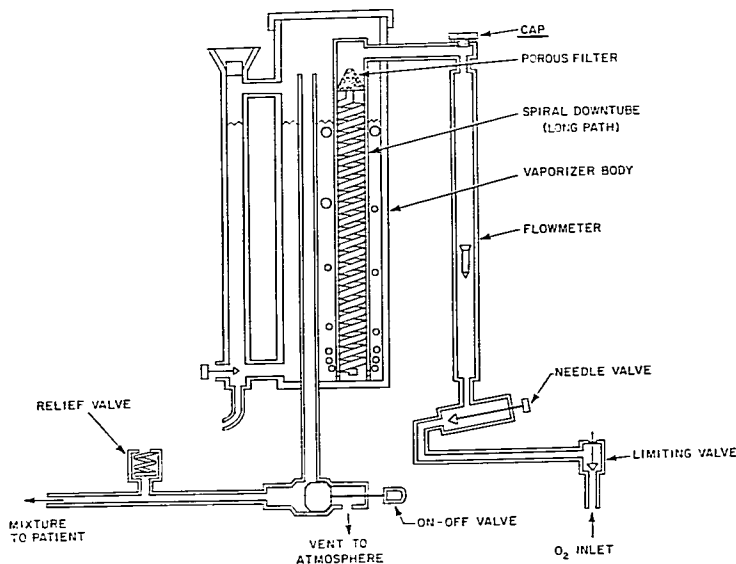


FIG. 1. Circuit diagram of the "Side-arm" Verni-trol Vaporizer, adapted from figure 2 in the "Operation and Repair Manual." Reproduced with permission of Ohio Medical Products.

porizer circuit normally produces no backflow of liquid halothane into the rotameter tube because of compensating pressure within the flowmeter. But with an avenue for the escape of pressure on the rotameter side of the circuit, liquid halothane could be forced up through the spiral tube into the flowmeter. Drying the flowmeter and tightening the hex nut solved the problem.

The explanation is simple, but we confess to requiring a few minutes of systematic sleuthing at the conclusion of the case to discover the

loose cap and to determine how it contributed to the observed event.

RONALD A. GABEL, M.D.
*Instructor in Anaesthesia
Harvard Medical School
Junior Associate in Anaesthesia
Peter Bent Brigham Hospital*

J. BENT DANIELSEN, M.D.
*Instructor in Anaesthesia
Harvard Medical School
Boston, Mass. 02115*

Surgery

POSTOPERATIVE MYOCARDIAL INFARCTION Three hundred sixty-five patients with no clinical symptoms of infarction within the preceding 24 months who were scheduled for major operations were studied. All patients had abnormal electrocardiograms preoperatively, with one or more of the following findings: previous myocardial infarction, bundle-branch block, left ventricular strain or hypertrophy, or ST segment changes suggesting subendocardial injury. Ninety per cent of patients received general anesthesia. Postoperatively, ECG and serum enzyme measurements were made daily. No changes were seen postoperatively in 201 patients. In only two of the nine patients in this group who died was there any clinical suspicion that death could have been due to silent myocardial infarction. ECG changes indicative of new or additional myocardial ischemia were seen in 64 patients (18 per cent). Thirty-four of these patients showed no clinical evidence of myocardial injury. Two of the 34 died, and at postmortem examination both had myocardial infarction. Thirty patients (8 per cent) suffered acute myocardial infarction, and 16 died as a result. Fifteen per cent of patients whose intraoperative systolic blood pressures decreased by 30 per cent or more for 10 minutes or longer and 3.5 per cent of patients who suffered no such hypotension developed postoperative myocardial infarction. It is suggested that routine stabilization of blood pressures in high-risk patients be attempted through the use of drugs. (*Mauney, F. M., Jr., Ebert, P. A., and Sabiston, D. C., Jr.: Postoperative Myocardial Infarction, Ann. Surg. 172: 497 (Sept.) 1970.*)

SUBCLAVIAN VENIPUNCTURE The technique of subclavian venipuncture via the infraclavicular route, the subject of numerous papers in recent years, has some vigorous proponents and, owing to occasional serious complications, a number of vehement antagonists. Reported complications include 1) pneumothorax, 2) hemothorax, 3) hydrothorax, 4) subcutaneous emphysema, 5) hematoma, 6) arterial puncture, 7) dermatocellulitis and septicemia, 8) brachial plexus injury, 9) cervico-mediastinal infiltration, and 10) air embolism. That these complications can and do occur is not questioned, but a number of authors think the risks are highly overestimated if proper techniques are rigidly observed. (*Johnson, C. L., and others: Subclavian Venipuncture: Preventable Complications; Report of Two Cases, Mayo Clin. Proc. 45: 712 (Oct.) 1970.*)