

## Clinical Workshop

S. G. HERSHEY, M.D., *Editor*

### Ketamine-induced Intracranial Hypertension

S. R. WYTE, M.D.,\* H. M. SHAPIRO, M.D.,† P. TURNER, M.D.,‡  
A. B. HARRIS, M.D.\*

Recent communications to the editors of *Lancet* have evoked controversy concerning the safety of using ketamine for neurodiagnostic procedures.<sup>1-4</sup> During continuous monitoring of intracranial pressure (ICP) in high-risk neurosurgical patients we have observed acute elevations of ICP after administration of ketamine to patients undergoing diagnostic and minor neurosurgical procedures. Our initial findings are presented below in the form of two case reports. Prior to administration of ketamine one patient had signs and symptoms of increased intracranial pressure and the second had normal intracranial pressure.

#### REPORT OF TWO CASES

**Patient 1.** An 8-year-old boy who had a ventriculoatrial shunt in place for obstructive hydrocephalus secondary to aqueductal stenosis returned to the University Hospital with a two-day history of diplopia and intermittent headache. He was alert and oriented, and examination showed paresis of upward gaze, loss of convergence, and symmetrically dilated pupils which reacted sluggishly to light. The remainder of the physical examination was within normal limits. Examination of the non-valved flushing device suggested cardiac end obstruction. The dome of the flushing device was tapped; opening pressure was 9.5 torr. Twelve hours later, the patient became obtunded and was irritable when stimulated. Tap of the

flushing device revealed an opening pressure of 11 torr, and 6 ml of crystal-clear fluid were removed. Subsequently, the patient became increasingly alert, coherent, and oriented. An external ventriculostomy with a CSF drainage system was established, with resolution of his symptoms.

Twenty-four hours after the patient's admission a ventriculogram was obtained. The child was alert and asymptomatic. The external ventriculostomy was connected to a pressure transducer; ICP was 8 torr (fig. 1A). Blood pressure was 120/80 torr; pulse 96/min, and respiratory rate was 20/min. At point 1, 2 mg/kg (ketamine 60 mg) were injected. Forty seconds later ICP rose precipitously to 42 torr, returning to the control level after 15 minutes. At this time the patient appeared sedated and responded to verbal commands. At points 2, 3, and 4, systemic blood pressure and respiratory rate were increased; these values returned to normal at point 5.

The ventriculogram showed obstructive hydrocephalus. The patient was maintained on external CSF drainage for an additional 12 hours, then brought to the operating room for revision of the ventriculoatrial shunt. The child was alert and oriented. The pressure transducer was reattached to the external ventriculostomy and anesthesia was induced with ketamine, 60 mg (fig. 1B). Immediately after induction, ICP rose rapidly to 7 torr. At point 2, of sodium thiopental, 100 mg was administered, and ICP fell rapidly to the pre-induction level. At point 3, manual hyperventilation was instituted, and ICP decreased precipitously. At points 4, 5, and 6, succinylcholine, 30 mg iv, was administered, and the trachea was intubated. Twenty minutes after his arrival in the recovery room at the completion of the procedure, the patient was alert and oriented.

**Patient 2.** A 17-year-old boy was being followed at the University Hospital for a low-grade astrocytoma of the hypothalamus and obstructive hydrocephalus. He was admitted for revision of his ventriculoatrial shunt because of infection with *Corynebacterium acnes*. The patient was asymptomatic, and his shunt was functioning properly. Prior to induction of anesthesia, a 22-gauge needle

\* Assistant Professor.

† Research Fellow and Resident.

‡ Resident.

Received from the Departments of Anesthesiology and Neurological Surgery and the Anesthesia Research Center, University of Washington School of Medicine, Seattle, Washington 98195. Supported in part by USPHS Training Grants GM 01160-08, NS 05211, and USPHS grant GM 15991-03, National Institute of General Medical Sciences, National Institutes of Health, Bethesda, Maryland.

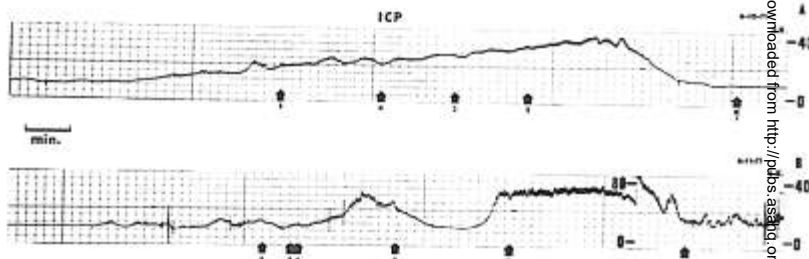


FIG. 1. Intracranial-pressure responses of Patient 1 to ketamine. A, 6-10-71. K, ketamine, 2 mg/kg (60 mg), blood pressure 120/70 torr, respiratory rate 16/min. 2, ketamine, 2 mg/kg (60 mg), blood pressure 120/80 torr, respiratory rate 20/min. 3, blood pressure 130/90 torr, respiratory rate 25/min. 4, blood pressure 130/90 torr, respiratory rate 16/min. 5, blood pressure 115/80 torr, respiratory rate 12/min. B, 6-11-71. K, ketamine, 2 mg/kg (60 mg), blood pressure 110/70 torr, pulse 112/min, respiratory rate 12/min. 2, sodium pentothal, 100 mg iv, blood pressure 135/95 torr. 3, manual hyperventilation. 4, succinylcholine, 30 mg iv. 5, laryngoscopy. 6, laryngoscopy and intubation.

was inserted into the flushing device and baseline recordings were obtained. At point 1 in figure 2, ketamine, 2 mg/kg (180 mg), was injected. Throughout the entire course of induction and intubation only small fluctuations in ICP were observed.

#### DISCUSSION

Our first case clearly demonstrates the risk of administering ketamine to patients with proven or suspected increased intracranial pressure. The resultant acute increase in ICP was similar to that observed when halothane is administered to patients with abnormal CSF pathways.<sup>4</sup> Halothane and ketamine have been shown to cause cerebrovascular dilatation and increased cerebral blood flow.<sup>5,6</sup> Presum-

ably the acute elevation in ICP observed with these agents is secondary to augmented cerebral blood volume.<sup>6,7</sup>

The elevated ventricular pressure in Patient 1 closely approximated the time course of the CBF and ICP changes in dogs given similar doses of ketamine by Dawson and associates.<sup>8</sup> In contrast to Dawson's findings of no significant change in mean arterial pressure, both our patients had significant increases in systemic and diastolic arterial pressures which followed the elevation in ICP. Following injection of ketamine respiratory stimulation was noted in each patient. This hyperventilation could induce a reduction in PaCO<sub>2</sub> and might thereby reduce cerebral blood flow and blood

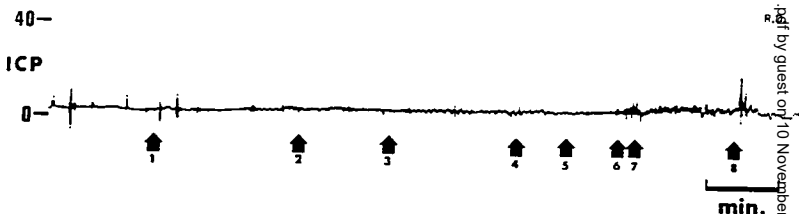


FIG. 2. Intracranial-pressure response of Patient 2 to ketamine (2 mg/kg). 1, ketamine, 2 mg/kg (180 mg), blood pressure 130/90 torr, pulse 75/min. 2, blood pressure 150/100 torr, pulse 85/min. 3, blood pressure 140/100 torr, pulse 87/min. 4, succinylcholine, 80 mg iv. 5, muscle fasciculation. 6, laryngoscopy. 7, 4 per cent xylocaine spray, 2 ml. 8, intubation.

volume, reducing the ICP response secondary to ketamine.<sup>8</sup> This phenomenon is illustrated in figure 1B where hyperventilation returned ICP to preinduction levels.

Sodium thiopental in 100-mg increments rapidly reversed the ketamine-induced intracranial hypertension in Patient 1. The effect of thiopental is transient and is related in time to drug redistribution.<sup>9</sup> Thiopental reversal of increased ICP may be due to cerebrovascular constriction with a concomitant fall in cerebral blood volume.<sup>10</sup> Dawson *et al.*<sup>6</sup> found that thiopental could reverse ketamine's effects on cerebral blood flow and metabolism in dogs pretreated with thiopental. Our findings suggest a similar effect when thiopental is administered after ketamine. The use of ketamine anesthesia for patients with neurologic lesions should be limited to those cases in which there are no signs or symptoms of increased intracranial pressure.<sup>1</sup>

#### REFERENCES

1. Bosomworth PP: Ketamine Symposium—comments by moderator. *Anesth Analg* (Cleve) 50:471-479, 1971

2. Evans J, Rosen M, Weeks RD, *et al.*: Ketamine in neurosurgical procedures. *Lancet* 1:40-41, 1971
3. Wilson GH: Ketamine in neuroradiology (letter to the editor). *Lancet* 1:243, 1971
4. Jennett WB, Barker J, Fitch W, *et al.*: Effects of anesthesia on intracranial pressure in patients with space-occupying lesions. *Lancet* 1:61-64, 1969
5. Wollman H, Alexander SC, Chase PJ, *et al.*: Cerebral circulation of man during halothane anesthesia. *ANESTHESIOLOGY* 25:180-184, 1964
6. Dawson B, Michenfelder JD, Theye A: Effects of ketamine on canine cerebral blood flow and metabolism: Modification by prior administration of thiopental. *Anesth Analg* (Cleve) 50:443-447, 1971
7. Risberg J, Ancrì D, Ingvar DH: Regional cerebral blood volume changes related to blood flow variations. *Scand J Clin Lab Invest* 22 suppl 102, XI:C, 1968
8. Reivich M: Arterial  $P_{CO_2}$  and cerebral hemodynamics. *Am J Physiol* E06:25-35, 1964
9. Brodie BB, Mark LC, Papper EM, *et al.*: The fate of thiopental in man and a method for its estimation in biological material. *J Pharmacol Exp Ther* 98:85-96, 1950
10. Pierce EC Jr, Lambertsen CJ, Deutsch *et al.*: Cerebral circulation and metabolism during thiopental anesthesia and hyperventilation in man. *J Clin Invest* 41:1664-1671, 1962

## Brain Anesthetic Concentration—A New Concept

BERNARD WOLFSON, M.B., F.F.A.R.C.S., SUSAN E. DORSCH, M.D.,  
TONG-SHIANG KUO, M.D., E. S. SIKER, M.D.

The minimum alveolar concentration (MAC) of anesthetic agent necessary to produce anesthesia has become a basis for comparison of agents. Additionally, depth of anesthesia may be discussed in terms of MAC and multiples thereof. The validity of the concept is dependent upon the equilibration of the agent between alveolar, arterial and brain compartments. While brain equilibration at constant arterial concentrations usually takes less than 15 minutes,<sup>1</sup> alveolar-arterial equilibration

may be time-consuming, especially with soluble agents such as methoxyflurane.

If it is assumed that the degree of narcosis is a function of the concentration of the agent in the brain, then direct measurement of the concentration seems reasonable. In addition, if cardiovascular depression is related to the concentration in heart muscle, then this, too, is worthy of attention. Such direct measurement offers a number of possible advantages. Equilibration of the agent between the tissues being measured and the arterial blood should not be necessary. Small animals, in which measurement of alveolar concentration is tech-

Received from the Department of Anesthesiology, Mercy Hospital, Pittsburgh, Pennsylvania.