

Clinical Workshop

S. G. HERSHEY, M.D., *Editor*

Failure of Spinal Anesthesia Due to Subdural Catheter Placement

CHARLES A. COHEN, M.D.,* AND TAMAS KALLOS, M.D.†

At times anesthesiologists are puzzled by failure of anesthesia following injection of local anesthetic through a spinal needle from which cerebrospinal fluid has flowed. One explanation for this has been that the injection was subdural rather than subarachnoid.¹ Radiologists see inadvertent injection of radiopaque solutions into the subdural space as a common complication of myelography.² We report here a "failed catheter spinal" that probably resulted from subdural injection.

REPORT OF A CASE

A 78-year-old man was scheduled for total hip replacement for degenerative joint disease. Except for rheumatoid arthritis of the hands, he was in good general health, without history of neurologic symptoms or previous subarachnoid puncture. For the induction of continuous spinal anesthesia, he was placed in the right lateral decubitus position and, after several attempts, an 18-gauge Hustead needle was inserted at the L5-S1 interspace, using a right paramedian approach. Cerebrospinal fluid (CSF), the first few drops of which were blood-tinged, dripped slowly through the needle, but aspiration of fluid was difficult even after rotating the needle. A teflon catheter was inserted 3-4 cm beyond the needle tip and the needle removed. Aspiration through the catheter yielded 1.5 ml of clear CSF, but with difficulty. This volume of CSF was mixed with 1 ml of 1 per cent tetracaine (final concentration 4 mg/ml). With the patient still in the right lateral decubitus position, 0.5-ml increments of this solution were injected through the catheter until the total 10-mg dose had been given. The patient felt no warmth or paresthesias; no sympathetic blockade or sensory level was de-

tectable after 20 minutes. General anesthesia was then induced, and the operation proceeded without difficulty. Three hours later, in the recovery room, no sensory level could be elicited. To determine the position of the catheter, 2 ml of iophendylate (Pantopaque) were injected through it. Figure 1 shows the abdominal roentgenogram made

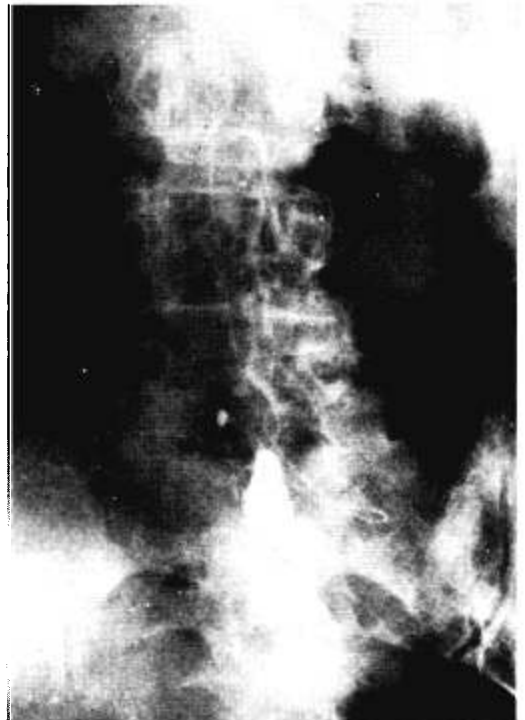

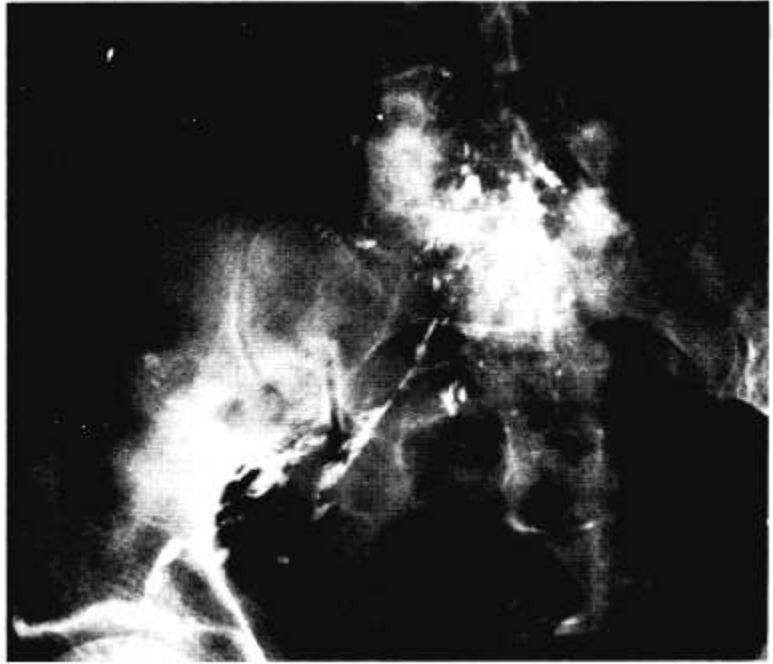
FIG. 1. Abdominal roentgenogram immediately after injection of Pantopaque. The contrast material had a smooth border consistent with either a subdural or a subarachnoid location, but it did not move with position change, suggesting subdural placement.

* Resident in Anesthesia.

† Assistant Professor.

Received from the Department of Anesthesia, University of Pennsylvania School of Medicine, Philadelphia, Pennsylvania 19104.

FIG. 2. Abdominal roentgenogram a week after injection of Pantopaque. The bulk of the contrast material had not changed location, but a small amount "streaking out" along nerve roots can be seen; this is consistent with epiarachnoid injection.



with the patient in the supine position immediately after this injection. A roentgenogram in the Trendelenburg position failed to reveal a shift of the contrast material. A week later, roentgenologic examination showed "streaking out" of the Pantopaque along the nerve roots (fig. 2). The patient had an uneventful postoperative course.

DISCUSSION

Failure to obtain anesthesia could have occurred for any of the following reasons: 1) catheter in the subarachnoid space but impotent drug; 2) catheter in the subdural space; 3) catheter in the epidural space. Although potency of the tetracaine was not tested, the contrast material should have shifted with position change had the catheter been located in the subarachnoid space. Had the catheter tip originally been located in the epidural space, perforation of the arachnoid space would have had to occur to allow CSF to be aspirated. Also, contrast material would have been expected along the nerve roots soon after the epidural injection.² It seems likely, therefore, that the catheter tip was located in the subdural space; this conclusion would be sup-

ported both by the failure of movement of contrast material with position change and by the slow migration along the nerve roots. In addition, the smooth border of the contrast material soon after injection is more characteristic of subdural than of epidural placement.

Sechzer¹ has discussed the possibility of subdural injection as a cause of "failed spinal" and has demonstrated that the subdural space is anatomically distinct from the subarachnoid space. The presence of spinal fluid in the subdural space has been postulated to occur owing to developmental defects in the arachnoid membrane or following traumatic perforation of the arachnoid by a needle. In this case it appears likely that the latter occurred, since several attempts were made before fluid flowed from the needle.

REFERENCES

1. Sechzer PH: Subdural space in spinal anesthesia. *ANESTHESIOLOGY* 24:869-870, 1963
2. Wood EH, Taveras JM: *Diagnostic Roentgenology*. Volume 1. Edited by LH Robbins. Baltimore, Williams and Wilkins, 1967, p 839