

Clinical Workshop

S. G. HERSHEY, M.D., *Editor*

Open-mouthed Head Lifting, A Sign of Incomplete Reversal of Neuromuscular Blockade

TAMAS KALLOS, M.D.*

Anesthetists commonly rely on the head-lifting test to ascertain the return of muscle power after the use of muscle relaxants. This test, although it does not directly test the respiratory muscles, correlates well with maximal inspiratory and expiratory pressures¹ and recovery of vital capacity to more than 75 per cent of control.² This is a report of a refinement of the head-lifting test which may help further in identifying residual neuromuscular blockade.

The initial observations were made in a study of four informed awake anesthesia residents. Each had received *d*-tubocurarine by intravenous drip until vital capacity was reduced 50 per cent for a study of respiratory responsiveness to carbon dioxide (*d*-tubocurarine, 18 to 24 mg, given in 45 to 60 minutes). After the study had been completed, the neuromuscular block was reversed with neostigmine, administered in 1-mg increments intravenously every 1 to 2 minutes. After each injection, the subject was asked to lift his head. During this gradual reversal, it was noted that when the subject first succeeded in raising his head off the bed (neostigmine, 2-3 mg), he would have his mouth open. (fig. 1). After an additional 1 to 2 mg of neostigmine, head-lifting would be performed with a closed

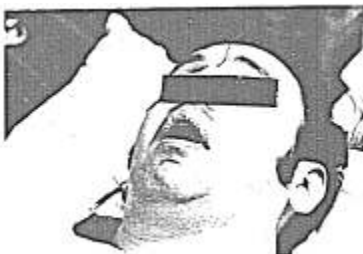

FIG. 1. A volunteer attempting head-lifting after 24 mg of *d*-tubocurarine, given over 45 minutes, was followed by 2 mg of neostigmine. Note the open mouth.




FIG. 2. Same as figure 1, but the total dose of neostigmine was 4 mg. Head-lifting is now performed with the mouth closed.

* Assistant Professor. Present address: Department of Anesthesiology, University of Miami School of Medicine, Miami, Florida 33152.

Received from the Department of Anesthesia, University of Pennsylvania School of Medicine, Philadelphia, Pennsylvania 19104. Accepted for publication May 22, 1972. Supported (in part) by USPHS Grant 1-P01-GM-15430-03 from the National Institute of General Medical Sciences, National Institutes of Health.

mouth (fig. 2). Later, in another subject, observations were made during gradual curarization. As before, the partially-curarized subject (12 *d*-tubocurarine) would elevate his head with an open mouth.

TABLE 1. Conditions under Which Open- and Closed-Mouthed Head-lifting Occurred in Five Patients

	Drug	Dose (mg)	Duration of Blockade (Min)	Dose of Neostigmine (μ g)	
				Open-mouthed Head Lift	Closed-mouthed Head Lift
Patient 1	Gallamine	140	50	2.0	3.0
Patient 2	Gallamine	120	45	2.5	4.0
Patient 3	<i>d</i> -tubocurarine	27	55	2.5	3.5
Patient 4	<i>d</i> -tubocurarine	30	50	2.5	5.0
Patient 5	<i>d</i> -tubocurarine	42	85	3.0	4.5

The study was extended to patients who were awake enough to attempt head-lifting after *d*-tubocurarine- and gallamine-supplemented anesthesia. Like the volunteers, the patients had their mouths open on head-lifting when neuromuscular blocks were incompletely reversed. Administration of more neostigmine resulted in head-lifting with a closed mouth. The doses of neuromuscular blocker, durations of blockade, and amounts of neostigmine that produced partial reversal (open-mouthed head lifting) and clinically complete reversal (closed-mouthed head-lifting) for five patients are listed in table 1.

This phenomenon may be explained by the physical arrangement of the muscles (fig. 3). In the supine position, considerable muscle effort is necessary for head-lifting because the moment of the skull (*i.e.*, force or weight \times perpendicular distance from the fulcrum) is large. The head-flexor muscles (F_2) are aided by the jaw-opening muscles (F_4) when the jaw is stabilized by the jaw-closing muscles (F_3). During partial neuromuscular blockade, the moment of the jaw-openers exceeds that of the jaw-closers because of the difference between the lengths of their lever arms (l_4 and l_3 , respectively), resulting in an open mouth when head-lifting is attempted.

The open-mouthed head-lifting sign is of diagnostic value in clinical practice. Its presence suggests incomplete return of muscle power and the need for further reversing agent when the relaxant used was a nondepolarizing agent. Although no observations after administration of depolarizing relaxants were

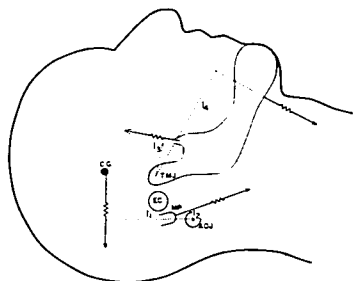


FIG. 3. Schematic representation of the physical arrangement of head-lifting forces. CG = center of gravity; AOJ = atlanto-occipital joint; MP = mastoid process; TMJ = temporomandibular joint; EC = ear canal.

made, the open-mouthed head-lifting sign may be expected to appear before complete return of muscle power after the use of this type of relaxant also.

The author thanks Drs. P. J. Cohen and J. R. Tyler, who made their volunteer subjects available to him for the above observations.

REFERENCES

- Johansen SH, Jorgensen M, Molbech S: Effect of tubocurarine on respiratory and non-respiratory muscle power in man. *J Appl Physiol* 19:990-994, 1964
- Waltz LF, Levin N, Dillon JB: Assessment of 1970 recovery from curare. *JAMA* 213:1894-1896,