

## Laryngeal Competence with Ketamine and Other Drugs

I. W. Carson, M.B., F.F.A.R.C.S.,\* J. Moore, M.D., F.F.A.R.C.S.,†  
J. P. Balmer, M.D., B.Sc., F.F.R.,‡ J. W. Dundee, M.D., Ph.D., F.F.A.R.C.S.,§  
T. G. McNabb, M.B., F.F.A.R.C.S.¶

The ability of the larynx to close in response to instillation of radiopaque dye into the pharynx was studied in 75 patients one minute after induction of anesthesia. Anesthesia was induced with ketamine, diazepam, chlormethiazole or one of three induction agents, with or without premedication. The presence of aspiration was assessed by radiologic screening. Soiling of the tracheobronchial tree with contrast medium occurred following all agents studied, and its incidence was increased by sedation or opiate premedication. The least aspiration occurred after 1 mg/kg ketamine or 0.5 mg/kg diazepam in the absence of preanesthetic medication. (Key words: Aspiration; Ketamine; Obstetrics; Intravenous anesthesia; Diazepam.)

ASPIRATION of gastric contents, with subsequent development of Mendelson's acid-aspiration syndrome, is a well-recognized hazard of the use of general anesthesia in obstetrics. An agent which would produce adequate analgesia for obstetric operations while leaving intact the pharyngeal and laryngeal reflexes would be a major advance in this field. Clinical pharmacologic studies by Domino *et al.* suggested that ketamine might be such a drug.<sup>1</sup> This was supported by the work of Moore *et al.*, who found that a "drink" of 20 ml of physiologic saline solution given to obstetric patients during ketamine anesthesia was

either swallowed or rejected.<sup>2</sup> However, depression of laryngeal reflexes following administration of ketamine,<sup>3</sup> as evidenced by tracheobronchial soiling by a radiopaque contrast medium placed at the back of the tongue, has been reported. This is contrary to the experience of Dundee and Moore,<sup>4</sup> but different premedications and doses of ketamine together with different timing of the laryngeal challenge may explain the discrepancy. To resolve the conflicting results, a larger study was carried out using two doses of ketamine given after different premedicants and comparing the findings with those obtained with other soporific drugs, diazepam<sup>5</sup> and chlormethiazole,<sup>6</sup> which are frequently used in obstetric practice. A study of induction agents (thiopental, methohexital, and Althesin<sup>7,8</sup>) was also included. This paper reports the findings in 75 patients in whom the competence of the laryngeal reflexes was tested a minute after induction of anesthesia.

### Methods

The protocol having been approved by the Faculty ethical committee, informed consent was obtained before minor gynecologic operations from 75 healthy patients, ranging in age from 18 to 48 years (average 28). They fasted from the evening prior to operation. No patient was sensitive to iodine. They fell into three groups:

1) Those receiving 1 or 2 mg/kg ketamine intravenously. Preanesthetic medication, when given, was an intramuscular injection of atropine, 0.6 mg, hyoscine, 0.4 mg, diazepam, 10 mg, or meperidine, 100 mg, 45 minutes prior to induction of anesthesia.

2) Patients receiving diazepam or chlormethiazole. Diazepam was administered intravenously at a rate of 5 mg every 5 minutes

\* Research Fellow.

† Lecturer in Obstetric Anaesthesia.

‡ Consultant Radiologist, South Belfast Hospital Group.

§ Professor of Anaesthetics.

¶ Former Senior Registrar, Department of Anaesthetics.

Received from the Department of Anaesthetics, The Queen's University of Belfast and South Belfast Hospital Group, Belfast, Northern Ireland. Accepted for publication September 8, 1972. Send reprint requests to: I. W. C., Department of Anaesthetics, Institute of Clinical Science, Grosvenor Road, Belfast, BT12 6BJ, Northern Ireland.

until the patient was drowsy but responded to commands. Premedication, when given, was hyoscine, 0.4 mg, or meperidine, 100 mg.

Chlormethiazole, which is chemically related to vitamin B<sub>1</sub>, is a sedative and anticonvulsant drug which is becoming increasingly popular in the management of pre-eclamptic toxemia.<sup>9</sup> It was administered as an intravenous infusion of a 0.8 per cent solution until the patient was either responsive and "lightly" anesthetized or unresponsive and "deeply" anesthetized. No premedication was given to these patients.

3) Patients receiving intravenous induction agents without prior medication. These were thiopental (4 and 6 mg/kg), methohexital (1.0 and 1.6 mg/kg), and Althesin, a new steroid induction agent (50  $\mu$ l/kg).

A minute after the induction of anesthesia or attainment of the desired level of sedation, 20 ml of an oily suspension of propylidone (Dionosil), as used for bronchography, were injected into the back of the pharynx using a syringe and a plastic catheter. The patient's throat and chest were screened with a Phillips BV20 portable image intensifier with strict coning to a narrow area to prevent scatter of radiation. Screening exposures lasted 2 seconds and were repeated at 1-minute intervals for 5-6 minutes as necessary. At the end of screening, the operation was begun and anesthesia was maintained with nitrous oxide-oxygen and suitable adjuvants. Where there was any evidence of contamination of the tracheobronchial tree by dye, x-ray examination of the chest was carried out about half an hour after the end of the operation. Screening of the patients and examination and interpretation of all x-rays were done by one radiologist (J. P. B.).

During all procedures, an efficient suction apparatus, a laryngoscope, an endotracheal tube fitted with connections, and a syringe containing a mixture of 100 mg succinylcholine and 0.6 mg atropine were immediately available. Three anesthesiologists were present at all times.

Where the incidence of aspiration was low, the number of patients studied in each series was 10 to 12. This was reduced to three in the remaining series, except for the induction agents with which aspiration and laryngo-

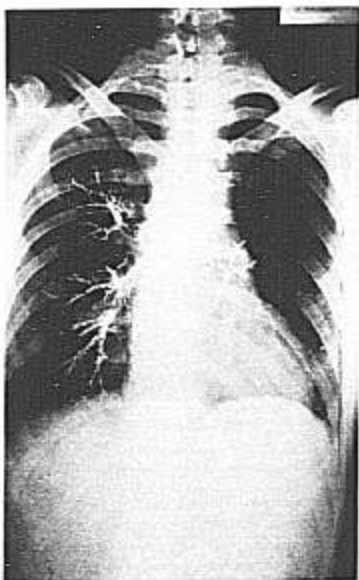


FIG. 1. Bilateral aspiration of contrast medium with 2 mg/kg ketamine after preanesthetic medication with meperidine, 100 mg.

spasm limited the numbers to one or two in each group.

Soiling of the tracheobronchial tree was subdivided into two categories, frank aspiration of contrast medium (fig. 1) and tracheal soiling (fig. 2), depending on whether the contrast medium passed beyond the carina. This was purely a radiologic diagnosis. Where aspiration did not occur, it can be assumed that the dye was actively swallowed.

### Results

The addition of sedative premedication increased the incidence of aspiration, especially with ketamine at the 2 mg/kg dose level (table 1). In the absence of preanesthetic medication, almost half of the patients receiving the larger dose had no dye in the tracheo-

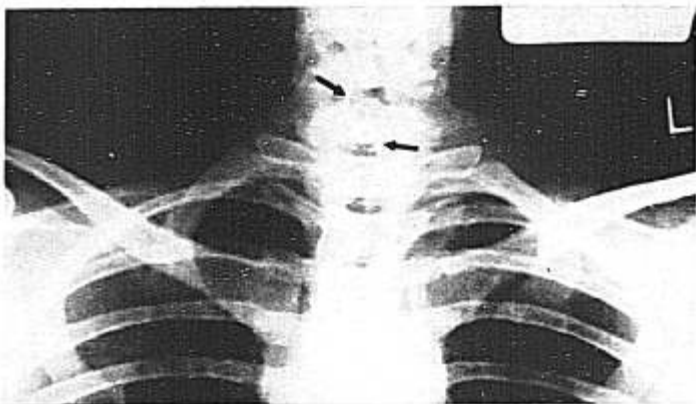

FIG. 2. Tracheal soiling, as evidenced by two thin lines of contrast medium on the tracheal wall, following sedation with diazepam.

bronchial tree. With 1 mg/kg, two thirds of the patients without preanesthetic medication had no evidence of aspiration, while in only one had the medium passed the carina. The addition of any sedative preanesthetic medication increased the risk of tracheal aspiration to a significant degree ( $P < 0.025$ ,  $\chi^2 = 6.44$  at 2 mg/kg;  $P < 0.01$ ,  $\chi^2 = 7.87$  at 1 mg/kg).

Of the ten unpremedicated patients receiving diazepam (table 2), only one had frank aspiration, compared with a 50 per cent incidence (i.e., three of six patients) in patients who received sedative premedication. All the patients receiving a combination of meperidine and diazepam, iv, had some evidence of aspiration of dye.

The events with chlormethiazole were different from those with any of the other agents. Five of the six patients receiving this drug inhaled the contrast medium, and two of these five actually regurgitated and aspirated it, one developing laryngospasm, respiratory obstruction, and cyanosis. Regurgitation did not occur with any other drug.

Following induction of anesthesia with thiopental, methohexital and Althesin, aspiration of contrast medium occurred in eight of nine patients (table 3). The remaining patient,

who was given the smaller induction dose of thiopental, developed mild laryngospasm. This occurred in four of the seven patients receiving a barbiturate, and was particularly troublesome with light methohexital anesthesia, but was not encountered with Althesin.

Figure 3 shows the percentage incidences of aspiration with the different drugs, with and without preanesthetic medication. It can be seen that the lowest incidence of tracheo-bronchial soiling was with 1 mg/kg ketamine and 0.5 mg/kg diazepam in unpremedicated subjects.

### Discussion

In their review of the current status of ketamine, Bovill and colleagues<sup>10</sup> stated, "one cannot be certain as to its safety in the presence of a full stomach. Here it is vital that anesthesia should not be too deep, or the advantage of the drug is lost." The present investigation substantiates this view and also the view that its use should be restricted to physicians skilled in the management of airway problems.<sup>11</sup>

Although the use of ketamine does not guarantee that the trachea will be fully protected from aspiration, in unpremedicated subjects,

TABLE 1. Incidences of Soiling of the Tracheobronchial Tree after Two Doses of Ketamine with Various Medications

	Praesthetic Medication	Number of Patients	Number of Patients Who Had Aspiration	Number of Patients Who Had Tracheal Soiling	Number "Clear"
Ketamine, 2 mg/kg	None	11	6	0	5
	Atropine, 0.6 mg	3	2	1	0
	Hyoscine, 0.4 mg	3	3	0	0
	Diazepam, 10 mg	3	3	0	0
	Meperidine, 100 mg	3	3	0	0
Ketamine, 1 mg/kg	None	12	1	3	8
	Hyoscine, 0.4 mg	3	3	0	0
	Diazepam, 10 mg	3	1	0	2
	Meperidine, 100 mg	3	2	0	1

TABLE 2. Incidences of Soiling of the Tracheobronchial Tree after the Drug Combinations Shown

	Average Dose	Praesthetic Medication	Number of Patients	Number of Patients Who Had Aspiration	Number of Patients Who Had Tracheal Soiling	Number "Clear"
Diazepam	0.5 mg/kg	None	10	1	3	6
	0.4 mg/kg	Hyoscine, 0.4 mg	3	1	0	2
	0.4 mg/kg	Meperidine, 100 mg	3	2	1	0
Chlormethiazole	0.25 ml/kg/min (light)	None	3	0	3	0
	0.34 ml/kg/min (deep)	None	3	2	0	1

TABLE 3. Incidences of Soiling of the Tracheobronchial Tree with Propylidone (Dionosil) Given One Minute after Three Induction Agents

Induction Agent	Dose	Number of Patients	Number of Patients Who Had Aspiration	Number of Patients Who Had Tracheal Soiling	Number "Clear"
Thiopental	4 mg/kg	2	1	0	1
	6 mg/kg	1	1	0	0
Methohexital	1.0 mg/kg	2	2	0	0
	1.6 mg/kg	2	2	0	0
Althesin	50 $\mu$ l/kg	2	2	0	0

even at the lower dose of 1 mg/kg, it would appear to provide greater protection than any other agent studied except diazepam. This may have been a result of preservation of the swallowing reflex. More important is the observation that any sedative premedication increases the risk of tracheal aspiration after ketamine, and in obstetric practice one must

remember that many patients will have received sedative or analgesic drugs during labor.

There are unsubstantiated reports of aspiration of gastric contents in non-intubated patients given ketamine<sup>12,13</sup> and a description of aspiration pneumonitis following its use in a child.<sup>14</sup> This patient, a 6-year-old boy, had also received pentobarbital. His intracranial

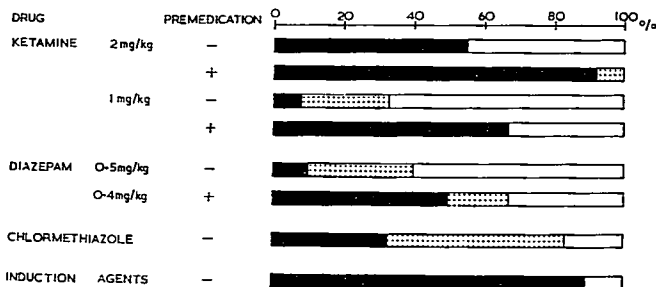


FIG. 3. Overall incidences of aspiration (solid bars) and tracheal soiling (bars with dots) with various drugs, with and without preanesthetic medication.

pressure was high, and he vomited about 15 minutes after loss of consciousness and failed to cough after the vomiting episode.

In some countries diazepam, iv, is commonly employed as a sedative for the anxious patient prior to artificial rupture of the membranes and in the treatment of pre-eclamptic toxemia and eclampsia. All our patients given diazepam, iv, were responsive to command, swallowing readily, and were in a lighter plane of anesthesia than those receiving ketamine, 1 mg/kg. When preanesthetic medication was avoided, aspiration was not a problem, but unlike the ketamine-treated patients, these patients could not have undergone surgery. Although narcotic premedication permitted use of a lower dose of diazepam to produce the necessary depth of sedation, it also resulted in a 100 per cent incidence of tracheobronchial soiling. This drug combination is commonly used in the obstetric patient. When used as a sedative for conservative dentistry, diazepam has been shown to produce a period of incompetence of the laryngeal closure reflex.<sup>15</sup>

Tomlin *et al.* demonstrated that the laryngeal reflex can be depressed for as long as two hours following any light general anesthesia.<sup>16</sup> Others have demonstrated that contrast medium can be aspirated into the tracheobronchial tree during intermittent methohexitone anesthesia for conservative dentistry.<sup>17, 18</sup> In the present study the barbiturates were particularly dangerous, especially during the light anesthesia, as laryngospasm and airway obstruction were encountered.

Although this study has revealed a moderately low incidence of aspiration of propylidone after small doses of ketamine without premedication, it must be appreciated that a nonirritant contrast medium was used. Perhaps laryngeal closure would have occurred more frequently, with consequent lessening of aspiration, had a more irritant contrast medium been used. Since this work was started, a method using very dilute ammonia in air as a challenge has been described by Hinkle and Tatum,<sup>19</sup> but it was felt ethically unjustifiable to pursue this study further.

The authors thank their gynecological colleagues and the nursing staff and radiographers of Musgrave Park Hospital for their cooperation in this study. This work was supported in part by a grant from Parke, Davis and Company.

## References

1. Domino EF, Chodoff P, Corssen G: Pharmacologic effects of CI-581: a new dissociative anesthetic in man. *Clin Pharmacol Ther* 6: 279-290, 1965
2. Moore J, McNabb TC, Dundee JW: Preliminary report on ketamine in obstetrics. *Br J Anaesth* 43:779-782, 1971
3. Taylor PA, Towey RM: Depression of laryngeal reflexes during ketamine anaesthesia. *Br Med J* 2:688-689, 1971
4. Dundee JW, Moore J: Ketamine anaesthesia (correspondence). *Br Med J* 3:46, 1971
5. Lean TH, Ratnam SS, Sivasamboo R: Use of benzodiazepines in the management of eclampsia. *J Obstet Gynaecol Br Commonw* 75:856-862, 1968

6. Chlormethiazole: Proceedings of a Symposium. *Acta Psychiatr Scand* suppl 192, 1966
7. Campbell D, Forrest AC, Miller DC, et al: A preliminary clinical study of CT 1341—a steroid anaesthetic agent. *Br J Anaesth* 43:14–24, 1971
8. Clarke RSJ, Montgomery SJ, Dundee JW, et al: Clinical studies of induction agents. XXXIX: CT 1341, a new steroid anaesthetic. *Br J Anaesth* 43:947–952, 1971
9. Duffus GM, Tunstall ME, MacGillivray I: Intravenous chlormethiazole in pre-eclamptic toxemia in labour. *Lancet* 1:335–337, 1968
10. Bovill JG, Coppel DL, Dundee JW, et al: Current status of ketamine anaesthesia. *Lancet* 1:1285–1288, 1971
11. Coppel DL, Dundee JW: Ketamine anaesthesia for cardiac catheterisation. *Anaesthesia* 27:25–31, 1972
12. Bosomworth PP: Ketamine Symposium—comments by moderator. *Anesth Analg (Cleve)* 50:471–479, 1971
13. Bush GH: Discussion on ketamine anaesthesia for burns surgery. *Postgrad Med J* 48: 156–161, 1972
14. Penrose BH: Aspiration pneumonitis following ketamine induction for general anaesthesia. *Anesth Analg (Cleve)* 51:41–43, 1972
15. Healy TEJ, Robinson JS, Vickers MD: Physiological responses to intravenous diazepam as a sedative for conservative dentistry. *Br Med J* 3:10–13, 1970
16. Tomlin PJ, Howarth FH, Robinson JS: Post-operative atelectasis and laryngeal incompetence. *Lancet* 1:1402–1405, 1968
17. Wise CC, Robinson JS, Heath MJ, et al: Physiological responses to intermittent methohexitone for conservative dentistry. *Br Med J* 2:540–543, 1969
18. Mann PE, Hatt SD, Dixon RA, et al: A minimal increment methohexitone technique in conservative dentistry—a comparison with treatment under local analgesia. *Anaesthesia* 26:3–21, 1971
19. Hinkle JE, Tatum KR: A technique for measuring reactivity of the glottis. *Anesthesiology* 35:634–637, 1971

## Obstetrics

**ABORTION AND COAGULATION FACTORS** Coagulation studies were carried out in 40 patients undergoing induced abortion by intra-amniotic injection of hypertonic saline solution. Other reports have indicated that severe defibrination syndromes can occur with this method of abortion. Findings of the study included: 1) no significant change in prothrombin time, partial thromboplastin time, or fibrinogen level; 2) a lowered platelet count, as well as profibrinolysin and fibrinolytic inhibitor levels; 3) the appearance of soluble fibrin monomers in plasma; 4) a decrease in factor VIII. The association of decreased platelet count, decreased factor VIII and evidence of soluble fibrin monomers suggests that early incomplete activation of the coagulation system was taking place. In addition, the reduced profibrinolysin and fibrinolytic inhibitor levels indicated slight activation of the fibrinolytic system. Despite these changes, no sign of thrombosis or hemorrhage was evident in any patient studied. One patient, not included in the study, has since developed disseminated intravascular coagulation. The authors note that problems may develop in the rare patient with pre-existing coagulation defects, fibrinolytic defects, or thrombocytopenia. (Brown, F. D., Davidson, E. C., Jr., and Phillips L. L.: *Coagulation Change after Hypertonic Saline Infusion for Late Abortions*. *Obstet. Gynecol.* 39: 538–543, 1972.)