

TABLE 1. Enzymatic Changes after the First Anesthetic

	27/10/72	28/10/72	29/10/72	30/10/72	Normal Values
CPK, μ units/ml	4,000	3,480	3,400	1,870	5-50
LDH, units/ml	3,250	2,800	1,480	1,060	208-442
SGOT, Karmen units	552	740	530	246	9-33

DISCUSSION

Several papers have suggested the usefulness of procainamide or procaine in the management of malignant hyperthermia,²⁻⁶ but its use without cooling has not been reported. We do not intend to understate the importance of cooling, but rather wish to emphasize the value of procainamide in the treatment of this condition.

The mechanism of action of procainamide in malignant hyperthermia is not known. Britt⁴ suggests that anesthesia triggers the release of calcium from a defective calcium storage membrane of muscle cells. This calcium stimulates muscle metabolism, with a vast increase in the utilization of oxygen and production of heat, hydrogen ions, and carbon dioxide. As ATP is consumed, there is not enough to supply the transport needs of the muscle membranes. Thus, the calcium leaks into the cells and the low extracellular fluid calcium induces neurogenic tetany, worsening the biochemical derangements. Procainamide seems to be effective by reducing calcium levels within the cytoplasm. This hypothesis suggests that early

management with procainamide can reverse the process before a vicious circle is entered.

Procaine was chosen for the second anesthetic because of its presumed usefulness in the therapy of malignant hyperpyrexia.⁴ If a longer anesthesia had been needed, tetracaine could have been used. Lidocaine and mepivacaine may initiate the lesion of malignant hyperthermia^{3,4} and therefore were not used.

REFERENCES

1. Britt BA, Kalow W: Malignant hyperthermia: A statistical review. *Can Anaesth Soc J* 17: 293-315, 1970
2. Kalow W: Succinylcholine and malignant hyperthermia. *Fed Proc* 31:1270-1275, 1972
3. Kalow W, Britt BA, Terreau ME, et al: Metabolic error or muscle metabolism after recovery from malignant hyperthermia. *Lancet* 895-898, Oct 31, 1970
4. Britt BA: Recent advances in malignant hyperthermia. *Anesth Analg (Cleve)* 51:841-851, 1972
5. Beldavs J, Small V, Cooper DA: et al: Post-operative malignant hyperthermia: A case report. *Can Anaesth Soc J* 18:202-212, 1971
6. Ratzlaff EH, Jenkins LC: Malignant hyperthermia: A case report of successful management. *Can Anaesth Soc J* 19:549-556, 1972

A New Technique of Caudal Anesthesia

WILLIAM D. OWENS, M.D.,* ELIOT M. SLATER, M.D.,†
GEORGE E. BATTIT, M.D.‡

* Assistant in Anesthesia, Department of Anesthesia, Massachusetts General Hospital; Instructor, Department of Anesthesia, Harvard Medical School.

† Director, Department of Anesthesia, Union Hospital, Lynn, Massachusetts.

‡ Associate Anesthetist, Department of Anesthesia, Massachusetts General Hospital; Assistant Professor, Department of Anaesthesia, Harvard Medical School.

Received from the Anaesthesia Laboratories of the Harvard Medical School at the Massachusetts General Hospital, Boston, Mass. 02114, and the Anesthesia Department, Union Hospital, Lynn, Mass. 01904. Accepted for publication February 5, 1973.

The complications and dangers of caudal analgesia include broken needles, severed catheters, complete spinal anesthesia, fetal scalp injections, and rectal injection. In a large series of cases reported by Dawkins,¹ dural puncture occurred in 1.2 per cent of 13,639 patients and unrecognized dural puncture in 0.1 per cent of 6,334 patients. Inadvertent fetal-scalp injections were initially reported in 1965^{2,3} and have been of concern to anesthesiologists and obstetricians ever since.

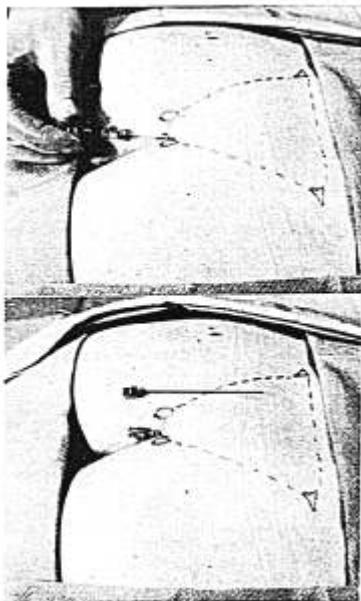


FIG. 1 (above). After passing the entire placement unit 1-1.5 cm into the caudal canal, the needle stylet is held in a fixed position and the cannula threaded off the stylet into the caudal epidural space. The stylet is NOT advanced farther.

FIG. 2 (below). The cannula in place with the needle alongside to illustrate the approximate distance the cannula has been advanced.

We have developed a new technique for single injection or continuous caudal analgesia which lessens the dangers of fetal-scalp and subarachnoid injections and needle breakage. Identification of the appropriate anatomic landmarks for the sacral hiatus have been described.^{4,5} A standard intravascular 2½-inch 16-gauge Teflon catheter with needle stylet is introduced through the sacrococcygeal ligament into the sacral hiatus. The entire unit is advanced cephalad about 1-1.5 cm beyond the sacrococcygeal ligament. The needle stylet is then withdrawn about 0.5 cm. The catheter is then advanced as far as desired

(approximately 3.0 cm in the average woman) holding the stylet stationary. The needle is then withdrawn completely (figs. 1 and 2). After ascertaining, by aspiration, that the catheter tip is not in the subarachnoid space or blood vessel, a test dose of an appropriate volume of local anesthetic is injected. The remainder of the desired dose of the anesthetic solution is injected after evaluating the effect of the test dose. When a continuous technique is planned, a plastic cannula (19-gauge) is introduced through the Teflon catheter and advanced up to 2-3.0 cm beyond the distal end of the Teflon catheter. This technique is preferred over the use of standard extension tubing attached to the Luer-Lok end of the catheter to avoid the possibility of pressure necrosis on the sacrum. Further, this technique allows for more flexibility in positioning the patient and stabilizing the catheter.

The needle is advanced for such a short distance beyond the sacrococcygeal ligament that we believe this technique reduces the risk of fetal-scalp injections and dural puncture. The blunt, soft end of the Teflon catheter or plastic cannula which is advanced has not been known to pierce either the dura or the fetal scalp. The catheter should never be withdrawn while the needle is in place, since this maneuver has caused portions of the catheter to be sheared off. We do not advocate the introduction of a needle in a patient in labor whose landmarks are not easily identified. It has been found that the Teflon catheter does not advance easily beyond the needle unless the needle is through the sacrococcygeal ligament and appropriately in the caudal space. It does not advance in the subcutaneous tissue overlying the sacrum without undue pressure or pain. In theory, and in our practice, this is a useful technique which is an improvement in the safety of caudal analgesia. This technique has now been used for more than 300 patients, 95 per cent of whom were obstetrical patients. Approximately 40 per cent of these patients had a continuous technique. There has been no failure to achieve caudal analgesia providing the Teflon catheter has been easily advanced into the sacral epidural space. There has been no broken needle or catheter. If the data published by Dawkins¹ were applied to

our series, one would anticipate having experienced three dural punctures. Instead, no dural puncture or fetal-scalp injection was encountered, and there has been no rectal injection.

REFERENCES

1. Dawkins CJM: An analysis of the complications of extradural and caudal block. *Anaesthesia* 24:554-563, 1969
2. Sinclair JC, Fox HA, Lentz JF, et al: Intoxication of the fetus by a local anesthetic. A

newly recognized complication of maternal caudal anesthesia. *N Engl J Med* 273:1173-1177, 1965

3. Finster M, Poppers PJ, Sinclair JC, et al: Accidental intoxication of fetus with local anesthetic drug during caudal anesthesia. *Am J Obstet Gynecol* 92:922-924, 1965
4. Moore DC: *Regional Block*. Fourth edition. Springfield, Ill., Charles C Thomas, 1965, pp 442-448, 455-464
5. Lofstrom B: *Illustrated Handbook in Local Anesthesia*. Edited by E Erickson. Chicago, Yearbook Medical Publishers, Inc., 1969, pp 130-133

Tracheoesophageal Fistula Following Prolonged Tracheal Intubation in a Thermally Injured Patient

STEPHEN SLOGOFF, M.D., MAJ, MC, GARY W. ALLEN, M.D., MAJ, MC,
GLENN D. WARDEN, M.D., MAJ, MC, WILLIAM F. McMANUS, M.D., MAJ, MC

Tracheoesophageal fistula formation is an increasingly frequent and often fatal complication of prolonged tracheal intubation. Meticulous care of the tracheostomy tube and assiduous management of the inflatable cuff are essential in minimizing its incidence. We present an unusual example of tracheoesophageal fistula and suggest an alternate mode of management.

REPORT OF A CASE

An 18-year-old youth sustained 56 per cent total body surface burns involving the head, neck, trunk, and upper extremities. Chest escharotomy and nasotracheal intubation performed shortly after injury relieved respiratory distress. The patient was then transferred to the United States Army Institute of Surgical Research. On admission, bilateral wheezes and rales were present and copious quantities of carbonaceous sputum were produced. A lung scan with ¹³³xenon revealed marked isotope retention bilaterally, indicative of respiratory tract damage and ventilatory impairment, corroborating the diagnosis of inhalation injury. On the fourth postburn day, continued ventilatory support was needed and a tracheostomy was performed. A 12-mm Portex tracheostomy tube with a prestretched cuff was inserted and the audible-leak technique used. Assisted ventilation was maintained with a Bird Mark XIV respirator. The first ten postburn days were complicated by intermittent upper gastrointestinal bleeding. Bilateral pulmonary infiltrates compatible with bronchopneumonia superimposed on

the inhalation injury developed. Blood and sputum cultures yielded *Pseudomonas aeruginosa*.

The patient was supported by nasogastric feedings and supplemental parenteral hyperalimentation. On the fifteenth postburn day, the pulmonary infiltrates partially cleared and he tolerated absence of respiratory assistance for 15 minutes every hour. By the eighteenth postburn day, he tolerated absence of respiratory assistance for 45 minutes of each hour and the roentgenogram of the chest showed further improvement. The upper gastrointestinal bleeding had ceased and the hematocrit was stable at 38 per cent.

Over the next few days, the patient continued to improve, but on the twenty-first postburn day, massive gastrointestinal hemorrhage recurred. Celiac artery catheterization was performed and epinephrine infused, without diminution in bleeding. A subtotal gastrectomy and vagotomy were performed using ketamine-oxygen-d-tubocurarine anesthesia. Two hours after induction of anesthesia, it was suddenly impossible to obtain a seal of the trachea with the tracheostomy cuff, and it appeared as if the balloon had ruptured. When proper position of the tube and integrity of the balloon had been verified, emergency bronchoscopy was performed; this revealed a large tracheoesophageal fistula, originating 3 cm above the carina and extending 3 cm cephalad. A Carlen's tube was inserted for the remainder of the operation. Although a seal with the tracheal balloon could not be produced, pulmonary aspiration of gastric contents was not apparent. At the conclusion of the operation, 6.5-mm nasotracheal tubes were placed through the tracheostomy stoma into each mainstem bronchus. The balloons were inflated sufficiently to maintain a seal and permit a slight leak on positive-pressure inspiration. The roentgenogram of the chest remained remarkably clear postoperatively. A moderate degree of bleed-

Received from the United States Army Institute of Surgical Research Brooke Army Medical Center, Fort Sam Houston, Texas 78234. Accepted for publication February 8, 1973.