

Clinical Observations Suggesting a Changing Site of Action during Induction and Recession of Spinal and Epidural Anesthesia

Bruno J. Urban, M.D.*

The cephalad borders of analgesia were determined 0.75 to 4 hours following the induction of spinal or lumbar epidural anesthesia. Levels thus obtained followed a straight line best described by the skin intercept of a transverse section through the trunk. They differed markedly from the dorsolaterally slanting pattern of segmental analgesia commonly associated with these blocks and observed during the onset of analgesia. There was no difference between spinal and epidural anesthesia in this regard. It is suggested that local anesthetics act first upon radicular structures and later upon structures inside the spinal cord. Because of different rates of anesthetic uptake and elimination, cord blockade becomes clinically apparent after the block of the more peripheral structures has worn off. (Key words: Local anesthetics; Anesthesia, spinal; Anesthesia, epidural; level of analgesia.)

IN TEACHING spinal and epidural anesthesia, it was observed that the cranial borders of analgesia determined after the completion of the operation followed a straight line, best described by the skin intercept of a transverse section through the trunk. This finding was unexpected, since it differs markedly from the dorsolaterally slanting pattern of segmental analgesia long associated with these blocks and customarily used to describe the extent of analgesia.¹ Since this observation apparently had not been reported, it was documented by more systematic observations.

Methods

The cranial borders of analgesia were determined in 14 patients after the completion of elective operations under spinal or epidural anesthesia. The examinations were per-

formed 0.75 to 4 hours after the last dose of the anesthetic had been administered. The criteria for patient selection were: absence of neurologic disease, cooperation of the patient, his ability to express himself in a language known to the examiner, atraumatic anesthetic technique, and lack of heavy sedation. The purpose of the repeated examinations was explained to the patients. All anesthetics were administered by supervised resident physicians. A conventional lumbar midline approach with either a single dose or a catheter technique was employed. For epidural analgesia, lidocaine, 1 per cent, or mepivacaine, 1 per cent, was used; for spinal anesthesia, tetracaine, 0.5 per cent in 5 per cent glucose, 0.1 per cent in water, was given. When epinephrine was added its concentration was 1:200,000 for epidural and 1:20,000 for spinal solutions (table 1). Preoperative medication and intraoperative sedation were administered according to clinical needs. No complications occurred during or after anesthesia.

Loss of sensation was tested by utilizing the appreciation of pin-scratch with a 25-gauge needle, always moving cranial from an anesthetized area. The examination started near the ventral midline and was repeated and extended on each side laterally and dorsally at about 1-cm intervals, thus testing the entire circumference of the trunk. The skin was marked with ink at the point at which the needle produced a painful sensation without further change in quality. This marked the transition from hypalgesia to normal sensation. The ink points were connected and the resulting line demarcating the anesthetic level recorded by description and sketches in relation to superficial landmarks. Polaroid photographs were taken of three patients. Two examinations were restricted to the ventrolateral aspects of the trunk since the patients could not be moved to the prone position at

* Assistant Professor, Department of Anesthesiology, State University of New York, Downstate Medical Center, Clarkson Ave., Brooklyn, New York 11203. Present address: Department of Anesthesiology, Duke University Medical Center, Durham, North Carolina 27710.

Accepted for publication May 15, 1973.

TABLE I. Patients, Operations, and Anesthetic Techniques

	Sex, Age (Years)	Operation	Anesthesia			Total Dose (mg)	Technique	Height Interval Block	Time of Examination (Hours)
			Agent	Agent	Agent				
Patient 1	M, 59	Transurethral resection of the prostate	Tetracaine, hyperbaric solution, with epinephrine	Tetracaine, hyperbaric solution, with epinephrine	10	Subarachnoid block	—	2.0	
Patient 2	M, 64	Transurethral resection of the prostate	Tetracaine, hyperbaric solution, with epinephrine	Tetracaine, hyperbaric solution, with epinephrine	10	Subarachnoid block	—	1.75	
Patient 3	M, 17	Pilonidal cystectomy	Tetracaine, hypobaric solution	Tetracaine, hypobaric solution	6	Subarachnoid block	—	1.5	
Patient 4	M, 68	Transurethral resection of the prostate	Tetracaine, hyperbaric solution, with epinephrine	Tetracaine, hyperbaric solution, with epinephrine	10	Subarachnoid block	—	3.5	
Patient 5*	M, 29	α-o-planting of tibia	Tetracaine, hyperbaric solution, with epinephrine	Tetracaine, hyperbaric solution, with epinephrine	12	Subarachnoid block	—	4.0	
Patient 6*	F, 28	Hysterotomy	Tetracaine, hyperbaric solution, with epinephrine	Tetracaine, hyperbaric solution, with epinephrine	12	Subarachnoid block	—	2.0	
Patient 7*	M, 51	Transurethral resection of the prostate	Tetracaine, hyperbaric solution, with epinephrine	Tetracaine, hyperbaric solution, with epinephrine	12	Subarachnoid block	—	1.5	
Patient 8*	M, 57	Orchidectomy	Tetracaine, hyperbaric solution	Tetracaine, hyperbaric solution	12	Subarachnoid block	—	1.5	
Patient 9*	M, 65	Transurethral resection of the prostate	Tetracaine, hyperbaric solution, with epinephrine	Tetracaine, hyperbaric solution, with epinephrine	12	Subarachnoid block	—	1.5	
Patient 10	F, 55	Subinguo-ophorectomy	Lidocaine, with epinephrine	Lidocaine, with epinephrine	8	Subarachnoid block	T5, T6, T7	2.25 2.75	
Patient 11	F, 30	Abdominal hysterectomy	Lidocaine, with epinephrine	Lidocaine, with epinephrine	510	Epidural block	—	1.5	
Patient 12*	F, 38	Vaginal hysterectomy	Mepivacaine	Mepivacaine	530	Epidural block	—	1.5	
Patient 13*	M, 58	Inguinal herniorrhaphy	Lidocaine, with epinephrine	Lidocaine, with epinephrine	380	Epidural block	—	0.75 2.5	
Patient 14*	M, 66	Transurethral resection of the prostate	Lidocaine, with epinephrine	Lidocaine, with epinephrine	380	Epidural block	T10, T11, T12	1.75 3.0	
			Lidocaine, with epinephrine	Lidocaine, with epinephrine	240	Epidural block	T8, T9	1.5 2.25	

* Patient also examined during induction.

† Single-dose subarachnoid block; continuous lumbar epidural block.

‡ Interval after the final dose of anesthetic was administered.

TABLE 2. Cranial Borders of Analgesia in the Ventral and Dorsal Midline while Anesthesia is Wearing Off

	Time (Hours)*	Analgesic Border†	
		Ventral Midline	Dorsal Midline
Patient 1	2.0	3.6 cm caudad of xiphisternal junction	Just cranial of T11
Patient 2	1.75	1.8 cm caudad of xiphisternal junction	T10
Patient 3	1.5	Just cranial of intermammary line	T6
Patient 4	3.5	5.4 cm caudad of xiphisternal junction	T10
Patient 5	4.0	5.4 cm cranial of umbilicus	Between L2 and L3
Patient 6	2.0	3.6 cm caudad of xiphisternal junction	Between T9 and T10
Patient 7	1.5	2.7 cm cranial of umbilicus	Between L1 and L2
Patient 8	1.5	0.9 cm caudad of umbilicus	Between L4 and L5
Patient 9	2.25	Halfway between umbilicus and xiphisternal junction	Just caudad of L1
	2.75	4.5 cm cranial of umbilicus	Between L3 and L4
Patient 10	1.5	1.8 cm caudad of suprasternal notch	T3
Patient 11	1.5	Intermammary line	Not determined
Patient 12	0.75	Xiphisternal junction	T10
	2.5	1.8 cm caudad of umbilicus	1.8 cm caudad of a line connecting the posterior iliac spines
Patient 13	1.75	1.8 cm caudad of suprasternal notch	T1
	3.0	Just caudad of xyphoid process	T12
Patient 14	1.5	7.2 cm caudad of xyphoid process	Not determined
	2.25	Just caudad of umbilicus	Just caudad of L5

* Interval after the final dose of the anesthetic was administered.

† Values given in cm are approximate, derived by converting measured fingerbreadths into centimeters.

that time. Four patients were tested twice during receding analgesia.

All examinations were done by the author. Reproducibility was checked by intermittently retesting the same area. Motor power and the modalities of touch, temperature, and proprioception were tested only cursorily. The resident physician involved in the clinical care of the patient was present during each examination to confirm the findings.

In five patients of the spinal-anesthesia group and three of the epidural-anesthesia group (table 1), the spread of analgesia was also repeatedly determined during induction (5 to 25 minutes after injection of anesthetic agent). The intervals between successive examinations were 5 to 10 minutes. A total of 24 sensory levels in eight patients was thus obtained. Only the ventrolateral aspects of the trunk were examined, sometimes only unilaterally. Time and surgical needs prohibited the simultaneous collection of further data.

Right intercostal nerve blocks were performed on three patients (Patients 9, 13, and

14, table 1) for postoperative pain relief while the anesthetic was wearing off. The resulting areas of analgesia were mapped and recorded.

Results

Analgesic levels determined while anesthesia was receding followed the same pattern after both spinal and epidural block. The cranial borders of anesthesia were sharply demarcated. Retesting at about 5-minute intervals showed them to be reproducible, never varying more than 1 cm. They encircled the body in a straight line following the boundaries of a transverse section. The intercepts of this section at the ventral and dorsal midline are listed in table 2. Because of the paucity of cutaneous landmarks on the trunk, this course was difficult to describe. However, a visually striking pattern evolved—comparable to a string tied around the trunk. This is illustrated in figures 1 and 2B and summarized in figure 3. In four patients (Patients 9, 12, 13, 14), retesting at a later time showed borders caudad and paral-

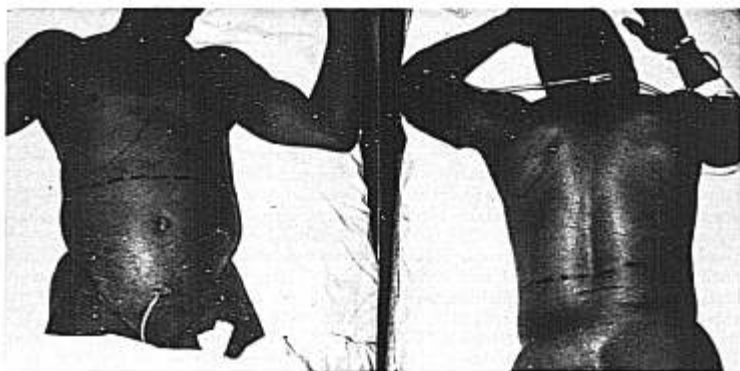


FIG. 1. Unretouched Polaroid photographs of Patient 9. The costal margins and the inferior borders of the scapulae have been marked on the skin (thin solid lines). The heavy interrupted line shows the cephalad borders of analgesia 2.25 hours after initiation of spinal anesthesia. Note the transverse course of the demarcation encircling the trunk. The level of anesthesia after 20 minutes is also marked anteriorly (heavy solid line).

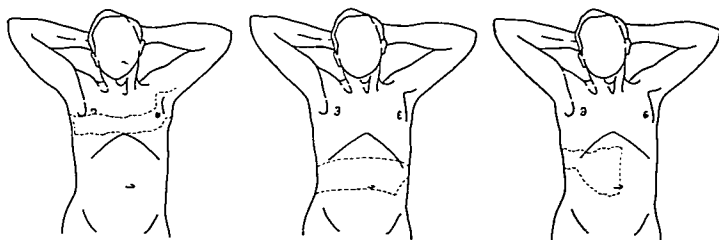


FIG. 2. Borders of analgesia obtained in the Patient 14 during induction and recession of lumbar epidural anesthesia and following intercostal nerve block. Line drawings after Polaroid photographs; the lower thoracic aperture and the iliac ligaments are outlined with solid lines. A (left), cephalad borders of analgesia 7 minutes (caudal interrupted line) and 22 minutes (cranial interrupted line) after induction of epidural anesthesia. B (center), cephalad borders of analgesia 1.5 hours (cranial interrupted line) and 2.25 hours (caudal interrupted line) after the last epidural injection. On the left lateral trunk a patch of analgesia in the area of the tenth thoracic dermatome protrudes cranially from the otherwise ring-shaped level at 2.25 hours. C (right), area of analgesia following block of the eighth and ninth intercostal nerves in the posterior axillary line.

rel to the previously established ones (fig. 3, table 2). In the two patients (Patients 11 and 14, first examination) in whom the intercept with the dorsal midline could not be determined, the anesthetic margins up to the posterior axillary line demonstrated the same straight course. In one patient (Patient 13,

first examination), analgesia was found to encompass the ulnar aspects of the upper extremities, and in another (Patient 14, second examination) a patch of analgesia in the area of the tenth thoracic dermatome on the left abdomen and flank extruded cranially from the otherwise-ringshaped margins (fig. 2B).

During induction the anterolateral margins of analgesia substantiated a from-dorsal-to-ventral and from-craniad-to-caudad slanting course. The obliquity of the boundaries was most pronounced at the lateral aspect of the trunk, becoming more horizontal anteriorly (fig. 2A). In the lower thoracic segments the borders curved craniad when nearing the ventral midline, producing a hump-like appearance. The analgesic areas produced by intercostal nerve block followed the distribution of the appropriate nerves. The craniad and caudad borders were likewise inclined caudad at the lateral trunk and became horizontal ventrally. The medial margin coincided with the ventral midline (fig. 2C). Both the margins of induction and intercostal block were in accordance with the classic schemata of segmental innervation (fig. 4) and at variance with the horizontal boundaries of receding anesthesia (fig. 3), crossing them in an oblique fashion at the lateral aspects of the trunk.

Discussion

Pin-scratch is a sensitive method of delineating an area of sensory loss. Analgesic areas thus mapped are discrete and distinguish well between different nerves or spinal segments.^{2,3} Technically, the method is limited by the examiner's judicious use of the applied pressure and by the patient's sensitivity to pain stimulation. Experience enables one quickly to determine the proper pressure for a given individual, especially when using the scratch test instead of skin pricking.² Further limiting factors of this test include the cooperation of the patient and the time consumed by the examination.

This study reports only results from alert, cooperative patients whose appreciation of pain was not altered by intra- or postoperative sedation. It was mainly confined to investigating the cephalad borders of the receding block, since the time needed for the examination may impede the accurate determination

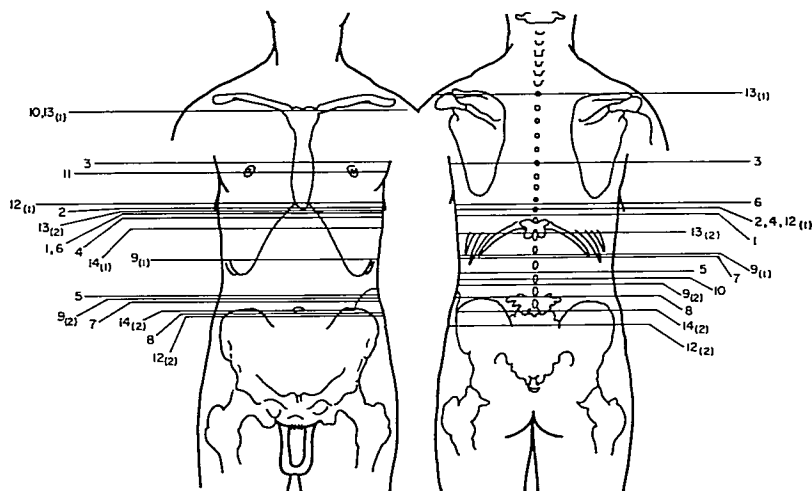
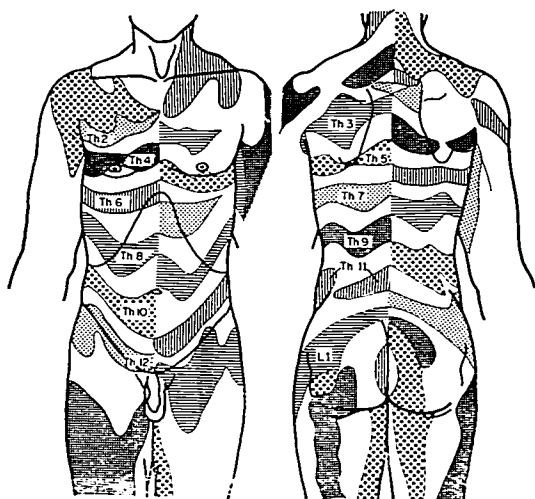


FIG. 3. Cephalad borders of receding analgesia (straight solid lines) obtained from 14 patients following spinal or epidural anesthesia. The subscripts 1 and 2 denote the first and second examinations. For details about patients identified by the numbers see table 1.

FIG. 4. Chart of thoracic dermatomes in man according to Head.^{2,4,15} The oblique course (craniad-to-caudad, dorsal-to-ventral) is most pronounced laterally, becoming more horizontal ventrally and dorsally and reversing to a craniad slant near the ventral midline.



of fast-changing sensory borders. For instance, the segmental spread of analgesia following the initiation of spinal anesthesia may be exaggerated when the examination advances from the midline laterally. Decreasing the number of determinations will speed up the examination but produce an approximation of level. Within these limits we confirmed the traditional segmental spread of analgesia during induction, occasionally even delineating the hump near the ventral midline in the lower thoracic segments.⁴ In contrast to induction, the slow decay of subarachnoid and epidural block lends itself to meticulous investigation. Here, the level by pin-scratch could be checked by retesting and could validate the method as accurate and reproducible.

The mechanisms of spinal and epidural anesthesia were subjected to extensive review recently.^{5,6} Practically all neural structures inside the vertebral canal have been proposed as anatomic sites for local anesthetic action. The most likely site of block, initially, seems to be confined to the areas of distal root, spinal ganglion, and nerve.^{8,9} Blocking these structures in the thoracic region will produce cu-

aneous analgesia in the distribution of the uniradicular intercostal nerves¹⁰ which closely correspond to Head's chart of segmental innervation¹¹ (fig. 4). Clinically, analgesia of segmental distribution has been ascribed to spinal and epidural block,^{1,12} and special techniques of segmental blockade¹³⁻¹⁴ are based on this feature.

If only one mechanism of action existed one would expect the receding block to resemble a mirror image of induction. The observed straight ring-shaped margins of analgesia, however, do not match the boundaries of segmental innervation, but cut sagittally across the dermatome. This is best demonstrated by comparing figures 1-3 with a chart of segmental innervation based upon radicular lesions^{2,4,15} (fig. 4). The difference seen cannot be explained by nonconduction in the spinal nerve or its ganglion and root.

It is conceivable that anesthetic concentrations in cerebrospinal fluid diminishing craniad might leave only the caudad half of the filaments from one segment anesthetized and thus produce an analgesic border transversing the dermatome. However, the reversal of

anesthesia is not determined by the decreased anesthetic concentration in cerebrospinal fluid.¹⁶ In addition, the nerve fibers emerging through the fila radicularia innervate the whole dermatome in the diffuse fashion. Section of half of the filaments of one spinal root results not in a smaller or differently shaped area of cutaneous analgesia, but in changed perception and hyperalgesia of the whole dermatome.¹⁷

Since block of both peripheral and radicular structures cannot explain the transverse margins of waning anesthesia, an alternative hypothesis must be considered. The only remaining possibility consists in the assumption that both receding spinal and receding epidural anesthesia exert their main effects upon structures inside the spinal cord. Clinically, this view is supported by the occasional observations that posterior myelotomies result in an area of analgesia with similar straight transverse margins surrounding the body like a belt (Cook, A. W., personal communication). Further supportive evidence is derived experimentally from work in the dog.^{18-19,20} Depression of induced spinal cord potentials comparable to the depression seen after epidural block was found after subarachnoid injection of procaine,¹⁸ and uptake of radioactively labeled local anesthetics into the cord was demonstrated to occur following epidural¹⁹ and spinal²⁰ anesthesia.

A dual mechanism—valid for spinal and epidural anesthesia alike—is postulated, based upon different anatomic sites of blockade with different onsets and durations of anesthetic action. Anesthesia starts by interrupting the radicular structures, but with time affects structures inside the cord as well. This results in an initial segmental pattern of analgesia during induction. As block of root, ganglion, and spinal nerve wears off, cord blockade becomes clinically manifest by the ring-shaped borders of analgesia observed. We have no basis on which to postulate any specific anatomic site of action inside the cord. One may only speculate upon such a site in the structures affecting neural transmission in the dorsal horn, where autoradiographic examination has shown that a selectively high concentration of local anesthetic accumulates.²⁰

Occasionally peripheral block may last longer than anesthesia of the cord. This happened when a patch of analgesia persisted in the left tenth dermatome in Patient 14. Here, an intense paravertebral block—probably resulting from the proximity of the epidural catheter to the left tenth spinal nerve—had been produced in addition to epidural anesthesia.

The proposed hypothesis contains the additional concept that segmental organization of the spinal cord differs from the dermatomes outlined by uniradicular nerves. It may be speculated that cord structures maintain a phylogenetically older projection to the periphery, although this has been distorted during evolution of the species as the individual nerve fibers travel in the peripheral nerve to its cutaneous distribution. No data describing the extent of segmental organization of the cord and its correlation with the radicular segments are available.

The author gratefully acknowledges the advice and criticism of Dr. B. D. King, Professor of Anesthesiology, State University of New York, Downstate Medical Center, and the stimulating and encouraging discussions with Dr. A. W. Cook, Professor of Neurosurgery, State University of New York, Downstate Medical Center.

References

1. Dogliotti AM: Anesthesia. Chicago, S. B. Debour, 1939, pp 499-625
2. Keegan JJ, Garrett FD: The segmental distribution to the cutaneous nerves in the limbs of man. *Anat Rec* 102:409-437, 1948
3. Hansen K, Schliack H: Ueber Segmentinnervation, Headsche Zonen und Metamerie. *Nervenarzt* 28:469-474, 1957
4. Head H, Campbell AW: The pathology of herpes zoster and its bearing on sensory localisation. *Brain* 23:353-523, 1900
5. Greene NM: Physiology of Spinal Anesthesia. Second edition. Baltimore, Williams and Wilkins, 1969
6. Bromage PR: Physiology and pharmacology of epidural analgesia. *ANESTHESIOLOGY* 28: 592-622, 1967
7. Vandam LD: Spinal anesthesia, *Anesthesiology*. Second edition. Edited by DE Hale. Philadelphia, F. A. Davis, 1963, pp 499-549
8. Frumin MJ, Schwartz H, Burns JJ, et al: Sites of sensory blockade during segmental spinal and segmental peridural anesthesia in man. *ANESTHESIOLOGY* 14:576-583, 1953

9. Frumin MJ, Schwartz H, Burns J, et al: Dorsal root ganglion blockade during threshold segmental spinal anesthesia in man. *J Pharmacol Exp Ther* 112:387-392, 1954
10. Dejerine J: *Sémiologie des affections du système nerveux*. Paris, Masson et Cie., 1914, pp 792-939
11. Elze C: Die anatomischen Grundlagen der Headschen Zonen. *Z Anat Entwicklungsgesch* 122:402-413, 1961
12. Bromage PR, Burfoot MF, Crowell DE, et al: Quality of epidural blockade. I: Influence of physical factors. *Br J Anaesth* 36:342-352, 1964
13. Saklad M, Dwyer CS, Kronenberg S, et al: Intraspinial segmental anesthesia: A preliminary report. *ANESTHESIOLOGY* 8:270-287, 1947
14. Dogliotti AM: A new method of block anesthesia. Segmental peridural spinal anesthesia. *Am J Surg* 20:107-118, 1933
15. Foerster O: Symptomatologie der Erkrankungen des Rückenmarks und seiner Wurzeln, *Handbuch der Neurologie*. Band V. Edited by O Bumke, O Foerster. Berlin, Springer Verlag, 1936, pp 64-380
16. Converse JG, Landmesser CM, Harmel MH: The concentration of pontocaine hydrochloride in the cerebrospinal fluid during spinal anesthesia, and the influence of epinephrine in prolonging the sensory anesthetic effect. *ANESTHESIOLOGY* 15:1-10, 1954
17. Winkler C: Ueber Rumpfermatome. Ein experimenteller Beitrag zur Lehre der Segmental-Innervation der Haut. *Monatsschr Psychiat Neurol* 13:161-176, 1903
18. Rudin DO, Fremont-Smith K, Beecher HK: Permeability of dura mater to epidural procaine in dogs. *J Appl Physiol* 3:388-398, 1951
19. Bromage PR, Joyal AC, Binney JC: Local anesthetic drugs: Penetration from the spinal extradural space into the neuraxis. *Science* 140:392-394, 1963
20. Cohen EN: Distribution of local anesthetic agents in the neuraxis of the dog. *ANESTHESIOLOGY* 29:1002-1005, 1968

Neonatology

RDS WITH PDA Hypoxia, prematurity and respiratory distress in the neonate may be associated with delayed closure of the ductus arteriosus. In the neonate with congestive failure, such delayed closure may result in large left-to-right shunts. Four female neonates weighing between 1 and 2 kg required mechanical ventilation for the respiratory distress syndrome. Each developed congestive cardiac failure which responded poorly to maximum drug therapy, and each was unable to have ventilatory support withdrawn. A patent ductus arteriosus was diagnosed and then ligated under anesthesia. In each case, rapid control of the cardiac failure occurred and withdrawal of mechanical ventilation was possible. One patient died of bronchopulmonary dysplasia, and the other three survived. Postoperative ventilation was continued for three days in the survivors. The diagnosis of patent ductus arteriosus can usually be made on clinical grounds: the location of a systolic or continuous murmur in the second or third interspace to the left of the sternum, associated with a wide pulse pressure. (*Gupta, J. M., and others: Ductus Ligation in Respiratory Distress Syndrome. J. Thorac. Cardiovasc. Surg.* 63: 642-647, 1972.)

EDITOR'S COMMENT: Clinical and x-ray diagnosis of pulmonary edema associated with a paradoxically high Pa_{O_2} , regardless of $F_{I_{O_2}}$, should always raise the suspicion of a left-to-right shunt, irrespective of its site. The problem in postoperative management is the persistent pulmonary edema. In fact, Pa_{O_2} may drop sharply once the left-to-right shunt is corrected (*i.e.*, PDA ligated) due to inefficient oxygenation at the pulmonary level.