

## Epidural Hematoma and Paraplegia after Numerous Lumbar Punctures

SAMUEL M. LERNER, M.D.,\* PAUL GUTTERMAN, M.D.,† FELIX JENKINS, M.D.†

Lumbar puncture for attempted spinal anesthesia caused an epidural hemorrhage with cord compression and permanent neurologic damage in a patient with normal blood coagulation. Intraspinous hematoma formation and subsequent paraplegia have been reported to occur after spinal anesthesia in a patient with a blood dyscrasia,<sup>1</sup> after continuous epidural anesthesia in a heparinized patient,<sup>2</sup> after lumbar puncture in a leukemic child,<sup>3</sup> after trauma to the vertebral column,<sup>4,5</sup> and spontaneously.<sup>6-8</sup> To our knowledge, no instance of spinal epidural hematoma following lumbar puncture in a patient whose blood coagulation is normal has previously been reported.

### REPORT OF A CASE

A 70-year-old woman was admitted to a suburban hospital with osteomyelitis of the right knee. Past medical history was noncontributory. The patient was taken to the operating room, where numerous lumbar punctures were made with a 22-gauge needle in an unsuccessful attempt at spinal anesthesia. Bloody fluid was obtained in the needle on at least one occasion. The attempt at spinal anesthesia was abandoned and the operation was performed using general anesthesia, without incident. Approximately 20 hours postoperatively, the patient complained of inability to move her lower extremities. Neurosurgical consultation was obtained and she was transferred to Episcopal Hospital.

On admission, the patient was alert and cooperative but complained of lumbar pain with radiation into the inguinal region bilaterally. General physical examination disclosed no abnormality except a surgical wound of the right knee. Neurologic examination showed flaccid paraplegia with total anesthesia below L1. Laboratory studies were within normal limits. The platelet count was 260,000/mm<sup>3</sup>; fibrinogen level and clot retraction were normal; prothrombin time was 15.7 seconds, compared with a control value of 13.5 seconds.

\* Associate Professor of Anesthesiology, Temple University Medical School, and Director of Anesthesiology, Episcopal Hospital, Philadelphia, Pennsylvania.

† Attending Neurosurgeon, Episcopal Hospital.

† Senior Resident in Neurosurgery, Episcopal Hospital.

Accepted for publication April 4, 1973.

Lumbar puncture for myelography at a level caudad to the previous puncture sites was unsuccessful. Cervical myelography demonstrated block at L1.

Laminectomy was performed approximately 36 hours after the onset of symptoms. Anesthesia consisted of thiopental, nitrous oxide-oxygen, and *d*-tubocurarine. A complete laminectomy was performed from T11 to L3 inclusive, and well-formed clots were evacuated from the epidural space. No other abnormality was found to account for the hematoma.

The patient's motor and sensory deficits did not improve postoperatively. Bladder and bowel control did not return, and she was treated with daily enemas and catheterization. The patient was transferred to a rehabilitation facility where, after four months, she regained only minimal function of her quadriceps femoris on the left side.

### DISCUSSION

In an exhaustive review of the neurologic sequelae of spinal anesthesia, Greene<sup>9</sup> recorded no instance of neural damage caused by hematoma formation and subsequent cord compression.<sup>9</sup> Neither Vandam and Dripps,<sup>10-12</sup> in their series of 10,098 spinal anesthetics, nor Moore and Bridenbaugh,<sup>13</sup> in their series of 11,574 cases, reported epidural hematoma as a complication of lumbar puncture.

In the present case, it appears that numerous lumbar punctures in a patient with a normal blood clotting mechanism produced an epidural hematoma, with cord compression and widespread neurologic damage. The operative findings of a large epidural hematoma compressing the spinal cord and cauda equina indicate that laceration of one or more epidural veins by an exploring spinal needle was primarily responsible for the neurologic damage.

Epidural hematoma should be suspected when lumbar puncture is followed by persistent severe pain in the lumbar region, flaccid motor weakness, and sensory loss. A diagnostic lumbar puncture is indicated, and myelography should be attempted. If lumbar myelography is unsuccessful owing to collapse of the subarachnoid space by the hematoma,

cisternal or lateral cervical myelography should be undertaken. Prompt surgical exploration and decompression of the spinal cord and cauda equina may prevent permanent neurologic damage.

REFERENCES

1. Bonica JJ: The Management of Pain. First edition. Philadelphia, Lea and Febiger, 1953, p 493
2. Gingrich TF: Spinal epidural hematoma following continuous epidural anesthesia. ANESTHESIOLOGY 29:162-163, 1968
3. Wolcott CJ, Grunner ML, Lakey ME: Spinal subdural hematoma in the leukemic child. J Pediatr 77:1060-1062, 1970
4. Rader JP: Chronic subdural hematoma of the spinal cord. N Engl J Med 253:374-376, 1955
5. Stewart DH, Watkins ES: Spinal cord compression by chronic subdural hematoma. J Neurosurg 31:80-82, 1969
6. Cloward RB, Yuhl ET: Spontaneous intraspinal hemorrhage and paraplegia complicating

- dicumarol therapy. Neurology 5:600-602, 1955
7. Hughes JT: Pathology of the Spinal Cord. Chicago, Year Book Medical Publishers, 1968, pp 52-54
8. Markham JW, Lyngne HW, Stahlman EBS: The syndrome of spontaneous spinal epidural hematoma, report of 3 cases. J Neurosurg 26:334-342, 1967
9. Greene NM: Neurological sequelae of spinal anesthesia. ANESTHESIOLOGY 22:682-698, 1961
10. Dripps RD, Vandam LD: Long term follow-up of patients who received 10,098 spinal anesthetics. JAMA 156:1486-1491, 1954
11. Vandam LD, Dripps RD: Exacerbation of pre-existing neurologic disease after spinal anesthesia. N Engl J Med 255:843-849, 1956
12. Vandam LD, Dripps RD: Long term follow-up of patients who received 10,098 spinal anesthetics; Neurological disease incident to traumatic lumbar puncture during spinal anesthesia. JAMA 172:1483-1487, 1960
13. Moore DC, Bridenbaugh LD: Spinal (subarachnoid) block. JAMA 195:907-912, 1966

### The Use of Nitrous Oxide during Ventilation with the Open Bronchoscope

EDWARD CARDEN, M.A., M.B., B. CHIR., FRCP(C),\* AND WAYNE B. SCHWESINGER, M.D.†

Since the report by Sanders in 1967,<sup>1</sup> oxygen injectors attached to bronchoscopes have

become widely used during anesthesia for bronchoscopy. The technique allows the endoscopist to operate with the proximal end of the bronchoscope open while the patient's lungs are mechanically ventilated with a mixture of air and oxygen. In 1970, we proposed using the sidearm of the older type of Chevalier-Jackson bronchoscope as the route for injecting oxygen down the bronchoscope.<sup>2</sup> By utilizing the wide bore of the sidearm (ap-

\* Assistant Professor, Department of Anesthesiology.

† Resident, Department of Surgery. Received from the University of North Carolina School of Medicine, Chapel Hill, North Carolina 27514. Accepted for publication March 27, 1973.

Requests for reprints should be sent to: Dr. Edward Carden, Department of Anesthesiology, North Carolina Memorial Hospital, Chapel Hill, North Carolina 27514.

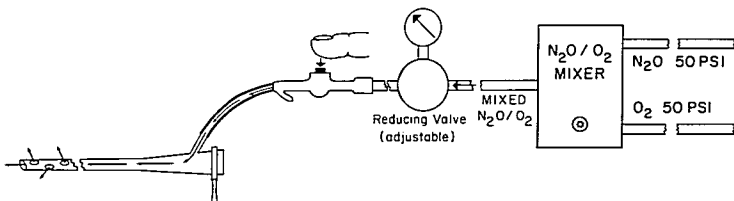


FIG. 1. Schematic representation of the ventilation system.

Downloaded from <http://pubs.asanet.org/> by guest on 07 July 2022