

In conclusion, simultaneous brachial and femoral blood pressure monitoring has shown that femoral hypotension becomes manifest with greater frequency than brachial hypotension when the term-pregnant woman lies supine. Since decreased femoral blood pressure is indicative of lower aortic obstruction, uterine displacement should be undertaken whenever a woman in the last trimester must assume the supine position, regardless of whether brachial pressure declines.

REFERENCES

- Howard BK, Goodson JH, Mengert WF: Supine hypotensive syndrome in late pregnancy. *Obstet Gynecol* 1:371-377, 1953
- Bieniarz J, Crottogini JJ, Curuchet E, et al: Aorto-caval compression by the uterus in late human pregnancy. II. An arteriographic study. *Am J Obstet Gynecol* 100:203-217, 1968
- Lees MM, Scott DB, Kerr MG, et al: Circulatory effects of the supine posture in late pregnancy. *Clin Sci* 32:453-465, 1967
- Goodlin RC: Importance of the lateral position during labor. *Obstet Gynecol* 37:698-701, 1971
- Cappe BE, Surks SN: Inferior vena cava syndrome in late pregnancy. *Am J Obstet Gynecol* 79:162-163, 1960
- Colon-Morales MA: A self-supporting device for continuous left uterine displacement during cesarean section. *Anesth Analg (Cleve)* 49: 923-924, 1970
- Kennedy RL: An instrument to relieve inferior vena cava occlusion. *Am J Obstet Gynecol* 107:331-333, 1970
- Goodlin RC: Aortocaval compression during cesarean section. A cause of newborn depression. *Obstet Gynecol* 37:702-705, 1971
- Akamatsu TJ: Personal communication

Efficacy of Cricoid Pressure in Preventing Gastric Inflation during Bag-Mask Ventilation in Pediatric Patients

M. R. SALEM, M.D.,* A. Y. WONG, M.D.,† M. MANI, M.D.,‡
B. A. SELICK, M.B., B.S., F.F.A.R.C.S.‡

The use of cricoid pressure to control regurgitation of gastric contents during induction of anesthesia in the adult patient with a full stomach has been described by Sellick.¹ He also suggested using the maneuver to prevent inflation of the stomach during positive-pressure ventilation applied through a face mask or by mouth-to-mouth respiration. The maneuver consists of tem-

porary occlusion of the upper end of the esophagus by backward pressure of the cricoid ring against the bodies of the cervical vertebrae.^{1,2} Recently, in a study in infant cadavers, the maneuver was found effective in preventing reflux at intraesophageal pressures of 100 cm H₂O.²

The efficacy of cricoid pressure in preventing regurgitation has encouraged us to evaluate a modified maneuver in preventing gastric inflation during bag-mask ventilation in pediatric patients. It was postulated that in this situation gentle rather than firm pressure would be desirable for two reasons: first, gentle pressure is all that is necessary to prevent intermittent opening of the esophagus at the commonly employed airway pressures, and second, firm pressure may interfere with airway patency in infants.

* Associate Director, Department of Anesthesiology, Cook County Hospital, Chicago, Illinois 60612.

† Attending Physician, Division of Pediatric Anesthesiology, Cook County Hospital, Chicago, Illinois 60612.

‡ Attending Physician, Department of Anesthesiology, Cook County Hospital, Chicago, Illinois 60612.

§ Consultant Anaesthetist, The Middlesex Hospital, London, W. 1, England.

Accepted for publication June 27, 1973.

METHODS

Ten patients between the ages of 3 months and 5 years, undergoing elective surgical procedures, were studied. None had any known gastrointestinal or respiratory disease. Anesthesia was induced and maintained with halothane in oxygen, using a circle absorber system. An oropharyngeal airway was inserted. Complete muscular paralysis during the study period was achieved with a succinylcholine infusion or by intravenous injections of *d*-tubocurarine.

The patients were then subjected to two periods of intermittent positive-pressure ventilation, each lasting 2 minutes. In one period, IPPV was used without cricoid pressure, thus serving as control, while in the other period, gentle cricoid pressure was exerted by an assistant. A stomach tube was initially introduced via the mouth prior to each test period to ensure gastric emptying. Immediately after each period, the stomach tube was reinserted and the volume of gases that could be aspirated was measured.

During the study period, intermittent positive-pressure ventilation was carried out via a tight-fitting face mask by means of an Air Shields Ventimeter Ventilator with a pediatric attachment. Minute ventilation was one and a half times that calculated from a standard nomogram. Respiratory frequency varied between 12 and 20/min. The ventilator settings were unaltered during the study period. The volume of exhaled gases in

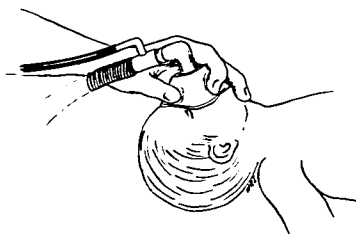


FIG. 1. Cricoid pressure applied with the middle finger during bag-mask ventilation of a child.

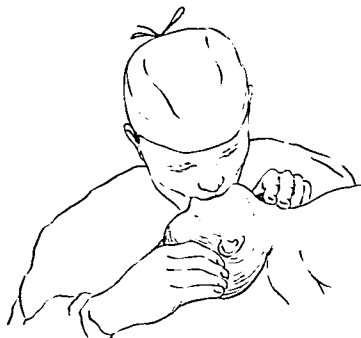


FIG. 2. Application of gentle cricoid pressure during mouth-to-mouth resuscitation.

TABLE I. Individual Data on IPPV with and without Cricoid Pressure*

Patient's Age	Peak Airway Pressure (cm H ₂ O)	Gas Volume in Stomach ml/2 Minutes		Difference in Stomach Gas Volumes (ml) (Control-Cricoid Pressure)	Difference in Exhaled Volumes (ml) (Cricoid Pressure-Control)
		Control	Cricoid Pressure		
3 mo	24	152	25	127	120
18 mo	25	315	.0	315	300
2 yr	22	144	26	118	100
2 yr	22	150	41	109	110
2 yr	21	18	0	18	20
3 yr	20	170	10	160	150
4 yr	21	50	3	47	50
4 yr	19	0	0	0	0
5 yr	22	605	5	600	520
5 yr	20	15	5	10	10

* Differences between values in columns three and four are significant.

each period was measured with a Wright's Respirometer and the peak airway pressures were monitored by a pressure gauge.

RESULTS

In most patients, bag-mask ventilation for a 2-minute period, without cricoid pressure, resulted in appreciable accumulation of gases in the stomach (table 1). The volumes of exhaled gases during the application of cricoid pressure tended to show slight increases compared with control values. The difference between stomach gas volumes in the two periods was approximately equal to the difference between exhaled volumes (cricoid-pressure period-control period) in each patient (table 1).

DISCUSSION

Gastric inflation is a problem frequently encountered during bag-mask ventilation and mouth-to-mouth resuscitation in pediatric patients. The problem becomes manifest when high airway pressures are used. Laryngeal obstruction and relaxation of the cricopharyngeal sphincter by neuromuscular blocking drugs or deep anesthesia are important contributing factors.³

The present investigation indicates that the simple maneuver of gentle cricoid pressure

is effective in reducing gastric distention during bag-mask ventilation without interfering with its adequacy. Exhaled volumes were greater during IPPV with cricoid pressure because gases were prevented from entering the esophagus and escaping into the stomach.

Use of cricoid pressure during IPPV should not be regarded as a substitute for tracheal intubation, but rather as an alternative in certain situations. It is useful when bag-mask ventilation is carried out for short periods or until tracheal intubation is accomplished. It may be performed by the anesthesiologist, using the middle or little finger of the hand holding the mask while the neck is kept extended (fig. 1). The maneuver has similarly been utilized during mouth-to-mouth resuscitation in pediatric patients. The operator exerts gentle pressure on the cricoid ring using the flat of his index finger during inflation (fig. 2).

REFERENCES

1. Sellick BA: Cricoid pressure to control regurgitation of stomach contents during induction of anaesthesia. *Lancet* 2:404-406, 1961
2. Salem MR, Wong AY, Fizzotti GF: Efficacy of cricoid pressure in preventing aspiration of gastric contents in paediatric patients. *Br J Anaesth* 44:401-404, 1972
3. Salem MR: Anesthetic management of patients with "a full stomach." A critical review. *Anesth Analg (Cleve)* 49:47-55, 1970

CNS Function

BRAIN PERFUSION No predictable relationship was found between neurologic state, intracranial pressure (ICP) and cerebral blood flow (CBF) in patients comatose secondary to head injury. In patients with an intracranial mass, the extents of autoregulation varied among patients and among different cerebral areas in the same patient. In the absence of a mass, autoregulation was intact in 50 per cent of patients. When autoregulation was impaired, ICP increased little with increasing systemic arterial pressure (SAP), nor was there any correlation between the presence of intact autoregulation and survival. Mannitol increased CBF, lowered ICP and increased cerebral perfusion pressure (CPP).

However, the increased CPP did not correlate with the increase in CBF or the increase in cerebral oxygen consumption. As the injury progressed to "brain death" (*Balslev-Jorgensen, P., and others: Cerebral Perfusion Pressure Correlated with Regional Cerebral Blood Flow, EEG and Aortic Cervical Arteriography in Patients with Severe Brain Disorders Progressing to Brain Death, Europ. Neurol.* 8: 207-212, 1972), mean ICP increased to and remained at or above mean SAP. The shape of the ICP wave was now identical to that of the SAP wave. At this stage, all clinical and EEG signs of brain function disappeared and CPP was zero. (*Brucc, D. A., and others: CBF and Intracranial Pressure in Comatose Patients. Europ. Neurol.* 8: 200-206, 1972.)