

## Clinical Workshop

C. PHILIP LARSON, JR., M.D., *Editor*

### A Comparison of the Effects of Intravenous Innovar and Topical Spray on the Laryngeal Closure Reflex

C. J. KOPRIVA, M.D.,\* R. J. ELTRINGHAM, M.B., Ch.B., F.F.A.R.C.S.† P. E. SIEBERT, M.D.‡

To minimize the hazard of aspiration of gastric contents in the patient with a full stomach presenting for operation, awake endotracheal intubation is often performed before anesthesia is induced. This can be accomplished after spraying the tongue, posterior pharynx, and valleculae with topical anesthetic, but the procedure is unpleasant for the patient and technically difficult for the anesthesiologist. Hence, intravenous administration of Innovar has been recommended to facilitate "awake" intubation.<sup>1,2</sup> However, it is possible that the use of Innovar may depress the laryngeal closure reflex, causing a greater incidence of aspiration than when topical anesthesia is used. This study was designed to determine whether the use of Innovar prior to intubation would lead to a greater incidence of aspiration than topical anesthesia.

#### METHODS

The protocol was approved by the Human Research Committee. Patients with histories of iodide sensitivity, chronic pulmonary disease, Parkinson's disease, or esophageal disease were excluded, as were patients for whom succinylcholine was contraindicated or pre- or postoperative coughing was un-

desirable. Each patient was visited the day before the operation, and informed consent was obtained. Thirty healthy fasting patients scheduled for elective operations requiring endotracheal anesthesia were selected. None was premedicated. The patients were divided into two groups. On the patient's arrival in the operating room, atropine, 0.6 mg, was given intravenously.

Group I included 12 patients who were given Innovar intravenously at a rate of 1 ml every 2½ minutes until the larynx could be easily visualized using a laryngoscope. During this time they were actively encouraged to breathe to counteract respiratory depression. After laryngeal visualization, the laryngoscope was removed and an oily suspension of propylidone (Dionosil), 15 ml, was injected into the pharynx to challenge the competence of the laryngeal closure reflex. Within 30 seconds of dye injection a roentgenogram of the chest and larynx was taken. The trachea was then intubated and anesthesia continued using a variety of techniques.

Group II included 18 patients who received topical anesthesia to the tongue, vallecula, and upper surface of the epiglottis with Cetacaine spray.‡ More extensive anesthesia of the larynx, e.g., percutaneous, transoral, or superior laryngeal block, was not employed, as it has been shown to allow aspiration of gastric contents.<sup>3</sup> In three patients a satisfactory view of the larynx could not be obtained, and in three others attempts at visualization were abandoned when the pa-

\* Chief, Department of Anesthesiology, Veterans Administration Hospital, Denver, Colorado.

† Instructor in Anesthesiology, University of Colorado Medical Center, Denver, Colorado.

‡ Associate Professor of Radiology, University of Colorado Medical Center, Denver, Colorado.

Accepted for publication January 17, 1974. Supported in part by V.A. Research Grant 5019-01.

§ An anesthetic solution containing tetracaine, 2 per cent, and benzocaine, 14 per cent.

tients found them stressful. In the remaining 12 patients an unobstructed view of the vocal cords could be maintained for 5 seconds, and intubation was considered possible. After visualization, the laryngoscope was removed; propylidone, 15 ml, was then introduced into the pharynx as in the first group, and a roentgenogram was taken within 30 seconds. Subsequently, general anesthesia was induced. All roentgenograms were evaluated by the same radiologist, who was unaware of the drugs administered to the patients.

### RESULTS

The average ages of the patients in the two groups were similar, being 45 years (range 22-61 years) in Group I (Innovar) and 44 years (range 22-66 years) in Group II (topical). In Group I the average amount of Innovar needed before patients tolerated laryngeal exposure was 6.5 ml (range 4-8 ml). In three patients systolic blood pressure decreased by more than 10 mm Hg but rapidly returned to normal with the administration of fluids intravenously. All Group I patients reacted with a cough on introduction of the contrast medium. Nevertheless, four patients had radiologic evidence of aspiration. In two cases, contrast medium was in the upper trachea (fig. 1), and in two cases it had reached the major bronchi (fig. 2). All four patients who aspirated contrast medium developed mild coughs for two days postoperatively, and two developed slight fevers. There were no other sequelae in these four, and the remaining eight patients were asymptomatic. All Group II patients reacted with a cough upon introduction of the contrast medium. However, in no case was there radiologic evidence of aspiration, nor was any cough or fever seen postoperatively. The incidence of aspiration in the Innovar group was significant; comparison of the two groups using Fisher's Exact Test gave  $P < 0.048$ .

### CONCLUSION

The tracheas of all 12 patients sedated with Innovar could be successfully intubated while the patients remained cooperative. In the sedated state, all reacted with a cough

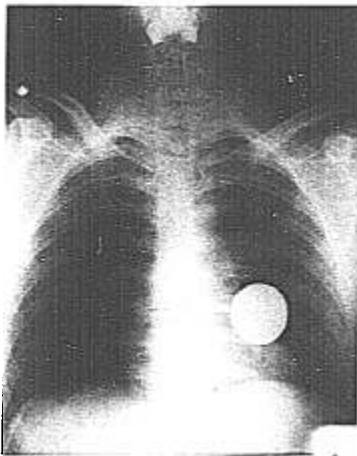


FIG. 1. Aspiration into the upper trachea after Innovar.

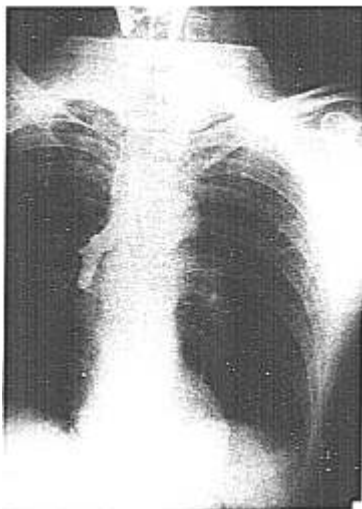


FIG. 2. Aspiration into the right main bronchus after Innovar.

when contrast medium was introduced into the pharynx and again when the endotracheal tube was placed. This initially gave the impression that the laryngeal closure reflex was intact, and seemed to confirm the findings of Claeys,<sup>5</sup> who used smaller amounts of Innovar. However, radiologic examination showed that four of the 12 patients had aspirated the contrast medium and that the integrity of the laryngeal closure reflex could not be relied upon.

In Group II, patients who received topical anesthesia, laryngeal exposure was achieved in 12 of 18 patients. In these 12 patients contrast medium introduced into the pharynx was not aspirated. This would therefore seem to be a safer procedure for intubating the trachea of a patient with a full stomach. But, because it is technically difficult for the anesthesiologist and unpleasant for the patient, intravenous sedation may be desirable. If Innovar is used to facilitate "awake"

intubation, it should be given in minimal amounts and with the knowledge that the risk of aspiration may be higher than when topical anesthesia only is used.

The authors thank P. J. Cohen, M.D., for advice and criticism in the preparation of this article.

#### REFERENCES

1. Fox JWC, Fox EJ: Neuroleptanalgesia: A review. *NC Med J* 27:471-475, 1966
2. Fox JWC, Fox EJ, Crandell DL: Neuroleptanalgesia for heart and major surgery. *Arch Surg* 94:102-106, 1967
3. Hamilton WK: Atelectasis, pneumothorax and aspiration as postoperative complications. *ANESTHESIOLOGY* 22:708-722, 1961
4. Goldstein A: Biostatistics—An Introductory Text. Second edition. New York, MacMillan, 1965
5. Claeys DW, Lockhart CH, Hinkle JE: The effects of translaryngeal block and Innovation on glottic competence. *ANESTHESIOLOGY* 38:485-586, 1973

## A Complication of Radial-artery Cannulation

ROBERT W. JOHNSON, M.B., B.S. (LOND.), F.F.A.R.C.S.\*

Serious complications resulting from radial artery cannulation are rare. Two cases of ischemic cutaneous damage from such cannulation are reported.

#### REPORTS OF TWO CASES

**Patient 1.** A 44-year-old man underwent aortic valve replacement with a Starr-Edwards prosthesis during cardiopulmonary bypass. A PTFE (Teflon) cannula was passed into the left radial artery, using the needle-and-wire technique described by Seldinger,<sup>1</sup> soon after induction of anesthesia. The site of puncture of the skin was approximately 1 cm proximal to the radial head, and the tip of the cannula was about 6 cm proximal to the puncture. The cannula was used for manometry and blood sampling. It was continuously

flushed by means of a continuous infusion pump at a rate of 8 ml/hr with sodium chloride, 0.9 per cent, containing heparin, 1,000 units/l. Free flow was found at all times.

Approximately nine hours after cannulation, a dusky purple area was noticed over the middle third of the anterior surface of the forearm. The cannula was withdrawn approximately 3 cm. Little change was noticed over the next six hours, and the cannula was removed. Systemic perfusion throughout this period was good. After four days the appearance of the affected skin was normal.

**Patient 2.** A 17-year-old boy involved in a traffic accident had received multiple injuries to the lower limbs, abdomen and thorax. Left-radial-artery cannulation was carried out percutaneously using a PTFE Venflon cannula of external diameter 1.4 mm prior to repair of a ruptured thoracic aorta during cardiopulmonary bypass. Flushing technique was identical to that described above. During operation the arterial supply to the cannulated limb was interrupted for a period of 10 minutes, during which time flushing of the cannula was continued.

During the first 24 hours after operation the systemic circulation was frequently poor. Cardiac arrest occurred once; the patient was resuscitated

\* Senior Registrar and Tutor in Anaesthetics United Bristol Hospitals and Frenchay Hospital, Bristol, England. Presently Visiting Assistant Professor of Anesthesiology, University of Virginia, Charlottesville, Virginia 22903.

Accepted for publication January 17, 1974.