

Pharmacologic Reversal of Horner's Syndrome Following Stellate Ganglion Block

A. P. WINNIE, M.D.,* S. RAMAMURTHY, M.D.,† Z. DURRANI, M.D.,†
R. RADONJIC, M.D.,† M. H. SHAKER, M.D.†

To anesthesiologists engaged in the diagnosis and management of pain problems, the development of Horner's syndrome following the performance of a diagnostic or therapeutic stellate ganglion block is a welcome, valuable sign, indicating that effective sympathetic blockade has been accomplished. To the patient undergoing the block, the development of Horner's syndrome, particularly the ptosis, may be irritating and alarming. The physiologic mechanisms by which stellate ganglion block produces ptosis, miosis, and enophthalmos, originally described by Horner,¹ have been clearly delineated and are well understood, as are the conjunctival and scleral injection and nasal stuffiness which also follow sympathetic blockade at this level.² Yet, astonishingly enough, the pharmacologic reversal of these unpleasant "side effects," so obviously suggested by the physiologic mechanisms producing them, have not, to our knowledge, been described in the anesthesia literature. Since it is the removal of sympathetic input which produces the characteristic ocular and nasal signs and symptoms, then topical application of sympathomimetic agents to the eye should reverse them.

METHODS AND MATERIALS

One hundred consecutive patients undergoing diagnostic or therapeutic stellate ganglion blocks at the University of Illinois Pain Clinic were selected for inclusion in this study. When the development of ptosis, miosis, and conjunctival injection became obvious after the performance of each stellate ganglion block, 1-2 drops of an ophthalmic

* Professor and Head.

† Assistant Professor.

Received from the Departments of Anesthesiology, Abraham Lincoln School of Medicine, University of Illinois at the Medical Center, University of Illinois Hospital, and West Side Veterans Administration Hospital, Chicago, Illinois 60612. Accepted for publication July 12, 1974.



FIG. 1. *Above*, fully developed Horner's syndrome following right stellate ganglion block. *Below*, Same patient shortly after the instillation of phenylephrine drops into the right eye. Note that the previously ptotic lid retracts to a position even higher than that of the normal lid, and that while the ptosis and conjunctival injection have already been reversed, the miosis still persists.

preparation of 10 per cent phenylephrine hydrochloride (Neosynepine) were instilled in the conjunctival sac of the eye, after which the eye signs were followed for the subsequent 10-15 minutes.

RESULTS

In each of the 100 cases in this study (and in all cases thereafter) instillation of phenyl-

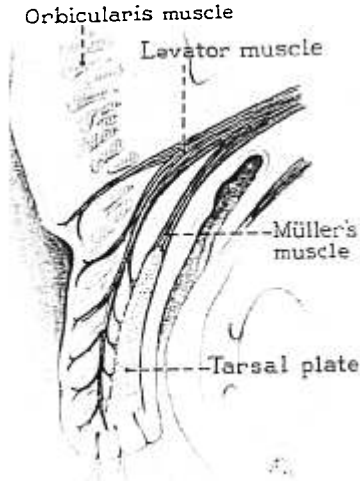


FIG. 2. Diagrammatic cross section, illustrating the muscles involved in elevation of the upper eyelid.

ephrine into the "chemically sympathectomized" eye resulted in prompt and complete reversal of the eye signs and symptoms that invariably follow effective stellate ganglion block. Not only did the conjunctival and scleral injection disappear, the ptotic upper eyelid also returned immediately to a normal or even slightly retracted position (fig. 1). Over the next 10-15 minutes, the miotic pupil returned to its normal size, and the nasal congestion produced by the block similarly decreased and then disappeared. Subjectively, the patients were extremely appreciative of this pharmacologic reversal of what most of them considered to be minor but definitely unpleasant side-effects of this treatment. The vast majority of them, when undergoing a series of stellate blocks, would say after each block had been done and their pain had disappeared. "Okay, my pain's gone; now can I have the eye drops?"

DISCUSSION

That the vascular supply to the conjunctivae and sclerae is under sympathetic control is neither surprising nor remarkable. However, anesthesiologists tend to forget that the size of the pupil (*i.e.*, the contractile state of the iris) and the level of the upper eyelid (*i.e.*, the contractile state of Müller's superior palpebral muscle) are under similar sympathetic control. These are mediated by alpha-adrenergic receptors, as indicated in the studies of Waldstein *et al.*,³ who were attempting to delineate the mechanism underlying the blepharoptosis of myxedema. They were able to demonstrate that in patients with myxedema the ptosis was primarily due to dysfunction of Müller's muscle, and that the instillation of phenylephrine but not epinephrine was effective in correcting the dysfunction of this sympathetic neuromuscular unit.

Involvement of either one of the two neuromuscular units which elevate the upper eyelid can result in ptosis, but the extent and type of ptosis resulting depends on which unit is involved. The major muscle is the levator palpebrae superioris, striated muscle innervated by the superior division of the oculomotor nerve. This muscle originates from the apex of the orbit and is inserted into the skin of the upper lid and anterior tarsal plate (fig. 2). The minor muscle is Müller's superior palpebral muscle, a small smooth muscle innervated by sympathetic nerves. It originates from the fleshy portion of the levator muscle and its insertion is on the superior border of the tarsal plate. When both the levator palpebrae superioris and Müller's muscle are intact and normally innervated, there is no ptosis, voluntary lid elevation is possible, conjugate lid elevation occurs with upward gaze, and there is a tarsal fold, *i.e.*, a fold in the skin of the upper eyelid on forward gaze. When neuromuscular dysfunction of the levator palpebrae superioris muscle occurs, marked ptosis, absence of voluntary lid elevation, failure of conjugate elevation, and loss of the tarsal fold will be present. On the other hand, when dysfunction of Müller's muscle alone

occurs, there is only slight ptosis, while voluntary and conjugate lid elevation are normal and the tarsal fold persists.

While the pharmacologic reversal of the ptosis (and the other eye signs) resulting from stellate ganglion block is carried out simply to minimize the discomfort of Horner's syndrome, it may also be useful for patients who have congenital hyperhidrosis. The only complete cure of this condition is surgical sympathectomy. Prior to surgical intervention, these patients usually have a stellate ganglion block to allow them to assess the tolerability of the sequelae of cervical sympathectomy. It has been our experience that these patients usually find the eye signs, and especially the ptosis, too distressing, and in women cos-

metically unacceptable, so they usually elect to live with their hyperhidrosis. In such cases the demonstration that the simple instillation of eye drops can pharmacologically reverse all of these sequelae may cause the patient to elect operation.

REFERENCES

1. Horner F: *Über eine Form Von Ptosis*. *Klin Monatsbl Augenheillol* 7:193-198, 1869
2. Hiccox CB, Tovell RM, Raskind R: *The stellate ganglion: Its significance in practice*. *ANESTHESIOLOGY* 4:150-159, 1943
3. Lee WY, Morimoto PK, Bronsky D: *Studies of thyroid and sympathetic nervous system interrelationships. I. The blepharoptosis of myxedema*. *J Clin Endocrinol Metab* 21: 1402-1412, 1961

The Editor-in-Chief and the Editors of ANESTHESIOLOGY wish to thank the following consultants and referees for making available their expert knowledge in reviews of manuscripts during the past six months:

MARJAM G. BEHAR, PH.D.
HENDRIK H. BENDIXEN, M.D.
RICHARD J. BING, M.D.
COLIN M. BLOOR, M.D.
RICHARD CHAPMAN, PH.D.
KAO LIANG CHOW, PH.D.
DONALD L. CLARK, M.D.
DR. W. C. CLARK
BRUCE CULLEN, M.D.
DR. WALLACE DAIRMAN
GEORGE P. FULTON, PH.D.
RONALD GABEL, M.D.
AARON GISSEN, M.D.
DR. FRANCIS J. HADDY
PETER JATLOW, M.D.
GABOR KALEY, PH.D.
JOAN KENDIG, PH.D.
LUKE M. KITAHATA, M.D., PH.D.
JAMES LANKTON, M.D.
EDWARD LOWENSTEIN, M.D.
MICHAEL MARSH, M.D.

WAYNE MARTIN, M.D.
TERENCE M. MURPHY, M.D.
JOHN L. NEIGH, M.D.
LOIS O'BRIEN, M.D.
HENRY L. PRICE, M.D.
EDWARD P. RADFORD, M.D.
KAI REHDER, M.D.
RICHARD K. RICHARDS, M.D.
JOHN SAVARESE, M.D.
HARVEY M. SHAPIRO, M.D.
DR. GENE SMITH
T. C. SMITH, M.D.
GEORGE E. STROBEL, M.D.
S. F. SULLIVAN, M.D.
JAMES TRUDELL, PH.D.
ISSAKU UEDA, M.D., PH.D.
BARBARA WAUD, M.D.
LESNICK WESTRUM, PH.D.
K. C. WONG, M.D.
DR. J. C. YANG
B. W. ZWEIFACH, PH.D.