

Hypesthesia of the Tongue

FRANCIS M. JAMES, III, M.D.*

The following case report describes an unusual injury resulting from efforts to maintain a patent airway.

REPORT OF A CASE

A very obese 36-year-old woman with menorrhagia and urinary incontinence was scheduled for transvaginal hysterectomy plus anterior and posterior repair. A small mouth, large tongue, and short fat neck made laryngeal visualization difficult. After two unsuccessful attempts, tracheal intubation was abandoned for fear of damage to the patient's teeth. Anesthesia was maintained with nitrous oxide-oxygen-halothane by mask. Despite the presence of an oropharyngeal airway, soft-tissue obstruction was a persistent problem, necessitating continuous bilateral anterior pressure at the mandibular angles to provide a patent airway. Surgery proved equally difficult, necessitating nearly three hours of anesthesia. On the first postoperative day the patient complained of numbness of the tongue and loss of taste sensation. Her complaints persisted approximately three weeks, completely resolving by 28 days.

* Associate Professor.

Received from the Department of Anesthesia of the Bowman Gray School of Medicine of Wake Forest University, Winston-Salem, North Carolina 27103. Accepted for publication September 3, 1974.

COMMENT

Although nerve injuries secondary to pressure phenomena are not uncommon, involvement of the lingual nerve is very unusual. The lingual nerve, a branch of V_3 , supplies general sensation to the sublingual region, including the floor of the mouth and the gums, as well as to the anterior two thirds of the tongue, where its fibers end mainly in fungiform and filiform papillae. The chorda tympani, a branch of the facial nerve, joins the lingual nerve from behind near the border of the lateral pterygoid muscle in the infratemporal fossa. It supplies taste to the anterior two thirds of the tongue, with its fibers ending in taste buds. The patient's complaints of loss of taste and numbness of the tongue could be explained by trauma to the lingual and accompanying chorda tympani nerves secondary to prolonged pressure on them by the lateral and medial pterygoid muscles, as the joined nerves pass between them (fig. 1). Anterior displacement of the mandible could result in this amount of pressure, especially if the pterygoid muscles became edematous during prolonged efforts at airway maintenance. It is unlikely that pressure on the dorsal aspect of the tongue by the Guedel airway caused the hypesthesia.

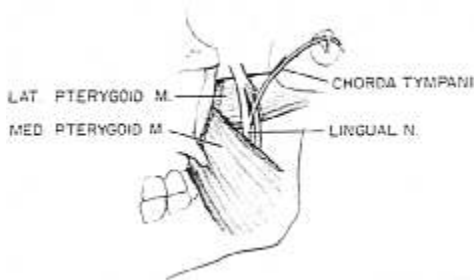


FIG. 1. Relationship of the chorda tympani and lingual nerve to the pterygoid muscles.