

Clinical Reports

BURNELL R. BROWN, JR., M.D., Ph.D., *Editor*

Air Embolism Through a Ventriculoatrial Shunt during Pneumoencephalography

JOHN A. YOUNGBERG, M.D., MAJOR, MC,* JOEL A. KAPLAN, M.D., MAJOR, MC,†
EDWARD D. MILLER, JR., M.D., MAJOR, MC‡

Pneumoencephalography is frequently used during routine evaluation of patients suspected to have intracranial lesions. In adult patients, the procedure is usually done under local anesthesia supplemented with sedation and with minimal monitoring. Many complications have been reported to occur during pneumoencephalography, including hypotension, bradycardia, arrhythmias, syncope, hypoventilation, cerebral herniation, and air embolism through dural venous channels.^{1,2} The following case demonstrates another route of air embolization during pneumoencephalography in a patient with a patent ventriculoatrial shunt. This case points out that, for selected patients who pose special problems, an anesthesiologist should be in attendance, and the patient should be monitored extensively.

REPORT OF A CASE

A 17-year-old Caucasian boy was admitted for evaluation of a suspected recurrence of a previ-

ously diagnosed and treated pinealoma. Four years prior to this admission, he had been found to have a mass lesion in the supracellar region and the third ventricle with extension to the left lateral ventricle. He had been treated with radiation to the brain and spinal cord and placement of ventriculoatrial shunt.

The patient's present admission was the result of frontal headaches, increased somnolence, and weakness on the right side. Physical examination disclosed optic disc pallor bilaterally, severely impaired visual fields inferiorly, and marked lethargy. A brain scan was unchanged from one done two years previously. An EEG was abnormal, with slow background activity and predominant delta activity bifrontally. A cerebral arteriogram showed a questionable mass in the area of the third ventricle. On the basis of these findings, it was decided to obtain a pneumoencephalogram to make a definitive diagnosis, even though the patient had a patent ventriculoatrial shunt. Preoperatively, the patient was taking Deletestyl, 200 mg, every four weeks, vasopressin, 5 mg every other day, hydrocortisone, 10 mg twice daily, and sodium levothyroxine, 0.2 mg daily. Hematocrit was 41 per cent, electrolyte values were normal, and the chest roentgenogram and EKG were normal. Premedication consisted of Innovar, 1 ml, hydrocortisone, 100 mg, and atropine, 0.6 mg, intramuscularly one hour before the procedure.

In the diagnostic room, a 16-gauge central venous pressure catheter was placed through the right antecubital vein. The position of the CVP line was checked by fluoroscopy and the tip was found to lie within the right atrium; blood could be easily aspirated. Other monitors included a precordial stethoscope positioned over the tricuspid valve, blood pressure cuff, and EKG lead II. The patient was placed in the left lateral decubitus position for insertion of a spinal needle. The opening pressure was 110 mm H₂O. The patient was then placed in the sitting position in a pneumoencephalography chair. Eighty milliliters of air were injected through the spinal needle.

* Resident, Anesthesia and Operative Service, Brooke Army Medical Center, Fort Sam Houston, Texas 78234.

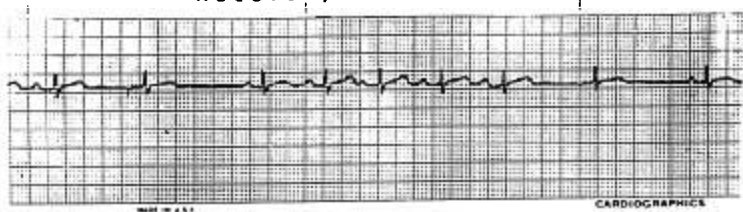
† Assistant Professor, Department of Anesthesia, Emory University, Atlanta, Georgia 30322.

‡ Staff, Anesthesia and Operative Service, Brooke Army Medical Center, Fort Sam Houston, Texas 78234.

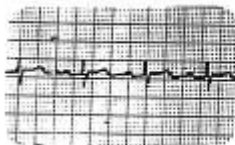Accepted for publication September 11, 1974.

The opinions or assertion contained herein are the private views of the authors and are not to be construed as official or as reflecting the views of the Department of Army or the Department of Defense.

Recovery Room Lead II



Pre-op Lead II



Post-op Lead II

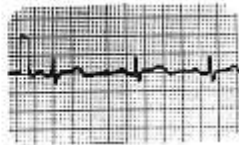

FIG. 1. A, EKG recording obtained in recovery room, demonstrating a severe sinus arrhythmia with atrial escape beats. B, preoperative EKG, demonstrating normal sinus rhythm. C, postoperative EKG, demonstrating normal sinus rhythm 24 hours after acute arrhythmia.

scout films were taken, and after approximately 5 minutes four exchanges of 20 ml of air for 20 ml of spinal fluid were performed. Following this, an additional 40 ml of spinal fluid was removed without an exchange of air. During the period in which the exchange was being performed, the patient complained of headache, the blood pressure increased from 110/70 to 120/74 torr, and heart rate increased from 110 to 140 beats/min. Approximately one minute after completion of the air-spinal fluid exchange, a "metallic" murmur could be heard over the tricuspid valve, and a supraventricular tachyarrhythmia was seen on the EKG monitor associated with ST-segment depression in lead II. Immediate aspiration through the CVP catheter yielded 8 ml of air. Over the next 3 minutes, the murmur changed in intensity and quality, ranging from "metallic" to "bubbling" and "whirring" in nature, then finally disappearing. Following return to the supine position, the patient suddenly became hypotensive, with a bradycardia that rapidly cleared. He was taken to the recovery room with a blood pressure of 134/80 torr, heart rate 92 beats/min, respiratory rate 18/min, and CVP 8 cm H₂O. The patient was alert but still complained of a headache; he had been awake throughout the procedure. The EKG remained abnormal, with a marked sinus arrhythmia and atrial escape beats (fig. 1) until the next morning, at which time it reverted to the preoperative EKG.

DISCUSSION

Many reports concerning air embolism during pneumoencephalography and other procedures have appeared, but to our knowledge this is the first report of an air embolus occurring through a patent ventriculoatrial shunt during pneumoencephalography. Fortunately, few patients undergoing pneumoencephalography have ventriculoatrial shunts. Patients with this complicating factor may be managed in the following ways: 1) use of another contrast medium instead of air; 2) extreme care in positioning the patient and removing cerebrospinal fluid; 3) placement of a CVP catheter in the right side of the heart to aspirate any air that might embolize there from the cerebral ventricles; 4) an anesthesiologist in attendance; 5) continuous EKG monitoring; 6) resuscitation equipment and drugs readily available; 7) placement of a chest piece or Doppler flow probe over the tricuspid valve; 8) consideration to ligating or clamping the shunt prior to performing pneumoencephalography.

and then re-establishing the shunt after the procedure has been performed.

Many other contrast media have been used for study of the cerebral ventricles. Lipiodal and Pantopaque have been used for ventriculography, but they have been reported to block ventriculoatrial shunts,² and Lipiodal has produced pulmonary oil emboli.⁴ Conray is a water-soluble contrast medium that will cause fewer mechanical problems with shunts, but it may produce convulsions if inadvertently placed in the subarachnoid space.^{5,6} Nitrous oxide or carbon dioxide can be used for gas ventriculography and would be safer than air if they embolized to the heart because of their rapid absorption in the blood.^{7,8} The rapid absorption of these gases from the ventricles may render the diagnostic studies inadequate; however, it has been demonstrated that satisfactory studies can be achieved when nitrous oxide is employed as the contrast medium in patients being anesthetized with nitrous oxide-oxygen, since the absorption time of nitrous oxide is prolonged sufficiently to yield a satisfactory study.⁹

If air is used as the contrast medium, it would be desirable to keep the air-fluid level above the proximal end of the ventriculoatrial shunt. It is recognized that leaving some cerebrospinal fluid within the ventricular system will yield a less than optimal study, but this may be preferable to the risk of air embolism through the ventriculoatrial shunt. In our patient, the injection of 160 ml of air caused no problem since the ventricular end of the shunt was still under the cerebrospinal fluid. Although 120 ml of cerebrospinal fluid were withdrawn, it was only after the final 40 ml was removed that the air reached the shunt and embolized to the heart. Possibly, air embolism might not have occurred in this patient if a smaller volume of air had been injected or a smaller amount of cerebrospinal fluid had been withdrawn. Careful positioning of the patient and continuous observation of the air-fluid level with respect to the shunt should help avoid air embolization.

We believe a CVP catheter should be placed in patients undergoing pneumoencephalography who have patent ventriculoatrial shunts in place.¹⁰ The position of the

catheter should be checked by fluoroscopy or by other means such as EKG localization or pressure recording through the catheter, and blood should be easily aspirated from the right side of the heart. With this catheter in place, the initial step in treating an air embolus is to aspirate the air out of the heart. Other measures include oxygenation, treatment of arrhythmias and hypotension, and positioning of the patient so that the cerebrospinal fluid covers the proximal end of the shunt.

There are many methods of diagnosing air embolism. Probably the most sensitive is the Doppler flow probe placed over the tricuspid valve.¹¹ We elected not to use this because of the numerous position changes necessary during pneumoencephalography. Our patient showed the following signs: an arrhythmia consisting of tachycardia, then bradycardia with premature atrial contractions, ST-segment depression on the EKG in lead II, hypotension, irregular respirations, and a change in heart tones detected by chest stethoscope. The patient first developed the "drum" sign as described by Hoffman,¹² consisting of metallic sounding heart sounds, then a "bubbling" noise, and, finally, the classic "mill wheel" murmur.

In summary, this case demonstrates another potential complication during pneumoencephalography. Recommended methods of management include the use of a contrast medium other than air and appropriate monitoring of the patient by an anesthesiologist during the procedure.

REFERENCES

1. Smith RM: Anesthesia for Infants. St. Louis, C.V. Mosby, 1968, p 346
2. Jacoby J, James JR, Zeigler J, et al: Pneumoencephalograph and air embolism: Simulated anesthetic death. *ANESTHESIOLOGY* 20:336, 1959
3. Mendez JS: Ventriculoatrial shunt blockage by previous positive contrast ventriculography. *J Neurosurg* 39:356-358, 1973
4. Allen WE, D Angelo CM: Pulmonary oil embolization following Pantopaque ventriculography in a patient with a ventriculovenous shunt. *J Neurosurg* 35:603-627, 1971
5. Cornejo SG: Conray ventriculography in the diagnosis of intraventricular and posterior fossa lesions. *J Neurosurg* 34:405-407, 1971

6. Weiss SR, Raskin R: Conray ventriculography in the diagnosis of brain tumors and congenital malformations in children. *J Neurosurg* 34:408-411, 1971
7. Gardner LG: Air embolism during cisternal air myelography. *Br J Anaesth* 43:807-810, 1971
8. Graff TD, Arbegast NR, Phillips DC, et al: Gas embolism: A comparative study of air and carbon dioxide as embolic agents in the venous system. *Am J Obstet Gynecol* 78: 259, 1959
9. Bergstrom K, Hogstrom S, Lodin H: Nitrous oxide and oxygen as contrast medium in pneumography under general anesthesia. *Acta Radiol [Diagn] (Stockh)* 9:140-145, 1969
10. Michenfelder JD, Martin JT, Alfenberg BM, et al: Air embolism during neurosurgery. *JAMA* 208:1353-1358, 1969
11. Michenfelder JD, Miller RH, Gronert GA: Evaluation of an ultrasonic device for the diagnosis of venous air embolism. *ANESTHESIOLOGY* 36:164-167, 1972
12. Hoffman EP, Fiskin RD, Sheldon CH: Unusual heart sounds associated with venous air embolism. *J Neurosurg* 33:460-462, 1970

Anesthetic Management of Emergency Tonsillectomy and Adenoidectomy in Infectious Mononucleosis

ELSIE F. MEYERS, M.D.,* AND BARBARA KRUPIN, M.D.†

Although infectious mononucleosis is usually benign, the disease may be fatal if severe airway obstruction develops.^{1,2} The possible causes of airway obstruction include hyperplasia of tonsils and adenoids, edema of the uvula, epiglottis, or arytenoids, formation of a pseudomembrane, or combinations of these. In past reports, tracheostomy has been performed as a life-saving measure prior to tonsillectomy.^{3,4} Anesthetic technique was not discussed. This report describes our anesthetic management of a case in which tracheostomy was avoided in the presence of airway obstruction due to enormous necrotic tonsils.

REPORT OF A CASE

A 16-year-old Caucasian girl had been healthy until a week prior to admission, when she developed fever, tonsillitis, and swelling of cervical lymph nodes. During the four days prior to admission she had been able to swallow only liquids; she was given a course of penicillin, but her temperature remained elevated (38.3 to 39.4 C. orally). Her tonsils on admission were described as

being "markedly inflamed with a whitish exudate," and so enlarged that they met in the midline. Marked cervical lymphadenopathy was present. Oral temperature was 38.8 C.

Pertinent abnormal laboratory findings included: heterophil agglutination 1:640; leukocyte count 5,300/cu mm with 44 segmented neutrophils, 53 lymphocytes (42 of which appeared young with nucleoli and scanty basophilic cytoplasm), and 3 monocytes. Culture of a specimen from the throat produced a few alpha streptococci, a heavy growth of *Hemophilus influenzae*, and moderate growth of *Neisseria*.

The night after admission the patient's sputum was bloody and she could speak only in a high-pitched whisper. Increasing airway obstruction developed despite administration of steroids and placement in a tent containing high humidity and supplemental oxygen. Insertion of a soft rubber nasal airway resulted in marked improvement of ventilation. Early the next morning the tonsils appeared necrotic, friable, more swollen, and firmly opposed in the midline. A nasal airway was still necessary for airway maintenance. The patient appeared ill and lethargic; cervical adenopathy was further increased. The decision to perform an emergency tonsillectomy and adenoidectomy was made.

Report was established and awake intubation of the trachea discussed with the patient. She was premedicated with droperidol, 2.5 mg, and atropine, 0.5 mg, intramuscularly one hour preoperatively. In the operating room she was given hydrocortisone sodium succinate, 100 mg, intravenously. The pharynx was sprayed with 2 ml lidocaine 4 per cent. The larynx was carefully exposed with a #3 MacIntosh blade. A 6-mm I.D.

* Assistant Professor.

† Resident.

Received from the Department of Anesthesiology, Washington University School of Medicine, St. Louis, Missouri. Accepted for publication September 16, 1974.