

## Medical Intelligence

### *Anesthesia for Brain Computer Tomography*

Sydney J. Aidinis, M.B., B.S., F.F.A.R.C.S.,\* Robert A. Zimmerman, M.D.,†  
Harvey M. Shapiro, M.D.,‡ Larrisa T. Bilanuick, M.D.,§  
A. Michael Broennle, M.D.¶

COMPUTER TOMOGRAPHY (CT) is a fundamentally new, noninvasive, highly accurate neuroradiologic diagnostic technique.<sup>1-4</sup> Anesthesiologists' services for CT scanning are required whenever patient movement within the scanning apparatus threatens to invalidate the procedure. At the University of Pennsylvania Hospital, approximately 7 per cent of patients need general anesthesia during CT examination. This percentage is relatively high because our patient load includes pediatric cases from a large children's hospital. Only about .5 per cent of our adult patients need general anesthesia for this examination. Approximately 17 per cent of pediatric and adult patients receiving general anesthesia are acute head-trauma cases. Because of the noninvasive nature of the CT scan, outpatients as well as very ill patients are being studied by CT with increasing frequency.

This paper briefly reviews the principles of CT and the major indications for such studies. It then discusses the special problems associated with organizing anesthetic and sup-

portive care for patients undergoing this innovative neuroradiologic procedure.

#### Principles of CT

Computer tomography relies upon the use of a small computer to process x-ray photon attenuation data as measured by sodium iodide crystals rotating about the patient's head.<sup>5</sup> The detection system (two sodium iodide crystals) is located on a scanning gantry in exact opposition to an x-ray tube. During the examination, the gantry rotates around the patient's head while a narrow collimated x-ray beam is transmitted through a thin section of the head. The gantry moves by 1 degree at a time, until it completes an arc of 180 degrees. After each rotation of the gantry, the continuously operating x-ray tube performs a linear scan, which results in 160 readings. Completion of a scan requires about 4½ minutes and results in 28,800 measurements (160 × 180). Usually, eight 13-mm thick contiguous slices are necessary to examine the entire intracranial contents. Because two slices are obtained simultaneously with each rotation around the head, the complete examination usually involves four revolutions and takes about 25 minutes. The first commercial computer tomographic apparatus, the EMI scanner, required that the patient's head be placed in a rubber bag surrounded by water. The purpose of the water was to act as a zero reference point for an arbitrary scale whose units represent relative densities proportional to absorption coefficients of various tissues. Thus, a zero base, the coefficient of the absorption to water, was established with each passage of the x-ray beam. The scale had a range of 1,000 EMI units, air (-500) and bone (+500) being at opposite ends and water in

\* Instructor in Anesthesia.

† Assistant Professor of Radiology.

‡ Associate Professor of Anesthesia and Neurosurgery. Present address: Department of Anesthesia, University of California, San Diego, University Hospital, 225 West Dickinson Street, San Diego, California, 92103.

§ Assistant Professor of Radiology.

¶ Assistant Professor of Anesthesia.

Received from the Neuroanesthesia Group, Departments of Anesthesia and Surgery, Division of Neurosurgery and Department of Radiology, University of Pennsylvania, and The Department of Anesthesiology, Children's Hospital of Philadelphia, Philadelphia, Pennsylvania 19104. Accepted for publication February 11, 1976. Supported in part by USPHS Grants #GM-15430-07, 215-16 and NINDS NS 08803-05, 0552.

Address reprint requests to Dr. Shapiro.

the middle. The water also modified large differences in density between bone and air and thus eliminated some of the "overshoot" problems. Newer CT scanners have eliminated the requirement for a water interface surrounding the skull, and scan at much faster rates.

Accuracy of reproduction of a density in EMI units is 0.5 per cent.<sup>6</sup> The computer data are then displayed on either a cathode ray tube or a digital printout sheet. Electronic enhancement of density differences can be accomplished, and Polaroid photographs of the cathode screen provide hard copies of the scan. The Polaroid picture of the cathode ray image is an anatomic depiction of a transverse section of the head. Figure 1 is an example of a CT scan, performed in the case

of a patient who had an intracranial hematoma. In the computer-processed picture, darker shades correspond to biologic media of low density (air, cerebrospinal fluid), while lighter shades relate to denser tissues such as blood, bone, and intracranial calcifications. Brain parenchyma takes on an intermediate shading, while extravasated blood is more opaque, and cerebral edema less dense than normal brain tissue. Abnormalities are recognized as either differences in density from adjacent structures or, when density differences are not present, by displacement of structures such as the ventricles.<sup>6</sup>

#### Indications for CT

CT scanning is usually indicated in the presence of suspected intracranial masses,

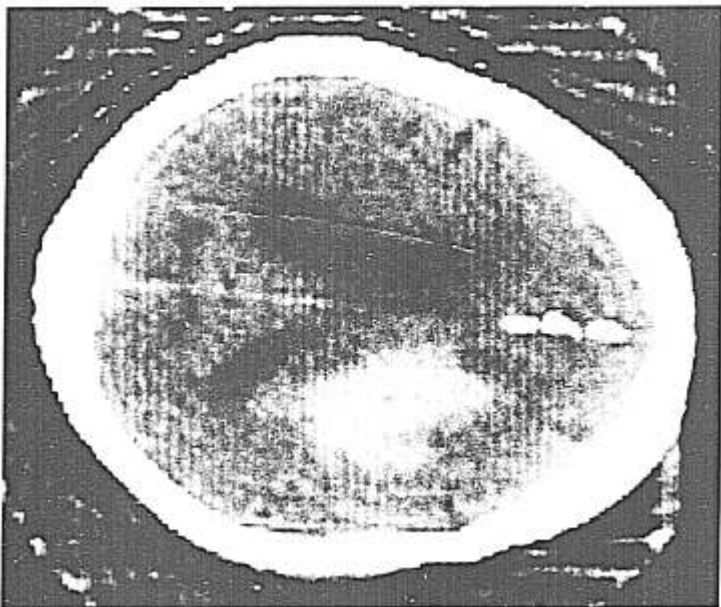


FIG. 1. CT shows elongated, irregular white density in the right hemisphere consistent with an intracerebral hematoma. It compresses the body of the right lateral ventricle. Decreased density in its periphery represents edema. Hydrocephalus is present, as evidenced by enlarged left lateral ventricle.




FIG. 2. Intubated, anesthetized patient undergoing computerized tomography in an EMI Scanner and in a room designed to accommodate the anesthesiologic requirements. Anesthetic gases and vacuum are piped into the suite through ceiling outlets located above and just behind the scanner. A small portable anesthesia machine equipped with a battery-powered ECG and pressure monitor is used. Often an anesthesia ventilator will be employed, as will ventilators appropriate to the continuing support of intensive-care patients. It is important that the shielded observation window (upper left corner) have a view of the patient's head and remain unobstructed.

degenerative processes, congenital anomalies, and infectious or vascular disease.<sup>6</sup> CT has proved particularly valuable in the detection of low-grade gliomas, intracerebral hematomas,<sup>7</sup> and cerebral edema,<sup>1</sup> and in the delineation of the ventricular system and subarachnoid spaces.<sup>4,6,8</sup> The CT scan plays a major role in the evaluation of the patient with an acute head injury. It not only offers a quick, noninvasive method of diagnosing and assessing the extent of acute brain swelling, but also is able to differentiate between hematoma and edema.<sup>4</sup> This was not possible with previously available techniques. Thus, emergency cerebral arteriography can frequently be avoided. However, angiography remains the best technique currently available for displaying cerebral blood vessels and their abnormalities.

Serial CT scanning is assuming an increasingly important role in the preoperative and postoperative management of neurologic patients. Because it is free from the hazards of the invasive techniques of arteriography

and air or contrast studies, there is less reluctance to repeat studies. Repeat CT scanning complements the clinical examination, especially in the appraisal of a patient's deteriorating condition. This is particularly helpful in evaluating the state of cerebral edema, change in size of intracranial hematomas, or alteration in size of the ventricular system.

Diagnostic errors with CT scanning, approximately 3–4 per cent, occur when the density of lesions differs little from that of normal tissue.<sup>9</sup> Similar errors may be expected when the pathologic anatomy is small or complicated by virtue of its location, e.g., posterior fossa lesions. Tissue-density differences may be enhanced by using intravenous contrast media, for example, iodine in sodium iohalamate.<sup>10</sup> Contrast agents often permit differentiation between tumors and infarcts, because tissue density enhancement usually occurs in neoplastic pathology. Lesions such as meningiomas, neurinomas, and arteriovenous malformations may show contrast

enhancement due to either increased vascularity or an abnormal blood-brain barrier. The use of intravenous contrast medium adds a risk of an allergic reaction and requires additional time (another 25 minutes).

### Radiation Exposure

During a 30-minute scan the patient is exposed to 1.0–2.5 rads, or approximately the amount of radiation associated with a conventional x-ray examination of the skull. Patient gonadal dose is less than 0.1 mrad.<sup>11</sup> The highest radiation field in the room is a result of the x-ray emitter tube leakage. Thus, as this tube rotates around the right side of the patient, the exposure is greatest on the right. An anesthesiologist positioned on the left between the patient and the anesthesia machine shown in figure 2 could expect to receive a skin dose of 1–2 mrad/hour.<sup>11</sup> An anesthesiologist wearing a lead apron 5-mm thick and avoiding close exposure to the emitter tube could safely participate in an unlimited daily schedule. Radiation monitoring badges should be worn by anesthesiologists who participate in CT scanning on a regular basis.

### Problems in CT Scanning

Movement of the patient's head during a CT scan scrambles the geometrical coordinates fed into the computer. To prevent movement during the scanning process, the patient's head is positioned in a tightly fitting water-filled rubber head bag (fig. 2). A head holder may also be employed to restrict movement. Patient cooperation is vital to achieve high-quality scans. In one series about 4 per cent of CT scans were ruined by movement.<sup>3</sup> When the head holder and head bag are insufficient for preventing head motion, sedation or general anesthesia is necessary. This is frequently the case when the patients are young children or agitated adults. Scanning the posterior fossa requires greater forward flexion of the head.<sup>4</sup> However, the presence of pain and stiffness of the neck make it difficult for the patient to maintain this posture, and analgesia-sedation, or even general anesthesia, may be necessary.

### Organization of CT-Anesthesia Facilities

CT scanning necessitates close cooperation between the neuroradiologist and anesthesiologist and a mutual appreciation and understanding of each other's problems. Installation of the CT scanner requires major structural alterations in the radiologic suite. The anesthesiologist's participation in the design of this facility should occur early, as radiologists may not recognize or consider the anesthetic and supportive care in constructing their facilities. The difficulty of working in a limited space in an environment not conducive to intensive-care support of potentially high-risk patients (head injuries, etc.) is often not appreciated.

Radiologists fail to consider the time needed to prepare for and induce anesthesia in patients undergoing neurodiagnostic studies. If adequate nearby induction areas are not available, the CT room itself must be used for this purpose. This represents a scheduling and economic burden to the radiology department, because in most instances CT schedules are fully booked. At approximately \$200–\$335 patient charge per study, delays such as those associated with the induction of anesthesia can create economic stresses.

A measure of the magnitude of this problem in our experience is provided by the following data. Delays due to a combination of anesthetic problems, poor scheduling of patients, and problems with the scanning apparatus resulted in an average time between induction of anesthesia and beginning of scanning of  $33.0 \pm 21.6$  (SD) minutes, with a range of 5–190 minutes. The mean time required for the scans was  $52.6 \pm 21.5$  minutes, with a range of 15–125 minutes. These times include the additional times required for administration of intravenous contrast agents and re-scanning.

The induction area, as well as the CT room, ought to be large enough to accommodate the CT scanner, the anesthetist, an anesthesia machine, ventilator, routine monitoring equipment, and a hospital bed. The induction facilities should be in an adjoining room with storage space for anesthetic equipment and defibrillator. When not employed for anesthetic purposes, this room is available for patient preparation and as a holding area.

TABLE 1. Anesthesia Services Needed for CT Scanning in Adult and Pediatric Patients in a 23-month Period

	Total Number of CT Scans	General Anesthetics	Anesthesia Standby Life Support-Transport
Adult	1,972	8	8
Pediatric	530	160	7

TABLE 2. Indications for Brain CT Scanning Based on Presumed or Established Etiology in Adult Patients

Cerebral vascular disease		7
Hemorrhagic	4	
Occlusive	3	
Trauma		4
Hydrocephalus		2
Encephalitis		1
Coma		1
Tumor		1
TOTAL		16

TABLE 3. Indications for Brain CT Scanning Based on Presumed or Established Etiology in Pediatric Patients

Congenital abnormalities		43
Hydrocephalus	38	
Others	5	
Seizures		39
Trauma		25
Cerebral vascular disease		12
Occlusive	6	
Hemorrhagic	6	
Developmental abnormalities		10
Tumor		8
CNS infection		6
Cerebral palsy syndrome		5
Mental retardation		4
Encephalopathy		3
Miscellaneous		12
TOTAL		167

Piped anesthetic gases and vacuum with connectors for anesthesia machines should be provided in both CT and induction rooms. A small lightweight mobile anesthesia machine that requires little effort in movement is best. We have employed a mini-Boyle machine and find it completely satisfactory. Besides mobility, it offers a working and storage space (one drawer) and an overhanging shelf for placement of a portable,

battery-operated monitoring unit. An appropriate electrical power source and oxygen connection are required to accommodate ventilators, which may be needed for very sick patients.

If a recovery room is not immediately available, the induction area can serve this function, provided a trained nurse is available for postanesthetic observation. It is tempting to use the induction area as the recovery room. However, this causes delays in scheduling, especially when successive scans require anesthesia or postanesthetic complications such as vomiting occur.

Neurologic status, blood pressure, temperature, and electrocardiogram need to be monitored during the procedure. We have found a portable battery-operated unit with audio-alarms, temperature probe, pulse monitor, ECG monitor and attachments for directly connecting blood pressure and intracranial pressure transducers to be quite suitable. In the future planning of CT facilities, the incorporation of remote monitoring devices, with the display of the above-mentioned modalities in the CT control room, should be seriously considered.

### Indications for Anesthesia

The major radiologic requirement for a successful scan study is that the patient remain still during the examination. Anesthesia may be needed for cooperative patients who have movement disorders. It will frequently be necessary for confused, demented, or uncooperative patients, for restless head-injured patients, for the very young. Provision of anesthesia for CT scanning on an outpatient basis may also be necessary, as the non-invasive nature of the study had led to its early application in essentially well patients suspected to have intracranial abnormalities.

Anesthesiologists may also be asked to assist in the maintenance and transport of critically ill patients requiring various life-support devices to and from the CT suite. Transport of such patients is not without risk,<sup>14</sup> and its smooth performance necessitates a recognition of hazards existing within one's own hospital, logistic support, and continued vigilance.

Table 1 shows the distribution of anesthesia services needed for CT scanning in a single

scan facility serving a university medical center with 650 adult beds and a 200-bed children's hospital. Tables 2 and 3 summarize the types of brain lesions examined by CT scan.

### Anesthetic Management

Attempts at sedation may fail and be especially dangerous when CO<sub>2</sub> retention occurs or the airway becomes impaired. The semi-comatose, restless, head-injured patient who has borderline or established intracranial hypertension generally cannot be given sedatives; if anesthesia is needed, detailed attention to technique and an understanding of the disease process and cerebrovascular physiology are necessary.<sup>12</sup> Patients with parkinsonism who are being treated with levodopa may experience a high incidence of cardiovascular lability during anesthesia.<sup>13</sup> Scanning of posterior-fossa lesions requires forward flexion of the head, and with a large mass situated in a tense infratentorial compartment, compression of the brain stem can occur with such movement. The use of anesthesia and muscle relaxants may permit excessive head and neck movements and increase the propensity for this complication.<sup>12</sup>

When anesthesia is indicated, we generally employ a thiopental-N<sub>2</sub>O-O<sub>2</sub>-relaxant technique with oral intubation. With this technique, rapid postanesthetic recovery occurs and permits early assessment of neurologic status. Care is taken to avoid kinking the endotracheal tube during positioning in the CT apparatus. The CT scan room tends to be cold and well ventilated, and control of patient temperature may become difficult. The neonate or infant is especially prone to develop hypothermia, and facilities to add or conserve heat, especially during anesthesia, should be established. In children less than 12 months of age the incidence of hypothermia (rectal temperature <35 C) was 43 per cent. We do not have documentation of the problem in older patients. The cold water in the head bag can be heated to prevent cephalic heat loss, which can be of considerable importance in infants.

In summary, CT has introduced a new

dimension in neurologic investigative techniques. It is devoid of the risk of previous neurologic diagnostic methods. It is quick, noninvasive, and highly accurate. However, anesthesia for the CT patient represents his greatest risk. When the anesthesiologist understands the principles of CT scanning and the pathophysiology of the intracranial condition leading to the scan, this risk can be greatly minimized.

### References

1. Ambrose J: Computerized transverse axial scanning (tomography): Part II. Clinical application. *Br J Radiol* 46:1023-1047, 1973
2. Baker HL, Campbell JK, Houser OW, et al: Early experience with the EMI scanner for study of the brain. *Radiology* 116:327-333, 1975
3. New PF, Scott WR, Schuur JA, et al: Computerized axial tomography with the EMI scanner. *Neuroradiology* 110:109-123, 1974
4. Paxton R, Ambrose J: The EMI scanner. A brief review of the first 650 patients. *Br J Radiol* 47:530-565, 1974
5. Hounsfield GN: Computerized transverse axial scanning (tomography): Part I. Description of system. *Br J Radiol* 46:1016-1022, 1973
6. Ambrose J: Computerized x-ray scanning of the brain. *J Neurosurg* 40:679-695, 1974
7. Scott WR, New PF, Davis KR, et al: Computerized axial tomography of intracerebral and intraventricular hemorrhage. *Neuroradiology* 112:73-80, 1974
8. Huckman MS, Fox J, Topel J: The validity of criteria for the evaluation of cerebral atrophy by computed tomography. *Radiology* 116: 85-92, 1975
9. Baker HL, Campbell JK, Houser OW, et al: Computer assisted tomography of the head. *Mayo Clin Proc* 49:17-27, 1974
10. Kramer RA, Janetos GP, Peristen G: An approach to contrast enhancement in computed tomography of the brain. *Radiology* 116: 641-647, 1975
11. Perry BJ, Bridges C: Computerized transverse axial scanning (tomography): Part III. Radiation dose considerations. *Br J Radiol* 46: 1048-1051, 1973
12. Shapiro HM, Aidinis SJ: Neurosurgical anesthesia. *Surg Clin North Am* 55:913-928, 1975
13. Bevan DR, Monks PS, Calne DB: Cardiovascular reactions to anaesthesia during treatment with levodopa. *Anaesthesia* 28:29-31, 1973
14. Waddell G: Movement of critically ill patients within the hospital. *Br Med J* 2:417-419, 1975