

In summary, even classic thyrotoxic manifestations can be misdiagnosed in unexpected hypertthyroidism associated with hydatidiform mole. The alert and informed anesthesiologist, confronted with such an emergency situation, will make the appropriate anesthetic preparation to forestall the appearance of the life-threatening manifestations of uncontrolled thyrotoxicosis.

## REFERENCES

- Hershman JM: Hyperthyroidism induced by trophoblastic thyrotropin. *Mayo Clin Proc* 47: 913-918, 1972
- Kenimer JG, Hershman JM, Higgins HP: The thyrotropin in hydatidiform moles is human chorionic gonadotropin. *J Clin Endocrinol Metab* 40:482-491, 1975
- Hershman JM, Higgins HP: Hydatidiform mole—A cause of clinical hyperthyroidism. *N Engl J Med* 284:573-577, 1971
- Stehling LC: Anesthetic management of the patient with hyperthyroidism. *ANESTHESIOLOGY* 41:585-595, 1974
- Boutros AR: Anaesthesia and the thyroid gland: A review. *Can Anaesth Soc J* 8:586-615, 1961
- Astwood EB: Thyroid and antithyroid drugs. *The Pharmacological Basis of Therapeutics*. Fifth edition. Edited by Goodman LS, Gilman A. New York, Macmillan, 1975, p 1403

## Tension Pneumocephalus after Posterior-fossa Craniotomy, a Complication of the Sitting Position

LUKE M. KITAHATA, M.D., PH.D.,\* AND JONATHAN D. KATZ, M.D.†

The sitting position provides optimal operating conditions for surgical procedures on the cervical spinal column, posterior fossa, and gas-tric ganglion, but is associated with some potential complications. The risks of air embolism and postural hypotension have been well recognized.<sup>1</sup> More recently, several instances of position-related venous obstruction and consequent edema of the tongue or head and neck have been reported.<sup>2,3</sup> To our knowledge, tension pneumocephalus resulting from the sitting position during posterior-fossa craniotomy has not been previously described.

## REPORT OF A CASE

A 66-year-old man was admitted for evaluation of ataxia and dementia. The patient had been well until 5 months prior to admission, when he had suffered what was thought to be a seizure. There had been no residual neurologic deficit following this episode, and treatment with diphenylhydantoin, 100 mg, three times daily, had been instituted. During the ensuing four-month period, the patient had noticed increasingly severe ataxia and difficulty with memory, and the onset of a chronic left frontal headache. A neurologic examination one month prior to the present admission had

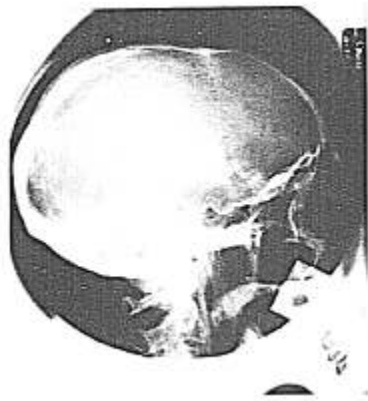

FIG. 1. Lateral skull x-ray taken one day after pneumocephalogram. There is no residual intracranial gas.

disclosed no abnormality except that an electroencephalogram showed excessive diffuse slowing and paroxysmal activity during hyperventilation.

On physical examination, the patient was disoriented as to time and place. There were grossly discernible deficits of gait and station and fine motor coordination, worse on the left side than on the right. There was no sensory or cranial nerve deficit. Pneumocephalogram (performed six days prior to operation with 45 ml oxygen) and vertebral arteriogram demonstrated a mass in the

\* Professor and Chairman.

† Assistant Professor.

Received from the Department of Anesthesiology, Yale University School of Medicine, 333 Cedar Street, New Haven, Connecticut 06510. Accepted for publication February 3, 1976.

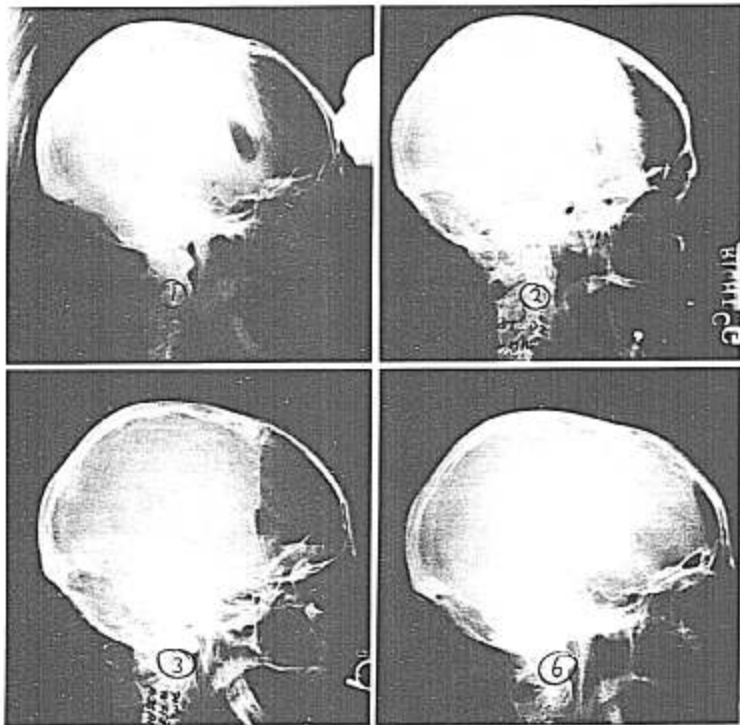


FIG. 2(*above, left*). Brow-up, lateral skull x-ray taken in recovery room. Note subdural air pocket and compression of the frontal lobes. One hemisphere can be seen to be more compressed than the other.

FIG. 3(*above, right*). Lateral skull x-ray taken after 100 per cent  $F_{iO_2}$  administered via face mask. Note some decrease in the size of the subdural gas pockets.

FIG. 4(*below, left*). Skull x-ray taken 12 hours postoperatively. The pneumocephalus has reaccumulated.

FIG. 5(*below, right*). Skull x-ray taken 30 hours postoperatively. Approximately 24 hours postoperatively a right frontal burr hole was made and an 18-gauge catheter was passed into the subdural space, evacuating air under pressure. There is a decrease in the size of the air pockets with re-expansion of the frontal lobes.

posterior fossa, located on the left superior cerebellar hemisphere. The remainder of the preoperative evaluation was essentially normal. A preoperative skull x-ray was free of intracranial air (fig. 1).

The patient was premedicated with secobarbital (100 mg), atropine (0.5 mg), and dexamethasone (4 mg), im. Anesthesia was induced with sodium

thiopental (200 mg, iv) and maintained with halothane (1 per cent) and  $N_2O$  (50 per cent) in oxygen via endotracheal tube and controlled ventilation. The patient was placed in the sitting position and a posterior-fossa craniotomy was performed. A right frontal craniotomy, which had been placed previously, was vented to facilitate surgical exposure. A subtotal resection of the left cerebellar

tumor was accomplished. Subsequent histologic examination revealed an undifferentiated small-cell carcinoma, metastatic to the cerebellum.

Total anesthesia time was 6 hours, 45 minutes. The patient received a total of 1,000 ml crystalloid, 12.5 g mannitol (to enhance diuresis) and 4 mg dexamethasone. Upon completion of the surgical procedure, the trachea was extubated and the patient returned to the recovery room breathing spontaneously.

Upon the patient's arrival in the recovery room, a neurologic examination revealed left hemiparesis, with the arm more affected than the leg, and left homonymous hemianopsia, with positive left Babinski sign and left-ankle clonus. Anteroposterior and lateral skull x-rays demonstrated diffuse haziness over the frontal hemispheres. Because of this finding, a lateral skull x-ray in the brow-up position was obtained. It clearly demonstrated a collection of subdural air with collapse of the cerebral hemispheres (fig. 2). The patient was given 100 per cent oxygen via face mask for one hour, with some decrease in size in the intracranial air pocket (fig. 3) but no improvement in physical findings.

During the ensuing 12 hours postoperatively there was gradual improvement in mental status but persistence of left hemiparesis. Repeat skull x-ray demonstrated persistence of the subdural air pocket (fig. 4). Approximately 24 hours postoperatively a right frontal burr hole was made and an 18-gauge catheter was passed into the subdural space. Approximately 20 ml of air under pressure was released upon puncture of the dura. In the following eight-hour period there was a dramatic improvement in motor strength in the left arm and leg and disappearance of the left visual field cut. There was also gradual disappearance of the pneumocephalus (fig. 5). By the following morning, 36 hours postoperatively, there was only a small amount of residual subdural air, with slight weakness of the left upper extremity. The remainder of the postoperative course was unremarkable.

### DISCUSSION

The sitting position helped create a circumstance conducive to the occurrence of a subdural pneumocephalus. The effects of gravity and intracranial dehydration (steroids, forced diuresis) permitted the cerebral hemispheres to settle into the inferior cranial vault. Intraoperative drainage of the right lateral ventricle might have enhanced the collapse of the right hemisphere. As the cerebral cortices receded from the overlying dura mater, a negative subdural pressure was created, drawing room air through the surgical wound into this space in order to attain equilibrium with ambient pressure.

The well-known propensity of inhaled nitrous oxide to enter into an enclosed air

space more rapidly than nitrogen exits accounts for the gradually enlarging pneumocephalus. A similar course of events has previously been described to occur in patients undergoing pneumoencephalography during nitrous oxide anesthesia.<sup>4</sup> Exposure to 100 per cent inspired oxygen transiently produced a moderate decrease in the size of the gas pocket (fig. 3). However, with continued egress of  $N_2O$  from the tissue stores and net transfer of gas into the enclosed space, the subdural air pocket reaccumulated. Because of the excessive collapse of the right hemisphere, a larger collection of gas appeared in the right subdural space (fig. 2). Similarly, with re-expansion of the cerebral hemispheres the right side had more volume to recover with reaccumulation of its ventricular as well as interstitial volume. The simultaneous occurrence of a greater parenchymal volume re-expansion and more subdural gas on the right side produced a situation of subdural hypertension. Because the subdural space does not communicate directly from one hemisphere to the other, the gas, much like subdural blood, might have behaved like a space-occupying mass lesion. The result was a more pronounced elevation in pressure in the right hemisphere. A needle inserted into the right subdural space released the pressurized gas mixture and permitted continued re-expansion of the right cerebral hemisphere.

The initial interpretation of the hemiparesis was that this elderly patient had incurred a cerebrovascular accident during his surgical procedure. The brow-up skull x-ray suggested the correct diagnosis and permitted appropriate treatment. The resolution of the neurologic deficit after the air pocket was released was dramatic.

### REFERENCES

1. Michenfelder JD, Gronert GA, Rehder K: Neuroanesthesia. *ANESTHESIOLOGY* 30:65-100, 1969
2. McAllister RG: Macroglossia—a positional complication. *ANESTHESIOLOGY* 40:199-200, 1974
3. Ellis SC, Bryan-Brown CW, Hyderally H: Massive swelling of the head and neck. *ANESTHESIOLOGY* 42:102-103, 1975
4. Saidman LJ, Eger EI II: Change in cerebrospinal fluid pressure during pneumoencephalography under nitrous oxide anesthesia. *ANESTHESIOLOGY* 26:67-72, 1965